



DOI: 10.19187/abc.20207288-92

Ovarian Cancer Metastatic to Breast and Axilla: A Case Report

Mehdi Ghelichkhani^{*a}, Nahid Nafissi^a, Zahra Rahimi^b, Farshid Ghasemi Meydansar^a,
Masoud Haghighikhan^a, Leila Sadeghi^c

^a Department of Surgery, Iran University of Medical sciences, Tehran, Iran

^b Student Research Committee, School Of Medicine, Iran University of Medical sciences, Tehran, Iran

^c Department of Medical Oncology and Hematology, Shahid Beheshti University of Medical Sciences, Tehran, Iran

ARTICLE INFO

Received:
30 March 2020
Revised:
23 April 2020
Accepted:
28 April 2020

Key words:

Ovarian cancer,
breast metastasis,
axillary metastasis

ABSTRACT

Background: Metastases to breast and axilla from extramammary sites are uncommon and have been reported in only 2% of breast malignancies. Ovarian cancer metastatic to breast and axillary lymph nodes is extremely rare and only accounts for 0.03%-0.6% of all breast neoplasms. The most common histologic feature of ovarian cancer metastatic to breast is papillary serous adenocarcinoma. Differentiating the secondary breast malignancies from primary ones is crucial as the treatment and prognosis are different, which could avoid many unnecessary procedures. Prognosis is generally poor because most patients have simultaneous spread of the disease.

Case presentation: A 67-year-old woman with a history of ovarian cancer, undergoing chemotherapy presented with redness and swelling in her left breast and pathologic axillary lymph nodes. Work ups revealed ovarian cancer metastases to breast and axillary lymph nodes. She underwent chemotherapy with second line chemotherapeutics. The results were satisfying and the patient is well.

Conclusion: The history of cancer in patients with a breast mass, even if clinically benign, may give rise to potential metastases. Screening with physical examination and serial mammography for patients with ovarian cancer could be beneficial. Early and accurate diagnosis of breast metastatic tumors is critical for proper management and preventing unnecessary and possibly harmful procedures.

Introduction

Metastases to breast and axilla from extramammary sites are uncommon and have been reported in only 2% of breast malignancies.¹ They most commonly originate from melanomas, lung cancer, sarcomas and renal carcinomas.² Ovarian cancers metastatic to breast and axillary lymph nodes are extremely rare and only account for 0.03%-0.6% of all breast neoplasms.³

Ovarian cancer has the highest mortality rate among gynecological cancers and happens mostly in postmenopausal women. At the time of diagnosis,

about 60% of women have a dissemination of disease which is usually limited to peritoneal cavity in 85% of patients.³ In advanced stages of the disease, ovarian cancer can be metastatic to liver, lungs and pleura.³

Most breast metastasis cases present as a solitary nodule and share some significant histological features including a metastatic lesion with a fibrous pseudocapsule showing a relatively well circumscribed growth pattern, and the absence of an in situ carcinoma.¹ The most common histologic feature of ovarian cancer metastatic to breast is papillary serous adenocarcinoma.^{4, 5} In mammography, the two main patterns observed in breast metastases are well circumscribed and spheroidal intramammary masses without spiculation or calcification, and architectural distortion and other skin changes.^{2,4,6} Breast metastases on ultrasound are either hypoechoic or isoechoic and

Address for correspondence:

Mehdi Ghelichkhani, MD
Address: Department of Surgery, Rassoul Akram
Hospital, Sattarkhan-Niayesh Avenue, Tehran, Iran
Tel: +98 21 64352390
Fax: +98 21 64352486
E-mail: dr.mehdi.gh@gmail.com



have well circumscribed margins.²

Differentiating the secondary breast malignancies from primary ones is crucial as the treatment and prognosis are different, which could avoid many unnecessary procedures. Prognosis is generally poor because most patients have simultaneous spread of the disease.²

In this study, we are presenting a 67-year-old woman with breast and axillary lymph node metastases from ovarian cancer.

Case presentation

A 67-year-old woman who was previously diagnosed with mullerian serous ovarian carcinoma in 2017, presented to our care unit in July 2019 with swelling and redness in her left breast.

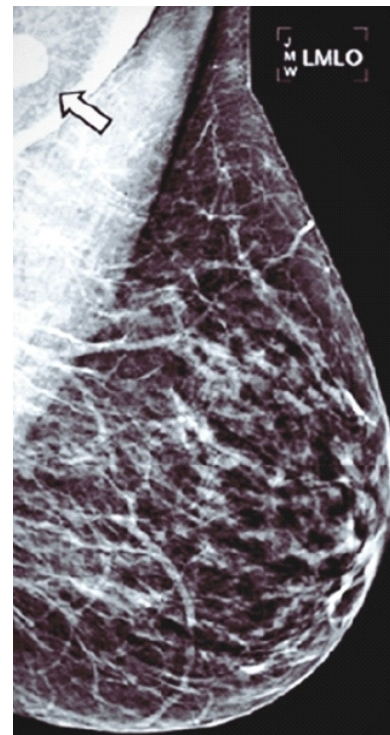
In her previous screening mammography in 2017, scattered areas of fibroglandular density and benign calcifications were found in both breasts. There was no evidence of skin or nipple retraction or pathologic adenopathy.

In 2017, she presented with abdominal pain. Abdominal wall mass guided core needle biopsy found papillary-like fragments composed of atypical cells with mildly pleomorphic hyperchromatic irregular nuclei and eosinophilic cytoplasm with focal calcifications. The tumor cells were immunopositive for CK7, ER, WT-1 and PAX-8, and immunonegative for CK20, TTF-1, CDX2, GATA3, Mammaglobin A and Calretinin markers. Analyses besides histomorphology and immunohistochemistry findings suggested left ovarian serous carcinoma. She received three sessions of Avastin (Bevacizumab) based chemotherapy and then underwent surgery in February, 2018. The patient continued to receive chemotherapy with Avastin for four more sessions after the surgery. Positron emission tomography (PET) scan was done and to complete the therapy, eight more Avastin based chemotherapy sessions were planned; however, after seven sessions, swelling and erythema appeared in the left breast (Figure 1).

In the physical examination, pathologic axillary lymph nodes were present. The primary diagnosis was

breast cancer metastasis to axillary lymph nodes. Left axillary lymph node needle biopsy was done. The results showed nests of large epithelioid cells with subsequent immunohistochemistry (IHC): PAX-8: Positive, WT-1: Negative, TTF-1: Negative, Chromogranin: Positive, synaptophysin: Negative, ER: positive 50%, PR: Negative, HER-2: Equivocal (2+), CK: Positive, GATA-3: Negative and KI67: 80%. The findings suggested that the lesion was a metastatic carcinoma of ovarian origin. Direct digital bilateral mammography (DDR), mediolateral-oblique (MLO) and cranial-caudal (CC) views, bilateral breast sonography and left breast skin lesion biopsy were done to confirm the diagnosis.

The mammogram (Figure 2) revealed mild skin thickening in the left breast, compared to her previous mammography. Pathologic high density enlarged lymph nodes were seen in the left axillary region. No pathology was detected in the breast parenchyma.



breast cancer metastasis to axillary lymph nodes. Left axillary lymph node needle biopsy was done. The results showed nests of large epithelioid cells with subsequent immunohistochemistry (IHC): PAX-8: Positive, WT-1: Negative, TTF-1: Negative, Chromogranin: Positive, synaptophysin: Negative, ER: positive 50%, PR: Negative, HER-2: Equivocal (2+), CK: Positive, GATA-3: Negative and KI67: 80%. The findings suggested that the lesion was a metastatic carcinoma of ovarian origin. Direct digital bilateral mammography (DDR), mediolateral-oblique (MLO) and cranial-caudal (CC) views, bilateral breast sonography and left breast skin lesion biopsy were done to confirm the diagnosis.

The mammogram (Figure 2) revealed mild skin thickening in the left breast, compared to her previous mammography. Pathologic high density enlarged lymph nodes were seen in the left axillary region. No pathology was detected in the breast parenchyma.

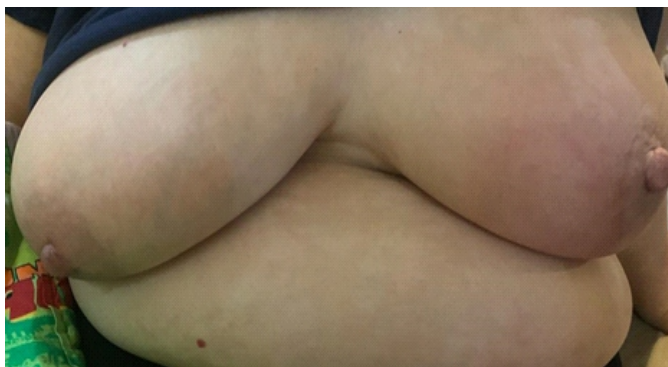


Figure 1. Swelling and erythema on patient's left breast

After biopsies and during preparation for chemotherapy, she developed symptoms (such as coughs and chest pain) similar to a cold. Radiology scan revealed pleural effusion. The fluid was discharged by thoracoscopy, pleurodesis was done and cytology confirmed malignant pleural effusion. Then the patient underwent chemotherapy with keytruda and topotecan. The outcomes were satisfying and there was no pathology in her breasts and axillary region or any side effects except ascites (Figure 3). The follow up continued for 3 months after interventions and the patient showed a very good clinical response.

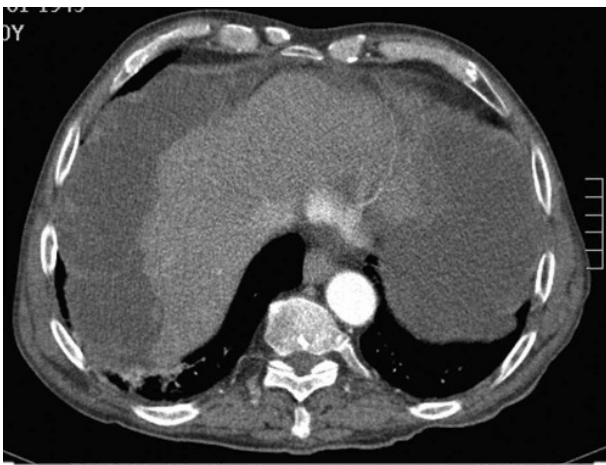

Figure 3 Abdominal CT scan demonstrating ascites

The present report describes a case of ovarian cancer metastasis to the breast and axilla. Metastases to breast from extramammary primary sites are rare. It regularly happens among age groups at risk for primary breast carcinomas. Malignant melanoma, lung cancer, lymphoma, ovarian cancer, soft tissue sarcoma, gastrointestinal and genitourinary tumors, and some sporadic tumors such as thyroid neoplasm, osteosarcoma, and cervical, vaginal and endometrial carcinoma, are the most common tumors to metastasize to the breast from extramammary locations.^{2,7} The most common symptom among patients is a palpable breast mass, although the lesion can also be found in regular mammography incidentally.⁸

Metastatic breast tumors are typically firm, superficial, well-circumscribed by a fibrous pseudocapsule and movable masses with the overlying skin generally of normal consistency.^{1,9} Previous studies indicated that calcifications are extremely rare and can only be seen in metastatic papillary carcinomas.^{3,8}

A solitary tumor is the most common type of clinical presentation of metastatic breast cancer (85% of patients) and only 4% of patients have diffuse involvement.¹⁰ The upper outer quadrant is the most common location for metastatic lesions (62% of patients).¹¹

Previous studies suggested fine needle aspiration (FNA) of the lesion is a proper and cost-effective diagnostic approach.^{7,12} On the contrary, Smyrniotis *et al.* discouraged FNA as it was not helpful in differentiating primary breast carcinoma from metastatic tumors.¹³ When examined microscopically, metastases usually do not have an invasive ductal or in situ component.⁹

The most common type of breast metastases from ovarian tumors is papillary serous adenocarcinoma¹ which is not a common pattern of the majority of invasive breast carcinomas.

Immunohistochemical studies may also be helpful for diagnosis in some cases. Use of tumor markers such as expression of C7 and CK20 for adenocarcinoma, TTF-1 for lung cancer, aFP for hepatocellular carcinoma (HCC), Ki-67 cell proliferation marker, ER/PR, BRST-2 and HER-2/neuoncoprotein for primary breast cancer, can be beneficial for locating the origins of metastatic breast tumors without specific morphological feature.^{8,14}

For differential diagnosis of ovarian cancer metastasis to breast, a considerable number of immunohistochemical markers have been reported to be useful including ER, PAX8, CK7, CK20, GATA3, CA125, WT-1, GCDFP-15, and mesothelin. WT-1 exists in 70% of ovarian carcinomas and 95% of serous papillary carcinomas; however, it is found in less than 10% of breast cancers.¹⁵ In addition, Mesothelin is found in more than 90% of serous papillary ovarian carcinomas, but it is poorly expressed in 3–14% of breast cancer cases.¹⁶

While no marker should be considered to be 100% precise, these markers, alongside a comparison of the pathology of the primary tumor and the suspicious breast tumor, can help to distinguish breast metastases from primary cancer. Routine pathologic examination and considering clinical history may also be helpful to differentiate primary breast cancer from metastatic cancer.

It is critical to differentiate breast metastases precisely from primary breast cancer because the prognosis and treatment are significantly different. Breast surgeries and radiation therapy can be unnecessary for metastases. In addition, chemotherapeutic treatments used in secondary tumors are different from primary breast lesions. Some studies suggest that ovarian metastasis to the breast should be treated as a systemic disease with proper chemotherapeutics.¹⁷ Conservative breast surgery is generally best reserved for patients who do not respond to systemic therapy and need palliation. In addition, a study of 169 patients with extramammary metastases to the breast found a considerably higher survival rate in patients undergoing breast metastasis surgical resection.⁸

The result of the previous reviews are not sufficient to provide a meaningful survival rate in this patient



group, due to the rarity of these metastases and the small number of patients. However, studies suggest that breast metastases and specifically from ovarian origins have an exceedingly worse prognosis.¹⁸ Patients have a median survival time of 10 months from the time their breast metastasis is diagnosed.⁸

Further clinical studies on ovarian cancer metastasis to the breast should be conducted to establish new specific markers for a more precise histopathological diagnosis based on biopsy specimens and to assess the real need for surgical intervention in terms of short and long-term prognosis compared to a palliative chemotherapy.

Metastases to breast can mimic primary breast cancer. While breast metastases of ovarian cancer are uncommon, screening with physical examination and serial mammography for patients with ovarian cancer could be beneficial. The history of cancer in patients with a breast mass, even if clinically benign, may give rise to the possibility of potential metastases and may need further evaluation. A combination of patient's clinical history, and radiologic, microscopic, pathologic and immunohistochemical features, could distinguish a primary breast mass from metastases. Early and accurate diagnosis of breast metastatic tumors is critical for proper management and preventing unnecessary and possibly harmful procedures in patients. Considering the poor prognosis of metastatic lesions, treatments should be individualized. Further work is necessary to confirm whether surgical resection of metastasis to the breast will bring a survival benefit in selected patients.

Ethical Consideration

The patient gave a written consent to the authors to publish this case report about her condition and treatment.

Conflict of Interest

None.

References

1. Delair D, Corben A, Catalano J, Vallejo C, Brogi E, et al. Non-mammary metastases to the breast and axilla: A study of 85 cases. *Modern pathology : an official journal of the United States and Canadian Academy of Pathology, Inc.* 2012;26.
2. Antuono L, Angela F, Luca N, Giovanni M, Enrico C. Breast metastasis from ovarian cancer: A case report. *Radiol Case Rep.* 2018; 13(6):1166-9.
3. Della Corte L, Giampaolino P, Fabozzi A, Cieri M, Zizolfi B, et al. Breast metastasis two years after pelvic surgery and adjuvant chemotherapy for serous ovarian cancer. *Gynecological Endocrinology.* 2019;35(3):211-3.
4. Klein R, Brown A, Gomez-Castro C, Chambers S, Cragun J, et al. Ovarian Cancer Metastatic to the Breast Presenting as Inflammatory Breast Cancer: A Case Report and Literature Review. *Journal of Cancer.* 2010;1:27-31.
5. Tempfer C, Fizazi N, Ergonenc H, Solass W. Metastasis of ovarian cancer to the breast: A report of two cases and a review of the literature. *Oncology Letters.* 2016;11.
6. Balaji R, Ramachandran K, Anila KR. Ovarian Carcinoma Metastasis to the Breast and Imaging Features With Histopathologic Correlation: A Case Report and Review of the Literature. *Clinical Breast Cancer.* 2009;9(3):196-8.
7. Akçay MN. Metastatic disease in the breast. *Breast (Edinburgh, Scotland).* 2003;11:526-8.
8. Williams S, Ehlers R, Hunt K, Yi M, Kuerer H, et al. Metastases to the breast from nonbreast solid neoplasms: Presentation and determinants of survival. *Cancer.* 2007;110:731-7.
9. Vergier B, Trojani M, De Mascarel I, Coindre J-M, Le Treut A. Metastases to the breast: Differential diagnosis from primary breast carcinoma. *Journal of Surgical Oncology.* 1991;48(2):112-6.
10. Kayikçioğlu F, Boran N, Ayhan A, Güler N. Inflammatory Breast Metastases of Ovarian Cancer: A Case Report. *Gynecologic Oncology.* 2001;83(3):613-6.
11. Moore DH, Wilson DK, Hurteau JA, Look KY, Stehman FB, et al. Gynecologic cancers metastatic to the breast. *Journal of the American College of Surgeons.* 1998;187(2):178-81.
12. Gupta D, Merino M, Farhood A, Middleton L. Metastases to breast simulating ductal carcinoma in situ: Report of two cases and review of the literature. *Annals of diagnostic pathology.* 2001;5:15-20.
13. Smyiotis V, Theodosopoulos T, Marinis A, Goula K, Psychogios J, et al. Metastatic disease in the breast from nonmammary neoplasms. *European journal of gynaecological oncology.* 2005;26:547-50.
14. Lee SK, Kim W, Kim SH, Hur S, Kim S, et al. Characteristics of Metastasis in the Breast From Extramammary Malignancies. *Journal of surgical oncology.* 2010;101:137-40.
15. Lee B, Hecht J, Pinkus J, Pinkus G. WT1, Estrogen Receptor, and Progesterone Receptor as Markers for Breast or Ovarian Primary Sites in Metastatic Adenocarcinoma to Body Fluids. *American journal of clinical pathology.* 2002;117:745-50.
16. Lee A. The histological diagnosis of metastases to the breast from extramammary malignancies. *Journal of clinical pathology.* 2008;60:1333-41.
17. Özsaran AA, Dikmen Y, Terek MC, Ulukus M, Özdemir N, et al. Bilateral metastatic carcinoma of the breast from primary ovarian cancer. *Archives of Gynecology and Obstetrics.* 2000;264(3):166-7.

18. Micha JP, Goldstein BH, Epstein HD, Rettenmaier MA, Brown JV, III. Ovarian cancer metastatic to the breast. *Gynecologic Oncology*. 2006;102(2):386-90.