



DOI: 10.32768/abc.202073132-135

A Case Report of Spontaneous Thrombosis of an Iatrogenic Breast Pseudoaneurysm

 Masoumeh Gity^a, Batoul Seifi Nadergoli^b, Behnaz Moradi^a, Mohammadreza Chavoshi^{*a}
^a Department of Radiology, Tehran University of Medical Sciences, Tehran, Iran^b Department of Radiology, Tabriz University of Medical Sciences, Tabriz, Iran

ARTICLE INFO

Received:
17 May 2020
Revised:
01 July 2020
Accepted:
06 July 2020

Key words:

Pseudoaneurysm,
iatrogenic,
breast,
thrombosis

ABSTRACT

Background: Pseudoaneurysm of the breast is a very uncommon disease mostly occurring following traumatic injuries including biopsy. Increasing the use of core needle biopsy in breast pathologies could lead to more cases of the iatrogenic pseudoaneurysm.

Case presentation: Here we described a breast pseudoaneurysm case that occurred after core needle biopsy. The diagnosis was made by color doppler ultrasonography and MRI with contrast. Ultrasound-guided compression was used to treat the lesion. The lesion was followed up with ultrasonography and finally it was resolved.

Conclusion: Although hematoma is a more common complication of breast biopsy, other complications including pseudoaneurysm should be kept in mind. Ultrasound is a useful technique for both the diagnosis and non-surgical treatment of the disease. Ultrasound-guided compression and follow up exams could be helpful to prevent invasive procedures.

Introduction

Core needle biopsy (CNB) is increasingly used as a diagnostic method for histologic examination of breast pathologies before the main surgery. Cost-effectiveness, accessibility, minimal rate of complications and short Procedure duration are major factors to make CNB a popular method. Although hematoma is the most common complication in CNB, limited cases of pseudoaneurysm have been published.¹ A pseudoaneurysm is a blood-containing false lumen that is connected to the main arterial lumen with a narrow neck. They could rarely happen spontaneously in patients with severe atherosclerotic changes, although most cases are posttraumatic.

Here we discussed an iatrogenic pseudoaneurysm following breast mass CNB which was treated conservatively.

Case presentation

A 29-year-old woman with chief complaint of nontender palpable breast mass was referred for further evaluations. Sonography showed a vascular, hypoechoic, well-circumscribed mass measuring 9×5 mm in the right breast upper outer quadrant. The lesion had a low suspicious feature (BIRADS 4a) and was candidate for tissue sampling.

Due to a suspicious history of bleeding disorders, platelets level and coagulation tests were checked and the result was normal. No drug history was recorded. Local anesthesia of skin and parenchyma around the lesion was done by 1% lidocaine without epinephrine. The surrounding tissue was checked to evaluate any probable vessel in the biopsy route. A biopsy was performed with a 14-gauge cutting needle and a throw of 22 millimeters under the guide of sonography.

Profuse bleeding occurred while doing the biopsy

www.SID.ir
Address for correspondence:

Mohammadreza Chavoshi, MD
 Shariati Hospital, Ale Ahmad Highway, Tehran, Iran
 Tel: +98-9143133658
 Fax: +98-2166581577
 E-mail: chavoshi.smr@gmail.com

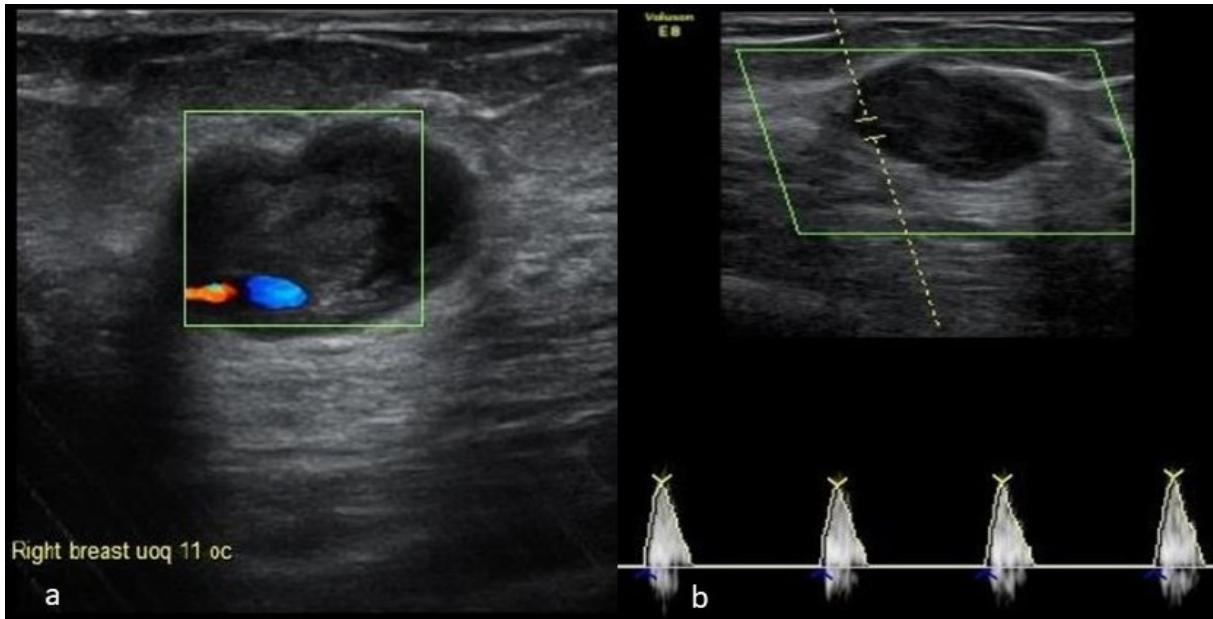


Figure 1. a) A heterogeneous hypoechoic mass with a turbulent flow. b) Spectral color Doppler revealed a to-and-fro waveform in the neck

and after the first sampling. Sonography showed a hematoma evident as a 20×15 mm hypoechoic lesion at the biopsy site. Immediate compression was done using the ultrasound transducer followed by manual compression for 30 minutes. No more bleeding was observed.

The next day control sonography showed a 21×16 mm echo-free to hypoechoic mass with a 2 mm narrow neck at 11 o'clock of the right breast adjacent to previous mass.

Color Doppler investigations showed that the blood flow was turbulent inside the mass and there was to-and-fro spectral waveform in the neck of the lesion. (Figure 1)

Due to the formation of hematoma and inflammatory changes in the surrounding tissue, evaluation of the initial mass was not possible with ultrasound. On the other hand, definite pathology of the tumor was unknown since the biopsy failed. Therefore, MRI was done to further evaluate the mass. The MRI was performed after 20 days and revealed an oval-shaped mass in the upper outer quadrant of the right breast with intermediate T1 and heterogeneous high and low signal intensity on T2 images measuring 21×16×15 mm (Figure 2a). The mass shows intense rapid enhancement on dynamic series and is related to early drainage (Figure 2b). The diagnosis was an iatrogenic pseudoaneurysm so

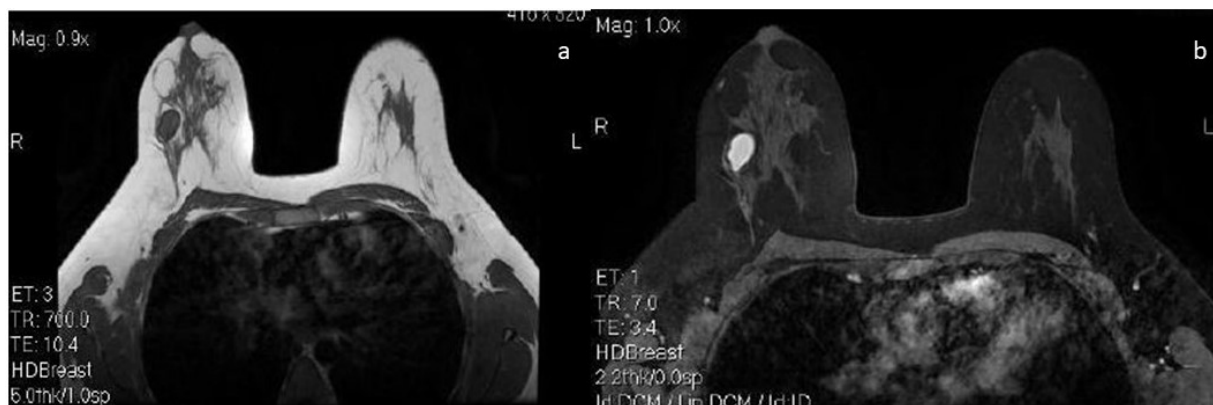


Figure 2. a) T1W MRI without contrast shows an intermediate intensity mass in the upper outer quadrant of the right breast. b) T1W MRI with contrast shows intense rapid enhancement after contrast injection. Since the pseudoaneurysm happened in about 2 cm of the mass, the mass is not obvious in this cut.

monitoring and conservative proceedings were advised.

Control Doppler ultrasonography 30 days after the biopsy showed a 12×7 mm heterogeneous mass with an anechoic center (Figure 3a). The color

Doppler image showed a whirling flow but power Doppler images showed vascularity which connected the mass to an adjacent vessel (Figure 3b).

Control MRI was done after 6 months. The results showed that the PA size had decreased (Figure 4) and

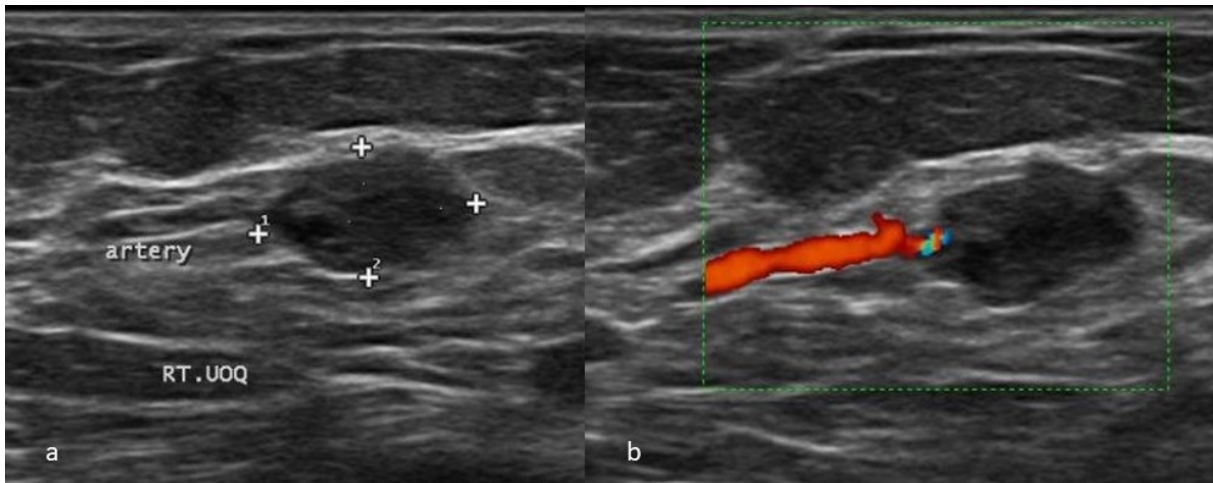


Figure 3. a) A hypoechoic heterogeneous mass in control US. b) Feeding artery of the mass.

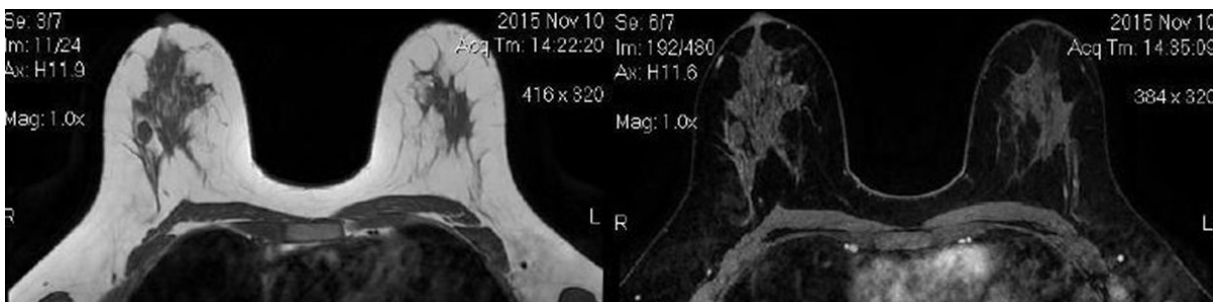


Figure 4. T1W MRI with and without contrast after 6 months shows a decrease in the size of the mass

its dimensions were 12×6 mm. The surgeon suggested the conservative Management. The lesion was completely resolved in the next ultrasound follow-up after 2 months.

Discussion

A pseudoaneurysm or false aneurysm most frequently occurs following a traumatic injury due to a puncture or tear in the arterial wall, after which blood is collected in adjacent tissue connected to the vessel.^{1,2} Pseudoaneurysms do not have an arterial wall and are contained by perivascular tissue.¹ Pseudoaneurysm occurs mostly in females, old people, those suffering from atherosclerosis, and those treated by anticoagulation therapy such as warfarin, heparin, or aspirin.¹⁻⁵ Pseudoaneurysm is uncommon but could be non-traumatic and spontaneous primarily among those with atherosclerotic disease or receiving anticoagulation therapy or both.^{3,6}

Pseudoaneurysm in radiology is an obvious complication of vascular catheterization and percutaneous core needle biopsy of a solid organ.¹⁻⁵

Breast pseudoaneurysm is diagnosed by mammography as a circumscribed mass which is adjacent to a blood vessel or extending from it,⁷ but an ultrasound can confirm the mass to be a pseudoaneurysm. An anechoic mass with echogenic rim, adjacent to an artery requires ultrasound examination.^{6,7} Color and

power Doppler imaging shows the adjacent artery, connecting neck, and communicating blood flow within the pseudoaneurysm with a turbulent flow and classic “ying-yang” sign on color Doppler imaging. The spectral Doppler imaging will show the “to-and-fro” waveform.^{3,6,8,9} In follow-up sonography as a result of clot formation there will be a hypoechoic lesion without any blood flow. Since some cases are secondary to traumatic injury the CT with contrast can be the first modality that shows pseudoaneurysm.

Since sonography displays real-time images, immediately focused compression of a hematoma can be observed. Iatrogenic pseudoaneurysms caused by large-diameter sheaths and needles could not be thrombosed by compression possibly due to a wide neck. Although compression has been applied as a first-line treatment, it may often bring about no desirable outcome.

Other treatments observed in the literature include percutaneous alcohol injection,² thrombin injection,^{8,10,11} micro coil embolization¹² and surgical correction.^{1,4,5} However, surgical treatment is mostly recommended in cases of underlying breast malignancy. Since pseudoaneurysms in the breast are uncommon, they are in general treated in the same way as are pseudoaneurysms in other organs.

Spontaneous resolution of breast pseudoaneurysms has also been reported.^{3,6,13} It is theorized that small pseudoaneurysms may be more common than initially



thought, but the small size, small neck, and absence of underlying anticoagulation lead to a spontaneous resolution before clinical identification.

Pseudoaneurysm, as a potential complication of the breast biopsy, needs to be considered. Mapping the vessels near the lesion by color flow evaluation before the biopsy can help prevent complications like pseudoaneurysm or hematoma in interventions. If pseudoaneurysm occurs, ultrasound-guided compression and follow up exams could be helpful to prevent invasive procedures. However, if the lesion is still present, performing an additional procedure such as embolization or surgery should be considered.

Conflict of Interest

None

Ethical Consideration

The written consent was signed by the patient.

References

1. Azorín Samper MdC, Hernandorena González M, Ibáñez Arias A, Díaz Sierra S, Bertolo Domínguez M, et al. A case report of pseudoaneurysm after a core needle biopsy of breast cancer. *The Breast Journal*. 2020;26(2):252-4.
2. Bazzocchi M, Francescutti GE, Zuiani C, Del Frate C, Londero V. Breast pseudoaneurysm in a woman after core biopsy: percutaneous treatment with alcohol. *American Journal of Roentgenology*. 2002;179(3):696-8.
3. Bitencourt A, Cohen MP, Graziano L, Souza JA, Marques EF, et al. Pseudoaneurysm after ultrasound-guided vacuum-assisted core breast biopsy. *The breast journal*. 2012;18(2):177.
4. Dixon A, Enion D. Pseudoaneurysm of the breast: case study and review of literature. *The British journal of radiology*. 2004;77(920):694-7.
5. Wilkes AN, Needleman L, Rosenberg AL. Pseudoaneurysm of the breast. *AJR American journal of roentgenology*. 1996;167(3):625-6.
6. El Khoury M, Mesurolle B, Kao E, Mujoomdar A, Tremblay F. Spontaneous thrombosis of pseudoaneurysm of the breast related to core biopsy. *American Journal of Roentgenology*. 2007;189(6):W309-W11.
7. Beres R, Harrington D, Wenzel M. Percutaneous repair of breast pseudoaneurysm: sonographically guided embolization. *AJR American journal of roentgenology*. 1997;169(2):425-7.
8. Eli E, Ansari H, Williams J, Carter M, Friedman P. Successful treatment of a two centimeter breast pseudoaneurysm with thrombin injection. *The breast journal*. 2012;3(18):292-3.
9. Sohn Y-M, Kim MJ, Kim E-K, Chung SH, Kwak JY, et al. Pseudoaneurysm of the breast during vacuum-assisted removal. 2009.
10. Buck RM, Ladner JR, Wuerdeman MF, Kitley CA. A novel treatment for breast pseudoaneurysm in the anticoagulated patient. *The Breast Journal*. 2020.
11. McNamara Jr M, Boden T. Pseudoaneurysm of the breast related to 18-gauge core biopsy: successful repair using sonographically guided thrombin injection. *American Journal of Roentgenology*. 2002;179(4):924-6.
12. Sasada S, Namoto-Matsubayashi R, Yokoyama G, Takahashi H, Sakai M, et al. Case report of pseudoaneurysm caused by core needle biopsy of the breast. *Breast Cancer*. 2010;17(1):75.
13. Al Hadidy AM, Al Najjar MS, Farah GR, Tarawneh ES. Pseudoaneurysm of the breast after blunt trauma: Successful treatment with ultrasound-guided compression. *Journal of Clinical Ultrasound*. 2008;36(7):440-2.