



# Polypectomy as a Complete Therapy for Leiomyosarcoma of the Cervix Uteri: An Unusual Treatment

Baffah Muhammad Aminu<sup>1</sup>, Lamaran Makama Dattijo<sup>1\*</sup>, Kabir Abdullahi<sup>2</sup>, Calvin Chama<sup>1</sup>

## Abstract

**Objectives:** Leiomyosarcoma (LMS), which arises from the uterine cervix, is an extremely rare neoplasm and is presented with vaginal bleeding and discharge. In our case report, we intended to highlight the role of polypectomy as a practical option for routine hysterectomy and the surgical cure of cervical LMS.

**Case Report:** A 50-year-old woman (Para 8+0, 6A) presented to the Gynecological Clinic of ATB University Teaching Hospital with vaginal discharge and fleshy mass protruding from the vulva. Examination revealed a cervical polyp on the anterior lip of the cervix. Polypectomy was performed subsequently, and histologic examination including immunohistochemical staining confirmed LMS of the uterine cervix. The patient underwent hysterectomy with bilateral salpingo-oophorectomy with the histological confirmation of a complete excision.

**Conclusions:** Generally, no specific management option is taken for this tumor due to its rare occurrence. However, polypectomy with a wide excision of tumor margin could result in a complete cure, and prolonged survival as in the case presented. Accordingly, histological studies including special stainings may play a vital role in cancer diagnosis.

**Keywords:** Cervix, Leiomyosarcoma, Polypectomy, Special stain

## Introduction

Leiomyosarcoma (LMS) is an aggressive soft tissue tumor, accounting for 2%-5% of tumors in the uterus (1). It presents the features of smooth muscle differentiation and can arise from viscera like uterus, soft tissue, or the gastrointestinal tract. It can also arise in the bone, dermis, and vessels. LMS is regarded as one kind of more than 50 kinds of sarcomas.

Frequency of cervical malignancies occurring due to sarcomas are fewer than 1% (1-4), which commonly occur in the perimenopausal (5) and postmenopausal women with quite a small number of reported cases of LMS amongst young women (3,4). LMS usually affects the uterine corpus, metastasizing to other peritoneal organs and even beyond. Interestingly, less than 25 cases of cervical LMS have been reported (5). Hence, it is a proliferating sarcoma with no encouraging outcome. Considering the abovementioned, this study aimed to seek the occurrence of this tumor, and the application of polypectomy as an alternative surgical cure for the cervical LMS.

## Case Presentation

A 50-year-old woman (P8+0, 6A) was referred to the Gynecological Clinic of ATB University Teaching Hospital with vaginal discharge and complaints of a mass protruding from her vagina for seven months. The patient was apparently asymptomatic previously, and then she

had noticed a mass in the vagina which had gradually increased in size. She had no associated lower abdominal pain and genital bleeding. Her menstrual cycles were regular and normal. Moreover, she was treated for leprosy 25 years prior to the presentation and was said to have been cured.

On the examination, she was not pale and her vital signs were normal. She had the stigmata of healed leprosy. Furthermore, no abnormality was detected on the abdominal examination. But, pelvic examination showed a mass protruding from the vagina. The upper, lower, and lateral borders of the mass could be ascertained. The mass was about 6 × 5 cm, firm to hard in consistency, freely mobile and non-tender, with its pedicle attached to the outer lip of the cervix anteriorly.

The uterus size was normal and no mass could be appreciated separate from the uterus. Furthermore, a pelvic ultrasound showed a growth occupying the vagina close to the cervix, adnexa, and pelvis, while other abdominal organs were all normal. Other hematologic results were also normal. The patient was counseled and finally polypectomy was offered.

A mass of 6 × 5.5 × 2 cm in size was seen intraoperatively, arising from the anterior lip of the cervix. The mass was excised, placed in 10% buffered saline formalin, and sent to the Histopathology Department of the Gynecological Clinic, where it was evaluated, representative sections

Received 2 June 2017, Accepted 28 September 2017, Available online 10 November 2017

<sup>1</sup>Department of Obstetrics and Gynaecology, Abubakar Tafawa Balewa University Teaching Hospital, Bauchi, Nigeria. <sup>2</sup>Department of Pathology, Usman Danfodiyo University Teaching Hospital, Sokoto, Nigeria.

\*Corresponding Author: Lamaran Makama Dattijo, Tel +234 8036301549, Email: Lamaran2@yahoo.com



made, embedded in paraffin, sectioned with a microtome, and stained with Hematoxylin and eosin for light microscopy (Figure 1A). Sectioning showed an ulcerated sessile polypoid tumor composed of sheets, small nests, and loose fascicles of moderately to markedly pleomorphic large spindle and round cells with hyperchromatic to vesicular nuclei, and coarse chromatin, and variable amounts of eosinophilic fibrillary cytoplasm. Special stains (Masson's Trichrome) (Figure 2C & 2D) showed a poor collagen lesion. Moreover, the tumor was negative for cytokeratin and chromogranin (Figure 2A & 2B).

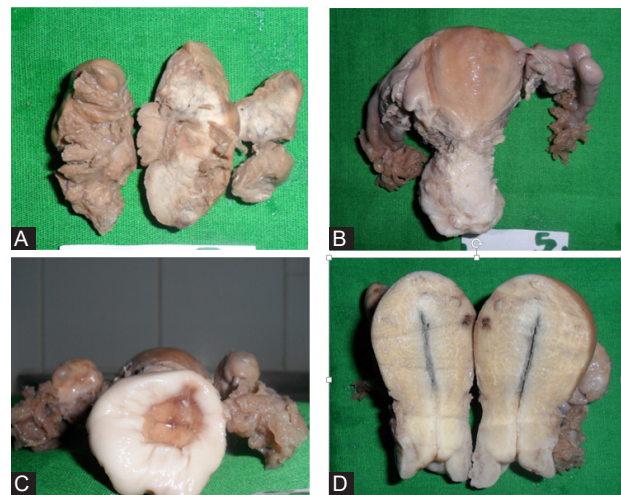
#### Diagnosis of Leiomyosarcoma

The patient was counseled and total abdominal hysterectomy with subsequent bilateral salpingo-oophorectomy was offered. In this regard, intra-operative findings depicted a normal uterus with normal ovaries and normal bilateral tubes. Sections of the cervix also showed ulceration and marked immature squamous metaplasia of the epithelium. In addition, the sub-epithelial stroma was myofibrous and free of tumor. Sections of the fallopian tubes showed fairly preserved transmural structures and the ovaries showed cystic follicles in an ovarian stroma. No evidence of tumor was observed in the TAH/BSO sample (Figure 1B-D). The postoperative management of the patient was uneventful. She did well subsequently and was discharged post operatively. She was then followed up for 3 years and the follow-up visits were uneventful.

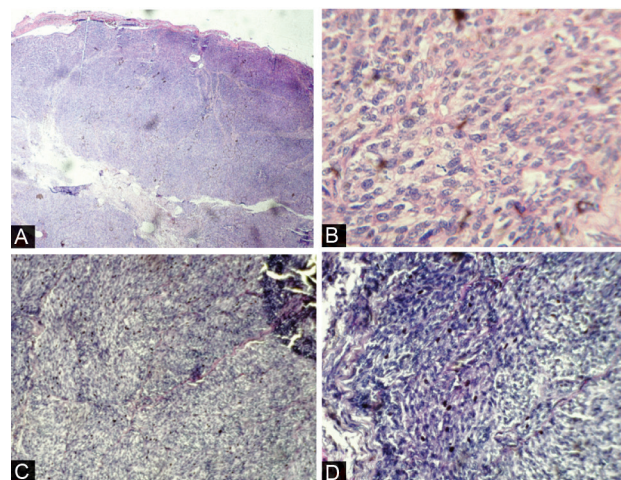
#### Discussion

Cervical LMS is an exceedingly rare neoplasm (3,5,7), the incidence of which is 1%-2% in postmenopausal women (8). Studies in Nigeria quoted an incidence of 0.5% (2). This tumor can arise primarily from the cervix given its extreme rarity (3,7). Patients with LMS are usually postmenopausal, at an average age of 60 years (7), and tend to present with non-specific symptoms which may include abnormal vaginal bleeding and discharge. Abdominal swelling, along with other urinary and gastrointestinal symptoms like constipation may sometimes be the other unusual complaints. There have been reports on LMS located in the uterus, ovaries, bone, liver, and the lungs, but the occurrence of this condition in the cervix has not been widely reported (7). When present in the cervix, the women may have vaginal bleeding and mass (5,7). The patient under our study did present with the classic symptoms because of the location of the tumor.

Diagnosis of LMS is largely histopathological (3), which relies mainly on the morphologic examination (i.e., light microscopic examination) of hematoxylin- and eosin-stained sections of formalin-fixed and paraffin-embedded tissues. In addition, immunohistochemical staining may be done for cases which are not very clear even after morphologic evaluation. Immunohistochemical studies are required to differentiate sarcoma from other alternative diagnoses like malignant melanoma, metastatic



**Figure 1.** (A) Cut Surface of the Polypectomy Showing Solid Areas. (B) External Surface of the Hysterectomy Showing Fairly Normal Sized Uterus and Adnexae. (C) Ectocervix Showing the Site of Polypectomy on the Anterior Lip of the Cervix Uteri. (D) Cut Surface of the Hysterectomy Specimen Showing Grossly Normal Appearance.



**Figure 2.** Sectioning of the Uterus. (A) Nodular lesion in sheets (H & E x40). (B) A moderately pleomorphic mesenchymal neoplasm with mitosis (H & E x 400). (C) Collagen-poor mesenchymal neoplasm (Masson's trichrome x40). (D) Collagen-poor mesenchymal neoplasm (Masson's trichrome x200).

carcinoma, and epithelioid and endometrial stromal sarcoma (6,7). Other adjuncts like magnetic resonance imaging, along with tumor markers such as CA 125 can be used to buttress the suspicion for LMS and other tumors such as sarcomas; CA 125 levels are abnormally higher in the former. Similarly, the presence of clinical symptoms suggestive of metastasis or lymphadenopathy can aid the diagnosis, as early metastasis via haematogenous spread is its hallmark. These were not present in our patient.

LMS is one of the difficult soft-tissue sarcomas to be treated owing to the uncertainty of its optimal management (7). Surgery is the main treatment option. Total abdominal hysterectomy, bilateral salpingo-oophorectomy with or

without omentectomy and lymph node dissection are the preferred options for women with LMS of the uterus (3,7,8). Our patient had polypectomy of the cervical LMS which is an unusual treatment option with a complete excision. Adjuvant chemotherapy using gemcitabine and docetaxel have also been reported (3, 7). This therapy with or without radiation therapy can result in the prolonged survival and cure.

Chemotherapy is used for metastatic diseases. Though not curative, it tends to slow down the progression of systemic diseases. Radiation therapy, on the other hand, improves the rates of local control when surgical margins are close, especially in high-grade sarcomas. LMS can be very aggressive (8), metastasizing to organs like the lungs, brain, bone, and the breast. The rate of recurrence and metastasis with LMS is high, and these may be attributed to its aggressive nature (8). It is therefore important to check for possible recurrence of the tumor after 17 months of chemotherapy. Sometimes a combination of all the therapeutic modalities may be instituted for a better and effective outcome (9). No other supportive therapy was applied for our patient since the initial surgical intervention was curative and the 3-year follow-up was uneventful.

### Conclusions

To conclude, there is no specific management option for LMS due to its rare nature (9), however polypectomy with a wide excision of tumor margin could result in a complete cure and prolonged survival as was seen in the case presented.

### Ethical Issues

An informed consent was obtained from the patient before using the data and images.

### Conflict of interests

The authors declare no conflict of interests regarding the

publication of this article.

### Financial Support

No financial support was received for this case report.

### References

1. Vellanki VS, Rao M, Sunkavalli CB, Chinamotu RN, Kaja S. A rare case of uterine leiomyosarcoma: a case report. *J Med Case Rep.* 2010;4:222. doi:10.1186/1752-1947-4-222
2. Ugwu EO, Iferikigwe ES, Okeke TC, Ugwu AO, Okezie OA, Agu PU. Pattern of gynaecological cancers in University of Nigeria Teaching Hospital, Enugu, south eastern Nigeria. *Niger J Med.* 2011;20(2):266-269.
3. Mehra R, Sidhu SPK, Pandey AK, Garg S. A rare case of leiomyosarcoma of cervix and challenges in its management: a case report and brief review of literature. *Int J Res Med Sci.* 2015;3(1):320-324. doi:10.5455/2320-6012.ijrms20150161
4. Bhatia V, Taksande R, Natekar A, Ali Z. Cervical leiomyosarcoma: a rare entity. *South Afr J Gynaecol Oncol.* 2015;7(2):64-66. doi:10.1080/20742835.2015.1030887
5. Aminimoghaddam S, Arabian S, Haghighi S, Haghighi L. Cervical leiomyosarcoma: a case report. *J Ob-stet Gynecol Cancer Res.* 2016;1(1):e7523. doi:10.17795/jogcr-7523
6. Hwang H, Matsuo K, Duncan K, et al. Immunohistochemical panel to differentiate endometrial stromal sarcoma, uterine leiomyosarcoma and leiomyoma: something old and something new. *J Clin Pathol.* 2015;68(9):710-717. doi:10.1136/jclinpath-2015-202915
7. Dhull AK, C A, Kaushal V, Marwah N. The uncovered story of leiomyosarcoma of the cervix: a rare case report and review of literature. *BMJ Case Rep.* 2013;2013. doi:10.1136/bcr-2013-008616
8. Gockley AA, Rauh-Hain JA, del Carmen MG. Uterine leiomyosarcoma: a review article. *Int J Gynecol Cancer.* 2014;24(9):1538-1542. doi:10.1097/igc.0000000000000290
9. Khosla D, Gupta R, Srinivasan R, Patel FD, Rajwanshi A. Sarcomas of uterine cervix: clinicopathological features, treatment, and outcome. *Int J Gynecol Cancer.* 2012;22(6):1026-1030. doi:10.1097/IGC.0b013e31825a97f6

© 2019 The Author (s); This is an open-access article distributed under the terms of the Creative Commons Attribution License (<http://creativecommons.org/licenses/by/4.0>), which permits unrestricted use, distribution, and reproduction in any medium, provided the original work is properly cited.