

CASE REPORT

Severe Calcium Channel Blocker Overdose and Successful Management: a Case Report and Literature Review

HONG KHAI LAU^{1,*}, KENNETH BOON KIAT TAN¹, PONAMPALAM R¹¹Department of Emergency Medicine, Sengkang General Hospital, Singapore

Abstract

Background: Calcium channel blocker (CCB) toxicity is one of the most lethal and common drug overdoses encountered in the emergency department (ED). The toxicity of these drugs results from blockade of L-type calcium channels in smooth cells, myocardial cells, and beta cells of the pancreas. Severe toxicity can result in bradycardia, hypotension, hyperglycemia, metabolic acidosis, shock, cardiac arrest and death. According to the American Association of Poison Control Centers' National Poison Data System's annual report in 2015, cardiovascular medications were the fourth most common adult poisoning exposure and second most common cause of adult poisoning fatality in the USA. CCBs are responsible for a substantial portion of the mortality associated with cardiovascular medication overdose cases. Understanding the emergent management of CCB toxicity is essential. Treatment of patients with CCB overdose remains challenging especially in those with refractory hypotension and end organ dysfunction.

Case Presentation: A 45-year-old male with massive amlodipine overdose presented to ED with syncope and severe hypotension. Intensive medical therapy (fluid resuscitation, inotropes, calcium gluconate, and hyperinsulinemia euglycemia therapy [HIET]) was initiated in the ED and continued in the Intensive Care Unit (ICU), and resulted in the patient's total recovery, without any major complications. Fortunately, ECMO implantation (extracorporeal membrane oxygenation) was not required in this patient.

Conclusion: Urgent administration of fluids, calcium, vasopressors, and HIET therapy seem to be the most well validated initial approaches to CCBs overdose treatment. Our successful management strategy should serve as a good learning experience as well as a recommendation for managing such patients.

Keywords: Amlodipine; Calcium Channel Blockers Overdose; Emergency Department

How to cite this article: Lau H.Kh, Boon Kiat Tan K, R P. Severe Calcium Channel Blocker Overdose and Successful Management: a Case Report and Literature Review. *Asia Pac J Med Toxicol* 2020;9(1):25-8.

INTRODUCTION

CCBs are widely prescribed for the management of hypertension, arrhythmias and angina pectoris. They can be divided into dihydropyridines and non-dihydropyridines, based on expected physiologic effects. The dihydropyridines are potent vasodilators but have minimal effect on myocardium contractility and conduction pathways, whereas nondihydropyridines have a greater effect on myocardium contractility and conduction pathways but a minimal effect on vasodilatation. However, at the higher doses seen especially in massive overdose cases, such selectivity is usually lost.

Amlodipine, a dihydropyridine CCB, is commonly used in clinical practice due to its desirable properties, such as once daily dosing and minimal effects on heart rate. The main problem with amlodipine overdose is prolonged hypotension due to the sustained-release formulation and the low metabolic clearance of amlodipine with a long plasma half-life (1). In the case of severe toxicity, good outcomes can be achieved through aggressive treatment and provision of circulatory support.

CASE PRESENTATION

A 45-year-old male with medical history of substance abuse and bipolar disorder presented to the emergency department (ED) after being found unconscious at home. He was brought to the ED by emergency ambulance services. On arrival, he was uncooperative during history taking. According to his father, he was found to be unresponsive in his room for a few minutes before regaining consciousness. In the ED, he had no apparent signs or symptoms of drug toxicity apart from hypotension. He denied any cardiac, respiratory, gastrointestinal, or neurological symptoms. Initial vital signs were blood pressure (BP) of 64/47 mmHg, heart rate of 56 beats per minute, respiratory rate of 18 breaths per minute, temperature of 36° Celsius and peripheral oxygen saturation of 98% on room air. After some time, the patient relented and admitted that he had ingested 30 tablets of amlodipine 5 mg 4 hours prior to ED presentation. He denied suicidal ideation and said he mistook it as a mood stabilizer as he was feeling mentally stressed. Although he appeared to be drowsy (Glasgow Coma Score of E3V5M6), he was

*Correspondence to: Hong Khai Lau, MBBS. Department of Emergency Medicine, Sengkang General Hospital, 110 Sengkang E Way, Singapore 544886
Tel: 65-9108 4488, Email: lau.hongkhai@singhealth.com.sg
Received 10 January 2020; Accepted 3 March 2020

rousable and oriented, and the rest of his physical examination was unremarkable. Several diagnostic tests including acetaminophen level, full blood count, and liver function tests were performed and were found to be within normal range. His initial serum electrolytes panel showed a potassium of 5.1 mmol/L, bicarbonate of 22.2 mmol/L, creatinine of 161 umol/L, and glucose of 10.1 mmol/L. His electrocardiogram showed sinus bradycardia with a rate of 54 beats per minute.

While in the ED, the patient remained persistently hypotensive with systolic blood pressure (SBP) of 50 mmHg and heart rate ranging from 50 to 60 beats per minute despite intravenous (IV) fluid resuscitation with 2.5 liters. He was given a total of 30 ml 10% Calcium Gluconate IV. However, BP was persistently low, so hyperinsulinemia euglycemia therapy (HIET) was initiated after discussion with the toxicologist. At the same time, dopamine infusion was given via peripheral line while a central line was being placed. Noradrenaline infusion was initiated, and his BP improved just before he was transferred to the ICU. The cardiothoracic (CTS) surgeon was also consulted for ECMO implantation (extracorporeal membrane oxygenation) as a backup plan during the early stage of management.

In the ICU, the patient continued to receive HIET (actrapid 1U/kg/hr) and noradrenaline (0.06mcg/kg/min). His SBP remained between 90 to 100 mmHg. However, four hours later, his BP dropped to 76/33. The requirement of HIET (actrapid 2U/kg/hr) and noradrenaline (0.25mcg/kg/min) were increased to support his BP. His arterial blood gas test showed worsening of non-high anion gap metabolic acidosis. The decision was made to intubate the patient, after which his condition stabilized and metabolic acidosis resolved. On day 2 of admission, the requirement for HIET and noradrenaline was decreased gradually while maintaining a stable SBP 90-110 mmHg. On day 3 of admission, he developed fever from

Staphylococcus epidermidis bacteremia, due to right arm phlebitis, and was treated with IV cloxacillin. On day 4 of admission, he also developed pneumonia with positive sputum culture for Staphylococcus aureus and Klebsiella pneumoniae and was treated with IV Piperacillin-Tazobactam. He remained stable despite ongoing sepsis and was weaned off of HIET and noradrenaline on the same day. On day 5 of admission, he was extubated successfully without any complications and discharged on day 7 of admission with intact neurological function.

DISCUSSION

Based on careful history taking and thorough physical examination, CCB overdose should be recognized as early as possible and prompt medical treatment should be initiated as soon as possible. A set of algorithms for CCB toxicity management is recommended by an international workgroup with expert consensus (2). Asymptomatic patients should be monitored from 6 to 36 hours, depending on the type of preparation that was ingested (3). Once airway and breathing have been established and secured, IV fluids should be administered for hypotension. If the patient shows signs of altered mental status, intubation and mechanical ventilation may be required. Gastrointestinal

decontamination with orogastric lavage or activated charcoal may be administered within 1-2 hours of ingestion. Whole bowel irrigation may be indicated in cases of massive overdose or ingestion of the extended release preparation. If additional therapies are needed to support BP, the following should be sequentially added until an adequate response is maintained: IV calcium salts (30 to 60 mL of 10% calcium gluconate solution or 10 to 20 mL of 10% calcium chloride solution), IV high-dose insulin and glucose (bolus of 1 unit/kg of regular insulin followed by an infusion of 0.5-2.0 units/kg/hr), and IV vasopressor (2 mcg/min of norepinephrine) (3).

TIMELINE

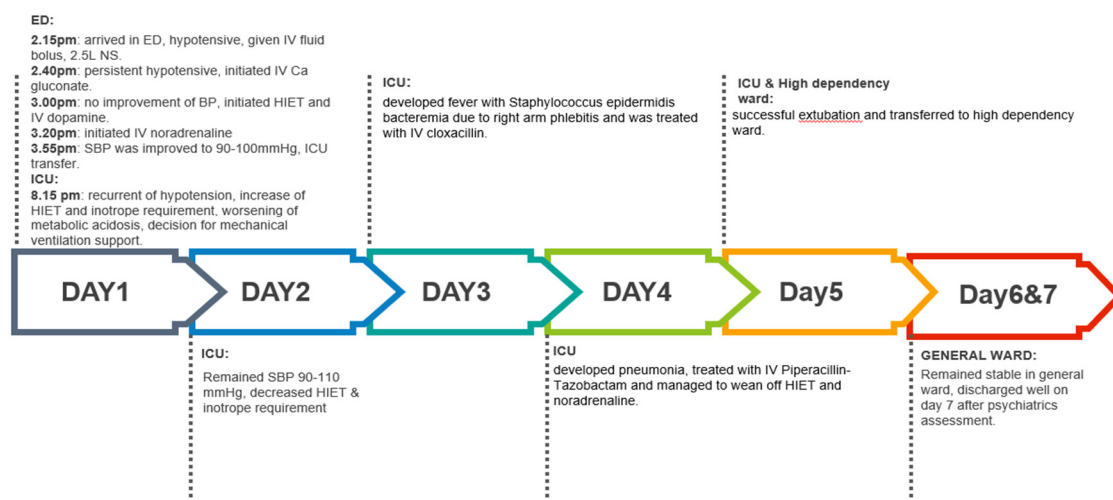


Figure 1. Timeline of the case

The level of evidence for interventions for CCB toxicity is low and mostly based on expert consensus recommendations (2). The following studies and mechanisms of action provide evidence for the use of the various treatments. IV calcium is recommended to increase calcium entry into cells via nonblocked channels, counteracting negative inotropy, and vasoplegia (3,4) which has been observed in some case series and animal studies (5). Regarding the use of HIET in CCBs-poisoned patients, observational studies, case series, and animal studies (5) documented an improvement in contractility, BP, and a potential increase in survival. The proposed mechanism involves improved smooth muscle contractility by increased efficiency of carbohydrate uptake and utilization which counteracts CCB's blockade of indigenous insulin release and decreased myocardial free fatty acid extraction (4). Regarding the use of adrenoceptor agonists, norepinephrine is used to increase BP in vasoplegic shock whereas epinephrine is used to increase contractility and heart rate (2). In the presence of confirmed myocardial dysfunction, clinicians can also use dobutamine and vasopressin (6). However, dopamine demonstrates inconsistent hemodynamic improvement in case series (2). Glucagon was observed to improve heart rate and cardiac output in animal studies and human case report (5) through activation of adenylate cyclase via G proteins resulting in positive chronotropic and inotropic effect.

Regarding lipid emulsion therapy, animal studies have associated its use with improved hemodynamic parameters and survival in animal models of verapamil poisoning (5). Also, two case series (7,8) and one case report (9) of human CCB toxicity demonstrate decreased mortality by using lipid emulsion therapy, particularly in the cases of refractory shock and cardiac arrest unresponsive to conventional treatments. However, there are case reports showing that lipid emulsion therapy is not effective in high-dose amlodipine intoxication (>280 mg) (10). Methylene blue has also been reportedly used as a novel approach to treat refractory CCB overdose by counteracting post-coronary artery bypass vasoplegia when added to vasopressors and HIET (1). Methylene blue resolves vasoplegia by decreasing intracellular cyclic guanosine monophosphate (cGMP), scavenging nitric oxide, and inhibiting nitric oxide synthesis, all in direct opposition to the action of CCBs (4).

ECMO has been used in amlodipine overdoses as a lifesaving measure in patients who are refractory to all other standard medical treatments. Venoarterial ECMO (VA-ECMO), which allows gas exchange and hemodynamic support, is a potential rescue therapy in CCB-poisoned patients presenting with cardiogenic shock or mixed shock. Case reports describe the use of VA-ECMO in a combined amlodipine, lisinopril and hydrochlorothiazide overdose and in a combined amlodipine and metoprolol overdose. The patients in both reports survived (11,12). However, complications of ECMO are common and it is associated with increase in morbidity and mortality, due to bleeding, systemic thromboembolism, and infection (13). In our case, ECMO was not initiated because the patient's BP and metabolic acidosis were improved after increasing the

dosage of HIET and noradrenaline and providing mechanical ventilation support.

CONCLUSION

CCB overdoses are challenging to treat, and the usual management can fail in cases with significant overdoses. It is important to do a careful history, thorough physical examination, and close monitoring, and to anticipate complications and treat them readily as they occur. Urgent administration of fluids, calcium, vasopressors, and HIET therapy seem to be the most well validated initial approaches to treatment, with the addition of the novel adjunct therapy being added into treatment based on necessity. Our successful management strategy should serve as a good learning experience as well as a recommendation for managing such patients.

Conflict of interest: None to be declared.

Funding and support: None.

REFERENCES

- Jang DH, Nelson LS, Hoffman RS. Methylene blue in the treatment of refractory shock from an amlodipine overdose. *Ann Emerg Med* 2011; 58:565-7.
- St-Onge M, Anseeuw K, Cantrell FL, Gilchrist IC, Hantson P, Bailey B., et al. Experts Consensus Recommendations for the Management of Calcium Channel Blocker Poisoning in Adults. *Crit Care Med* 2017; 45: e306-e315.
- Rana C, Das M, Traficante N, Kashani J. Massive Overdose of Calcium Channel Antagonist and Successful Management: A Case Report and Review of Management. *J Clin Toxicol* 2016; 6:319.
- Burkes, R, Wendorf G. A multifaceted approach to calcium channel blocker overdose: A case report and literature review. *Clin Case Rep* 2015; 3: 566-9.
- St-Onge M, Dubé PA, Gosselin S, et al. Treatment of calcium channel blocker poisoning: A systematic review. *Clin Toxicol* 2014; 52:92644.
- Kanagarajan K, Marraffa JM, Bouchard NC, Krishnan P, Hoffman RS, Stork CM. The use of vasopressin in the setting of recalcitrant hypotension due to calcium channel blocker overdose. *Clin Toxicol (Phila)*. 2007;45:56-9.
- Sebe A, Dişel NR, Açıklan Akpınar A, Karakoç E. Role of intravenous lipid emulsions in the management of calcium channel blocker and β -blocker overdose: 3 years experience of a university hospital. *Postgrad Med* 2015;127:119-24.
- Doepker B, Healy W, Cortez E, Adkins EJ. High-dose insulin and intravenous lipid emulsion therapy for cardiogenic shock induced by intentional calcium-channel blocker and Beta-blocker overdose: a case series. *J Emerg Med* 2014;46:486-90.
- Bekjarovski NG. Lipid Rescue Therapy and High-Dose insulin Euglycemic Therapy are Effective for Severe Refractory Calcium Channel Blocker Overdose: Case Report and Review of Literature. *Asia Pac J Med Toxicol* 2013; 2:114-6.
- Bozkurt FT, Izdes S, Demir HO, Kayar Calili D, Hosgun D. Intravenous Lipid Emulsion Treatment and High-Dose Amlodipine Intoxication: A Case Report. *Asia Pac J Med Toxicol* 2019;8:140-3.
- Weinberg RL, Bouchard NC, Abrams DC, Bacchetta M, Dzierba AL, Burkart KM, et al. Venoarterial extracorporeal membrane oxygenation for the management of massive amlodipine overdose. *Perfusion* 2014; 29: 53–6.

12. Maskell KF, Ferguson NM, Bain J, Wills BK. Survival after cardiac arrest: ECMO rescue therapy after amlodipine and metoprolol overdose. *Cardiovasc Toxicol* 2017 ;17:223-5.
13. George M, I-wen W. Extra Corporeal Membrane Oxygenation (ECMO) review of a lifesaving technology. *J Thorac Dis* 2015; 7: E166–E176.