





A Comparative Evaluation of Nephroprotective Property of *Urtica dioica* L. Aqueous Extract and Glibenclamide in Diabetic Mice

Mohammad Mahdi Zangeneh^{1,2} , Ghobad Mohammadi³, Saman Salmani², Payam Razeghi Tehrani⁴, Khodabakhsh Rashidi⁵, Akram Zangeneh^{1,2*} 

¹Biotechnology and Medicinal Plants Research Center, Ilam University of Medical Sciences, Ilam, Iran

²Department of Clinical Sciences, Faculty of Veterinary Medicine, Razi University, Kermanshah, Iran.

³Pharmaceutical Sciences Research Center, Health Institute, Faculty of Pharmacy, Kermanshah University of Medical Sciences, Kermanshah, Iran.

⁴Department of Basic Sciences, Faculty of Veterinary Medicine, Karaj Branch, Islamic Azad University, Karaj, Iran

⁵Research Center of Oils and Fats (RCOF), Kermanshah University of Medical Sciences, Kermanshah, Iran.

Abstract

Background and objectives: Diabetes is the most common metabolic disorder with severe effects on quality of life. Decreasing serum glucose levels and normalization of kidney parameters is of great clinical importance for treating diabetes. *Urtica dioica* L. has been used in as anti-inflammatory, antioxidant, anti-fungal, and antibacterial agent. To our knowledge, there are little evidences about the anti-diabetic and nephroprotective actions of *U. dioica* L. The present study was carried out to assess the anti-diabetic and nephroprotective activities of *U. dioica* aqueous extract (UDAE) in streptozotocin (STZ) induced diabetic mice for 20 days. **Methods:** Male mice were divided into six groups: normal control, untreated diabetic, diabetic mice receiving 30, 90 and 270 mg/kg of plant extract (groups UDAE30, UDAE90 and UDAE270, respectively) or 30 mg/kg glibenclamide. At 20th day, the mice killed, dissected, then blood and kidney samples were collected for biochemical and histological parameters analysis. **Results:** Biochemically, *U. dioica* aqueous extract at all doses and glibenclamide could significantly ($p \leq 0.05$) reduce the raised levels of blood glucose, urea and creatinine when compared to the untreated group. Histologically, different doses of *U. dioica* aqueous extract (especially UDAE270) and glibenclamide could significantly ($p \leq 0.05$) decrease the volume and length of the renal structures as compared to the untreated group. **Conclusion:** These results indicated *U. dioica* aqueous extract could improve diabetic related metabolic derangement such as hyperglycemia and elevated kidney markers.

Keywords: antidiabetic activity; aqueous extract; nephroprotective activity; streptozotocin; *Urtica dioica* L.

Citation: Zangeneh MM, Mohammadi G, Salmani S, Razeghi Tehrani P, Rashidi Kh, Zangeneh A. A comparative evaluation of nephroprotective property of *Urtica dioica* L. aqueous extract and glibenclamide in diabetic mice. Res J Pharmacogn. 2020; 7(1): 31-40.

Introduction

Diabetic kidney disease is one of the most frequent and perilous complications of diabetes mellitus, affecting about one-third of the patients [1]. In addition to the enhancing complexity of outpatient care for those with diabetes mellitus, diabetic kidney disease results in enhanced

hospitalizations and mortality rates, especially due to cardiovascular complications [1,2]. It also increases the demand for renal replacement therapies such as kidney transplants and dialysis [3]. The combined social and economic costs of this disease are high and of concern to the

* Corresponding author: Akramzangeneh@yahoo.com

world's health systems.

Diabetes-inducing chemicals such as streptozotocin (STZ) cause diabetic kidney disease [4]. STZ is the compound that is used as a diabetogenic agent in diabetes related experiments [4,5]. It is efficiently taken up by β -cells via the glucose transporter Glut2, causing diabetes by β -cell demolition [6,7]. In addition to β -cells, other tissues such as the kidney are also delicate to STZ toxicity [8,9] making it arduous to identify between diabetic nephropathy-related events and direct effects of STZ in these organs [10-12].

Findings from the screening of various ethno medicinal plants describe their antioxidant effects and reveal that they could protect kidney against STZ-induced oxidative stress by changing the levels of antioxidant enzymes [13-17]. Some medicinal plants have high content of alkaloids, flavonoids, naphthaquinone, saponins and triterpenes, so they can increase the quality and rate of nephrotoxicity [18-21].

Urtica dioica L grows widely in the western parts of the Iran. It is widely distributed throughout the temperate and tropical areas around the world In Iranian traditional medicine, the leaves and roots of the plant are used internally as blood purifier, diuretic, emmenagogue and for treatment of eczema, rheumatism, anaemia, nephritis, haematuria, nasal and menstrual haemorrhage, jaundice, menorrhagia and diarrhea [22-24]. *Urtica dioica* elaborates several classes of organic compounds of medicinal importance including phytosterols, flavanoids, saponins, tannins, sterols, carotenoids, fatty acids, chlorophylls, proteins, amino acids and vitamins [25-27]. The plant has been reported to have various pharmacological activities [26,28] such as anti-inflammatory, antioxidant [13], antibacterial, antimicrobial, antifungal [29-31], insecticide [32], hypocholesterolemic [33], hypoglycemic [34], antiulcer [35], anti-colitis, antiviral [25], anticancer [36], analgesic [29], natriuretic, hypotensive [37] antiandrogenic [38], immunomodulatory [39], cardiovascular [33], hepatoprotective [40] and anti-rheumatoid arthritis [41] effects.

In the present study, we have assessed the effects the *U. dioica* aqueous extract (UDA) by studying the microscopic structural changes in mice kidney after STZ-induced diabetic nephrotoxicity using modern design-based stereological methods. Renal functions were also

checked out by examining biochemical biomarkers.

Materials and Methods

Ethical considerations

The animal procedures were approved by standards of Payame Noor University of Kermanshah (No. 01/Z/G1395/12/01) on Humane Care and Use of Laboratory Animals, in accordance with the Research Ethics Committee of the Ministry of Health and Medical Education in Iran (adopted on April 17, 2006), based on the Helsinki Protocol (Helsinki, Finland, 1975). Also, animal studies were approved by Local Research Ethics Committee of Razi University, Kermanshah, Iran with the ethical code of 397-3-002.

Plant extraction

Urtica dioica was collected in July 2017 from Kermanshah province (in west of Iran). The plant was identified by the Central Herbarium of Agriculture and Natural Resources of Kermanshah province (Herbarium number 7806). The leaves of the plant were shade dried for one week. The dried aerial leaves of the plant were grinded, and about 200 g of the obtained powder was extracted with 2000 mL distilled water for 2 h at 40°C by continuous shaking. The extract was left for 24 h at room temperature; it was then filtered through Whatman paper no. 2. In rotary evaporator (Panchun Scientific Co., Kaohsiung, Taiwan), the extract was concentrated and lyophilized afterward.

Animals

Sixty male Balb/c mice weighing between 38-40 g were housed in an air-conditioned room (22±2 °C) and had free access to standard pellet diet and water ad libitum conditions during the study.

Experimental design

Diabetes was experimentally induced by intraperitoneal injection of STZ (60 mg/kg) in 50 mice. Fasting blood glucose levels were assessed everyday by glucometer strips. After three days, the mice with plasma glucose level > 250 mg/dL were considered diabetic [16]. The extract was dissolved in water and applied orally to mice (glibenclamide was also given orally).

The mice were divided into six following groups ($n=10$): I. Control group (C); II. Untreated-

diabetic group; III. Treated group with 30 mg/kg glibenclamide (G30); IV. Treated group with 30 mg/kg of the aqueous extract of UDAE (UDA30); V. Treated group with 90 mg/kg of the aqueous extract of UDAE (UDA90); VI. Treated group with 270 mg/kg of the aqueous extract of UDAE (UDA270) [16].

Blood sampling and determination of biochemical parameters

Blood samples were obtained in 0, 4, 7, 10, 13, 16, 20 days from tail vein to assess the blood glucose level by Easy Gluco glucometer (Ames, Korea). Twenty three days after diabetes induction and at the end of the 20th day of the treatment, the animals of all groups were euthanized by ketamine HCl (40 mg/kg). Immediately, blood samples were drawn from mice heart and inserted in serum tubes for determination of urea and creatinine.

Stereological study

Volume density

After dissection, the left kidney was weighed then fixed in 10% neutral buffered formalin solution for one week. Immersion method was used to evaluate the kidney primary volume. For assessment of kidney final volume, the amount of tissue shrinkage must be determined [42,43]. The sections of organ were prepared using orientator method. Totally, 7-10 slab were obtained from kidney. A circular piece was sampled from a kidney slab and the area of this piece was calculated. The slabs and circular piece were processed, sectioned (5 μm thicknesses) and stained by Periodic Acid Schiff (PAS) method. The area of the circular piece was calculated again and tissue shrinkage was measured [44]:

$$\text{Volume shrinkage} = 1 - (\text{AA}/\text{AB})^{1.5}$$

AA and AB: The area of the circular piece after and before tissue processing.

The total volume of the organ was then estimated using:

$$V_{\text{final}} = V_{\text{primary}} \times (1 - \text{Volume shrinkage})$$

Tissue sections were examined using a video microscopy system. The fractional volume of the renal structures was measured using a point probe (with an area of 100 cm² and containing 25 points) and following formula:

$$V_v = P_{\text{structure}}/P_{\text{reference}}$$

P_{structure}= sum of points hitting to the interested structures

P_{reference}= sum of points hitting to the reference space

Length density

The length density of the tubules and vessels was evaluated using an unbiased counting probe (740×740μm). The length density was estimated as:

$$L_v = 2 \times \sum Q/a(\text{frame}) \times \sum \text{frame}$$

∑Q = sum of the tubules counted, a (frame) = probe area, 547600μm², ∑frame = total number of the counted frames.

Statistical analysis

Data were expressed as mean ± SD and were analyzed by one way ANOVA and Duncan's test. p≤0.05 was considered significant.

Results and Discussion

The blood glucose levels of untreated diabetic mice enhanced to approximately 450% (p≤0.05) of the untreated-diabetic mice in a time-dependent manner. But, treatment of STZ-diabetic mice with the *U. dioica* aqueous extract at 30, 90 and 270 doses could significantly (p≤0.05) decrease the blood glucose levels similar to glibenclamide at the end of the experiment. Also, the difference among all doses of *U. dioica* aqueous extract was significant (p≤0.05) at several days. *U. dioica* aqueous extract showed most effect on day 20 of the experiment (figure 1).

The measured values of the kidney biochemical parameters have been indicated in figure 2. STZ-induced toxicity, increased urea and creatinine levels significantly (p≤0.05) as compared to the untreated group. Several doses of *U. dioica* aqueous extract and glibenclamide could significantly (p≤0.05) reduce the above parameters. There were no significant difference (p≤0.05) among *U. dioica* aqueous extract at all doses, glibenclamide and control groups in urea levels.

The results indicated that the kidney, cortical and medullary volumes increased (p≤0.05) in the untreated mice when compared to the control. Administration of *U. dioica* aqueous extract and

glibenclamide could significantly ($p \leq 0.05$) reduce the above parameters when compared to the untreated group (figure 3).

The volume of proximal convoluted tubule, distal convoluted tubule, collecting duct, loop of Henle, vessels and interstitial tissue enhanced significantly ($p \leq 0.05$) in untreated mice compared to the control ones (figures 4,5). Administration of *U. dioica* aqueous extract at all doses and glibenclamide to the mice could significantly ($p \leq 0.05$) reduce the volume of the

above structures in comparison with the untreated group. *Urtica dioica* aqueous extract at all doses significantly ($p \leq 0.05$) decreased the volumes of collecting duct, vessels and interstitial tissue similar to the glibenclamide group. Also there were no significant difference ($p \leq 0.05$) among UDAE270, glibenclamide and control groups in collecting duct and distal convoluted tubule volumes.

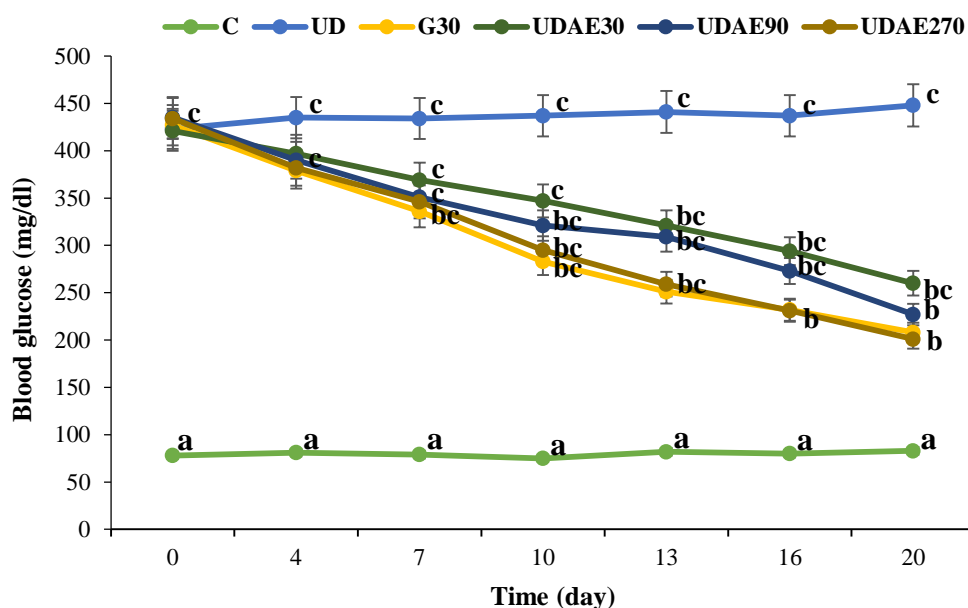


Figure 1. Blood glucose levels in different days of the experimental groups; C: control; UD: untreated diabetic; G30: treated diabetics with 30 mg/kg glibenclamide; UDAE30, UDAE90 and UDAE270: treated diabetics with 30, 90 and 270 mg/kg of *Urtica dioica* L. aqueous extract, respectively; non-identical letters indicate a significant difference between the groups ($p \leq 0.05$).

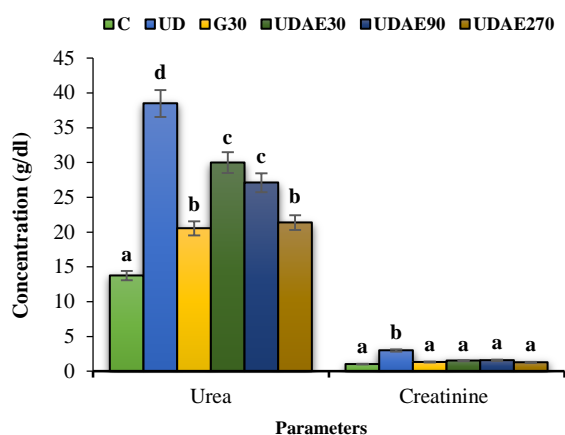


Figure 2. Urea and creatinine levels the experimental groups; C: control; UD: untreated diabetic; G30: treated diabetics with 30 mg/kg glibenclamide; UDAE30, UDAE90 and UDAE270: treated diabetics with 30, 90 and 270 mg/kg of *Urtica dioica* L. aqueous extract, respectively; non-identical letters indicate a significant difference between the groups ($p \leq 0.05$).

The data of the mean absolute lengths of kidney subcomponents in treated and untreated groups have been presented in figure 6. Lengths of the proximal convoluted tubule, distal convoluted tubule, collecting duct, loop of Henle and vessels were significantly ($p \leq 0.05$) enhanced in untreated mice compared to the control ones. *Urtica dioica* aqueous extract at all doses and glibenclamide could significantly ($p \leq 0.05$) reduce the lengths of the proximal convoluted tubule, distal convoluted tubule, collecting duct, loop of Henle and vessels compared to the untreated group ($p \leq 0.05$). No significant difference ($p \leq 0.05$) was observed among *U. dioica* aqueous extract at all doses and glibenclamide groups in collecting duct and distal convoluted tubule lengths. Also there were no significant differences ($p \leq 0.05$) among UDAE270, glibenclamide and control groups in length of loop of Henle.

The therapeutic benefits of herbal medicine have been recognized for centuries on the basis of clinical experience and practice [45-47]. They have the immense potential for the management and remedy of diseases such as nephrotoxicity [16,17]. A list of medicinal plants that have been consumed for their nephroprotective effects includes *Aerva javanica*, *Curcuma longa*, *Acorus calamus*, *Ficus religiosa*, *Rubia cardifolia*, *Boerhaavia diffusa*, *Tectona grandis*, *Crataeva nurvula*, *Tamarindus indica*, *Strychnos*

potatorum, *Carica papaya*, *Orthosiphon stamineus*, *Punica granatum*, *Euphorbia nerifolia*, *Aerva lanata* and *Vernonia cinerea* [48]. In this experimental study, the nephroprotective activity of *U. dioica* aqueous extract at several doses was determined in STZ-induced diabetes nephrotoxicity in mice model. To our knowledge, this is the first time *U. dioica* aqueous extract with these doses and methods has been used in experimentally induced diabetic in mice.

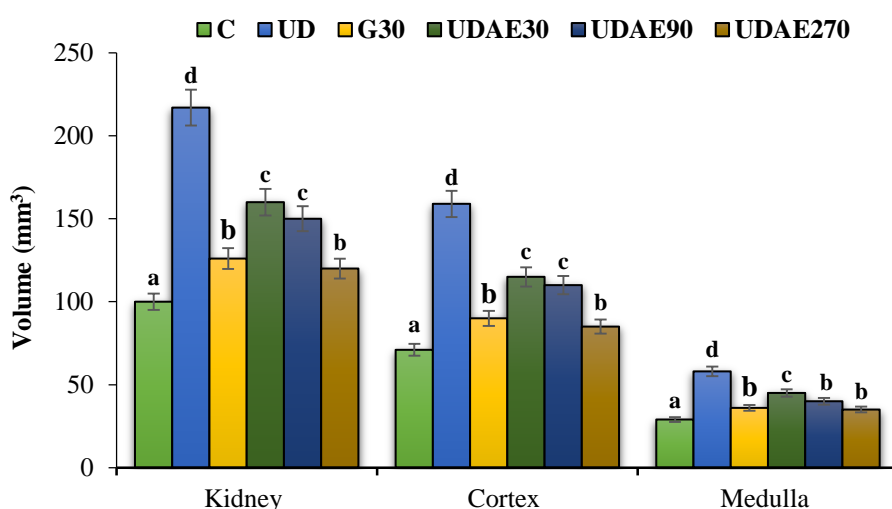


Figure 3. Absolute volume of the kidney cortex and medulla in all experimental groups; C: control; UD: untreated diabetic; G30: treated diabetics with 30 mg/kg glibenclamide; UDAE30, UDAE90 and UDAE270: treated diabetics with 30, 90 and 270 mg/kg of *Urtica dioica* L. aqueous extract, respectively; non-identical letters indicate a significant difference between the groups ($p \leq 0.05$).

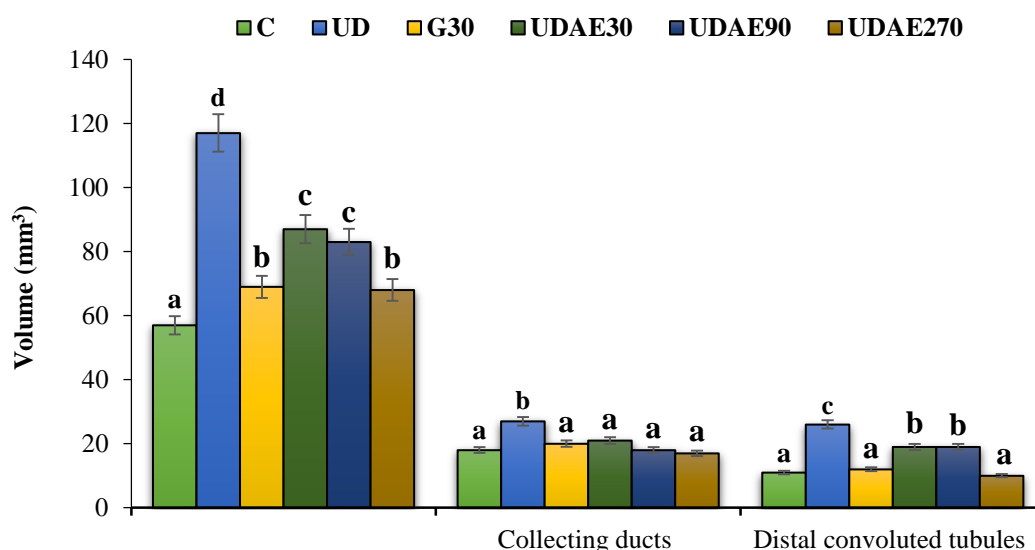


Figure 4. Absolute volume of proximal and distal convoluted tubules and collecting ducts in all experimental groups; C: control; UD: untreated diabetic; G30: treated diabetics with 30 mg/kg glibenclamide; UDAE30, UDAE90 and UDAE270: treated diabetics with 30, 90 and 270 mg/kg of *Urtica dioica* L. aqueous extract, respectively; non-identical letters indicate a significant difference between the groups ($p \leq 0.05$).

In the recent study, diabetes was induced in all mice by single intraperitoneal injection of STZ. STZ partially annihilates the beta cells of islets of Langerhans, nephron, hepatocytes and RBC

resulting in inexpressive insulin secretion causing type 2 diabetes, hepatotoxicity, nephrotoxicity and hematotoxicity [8,12].

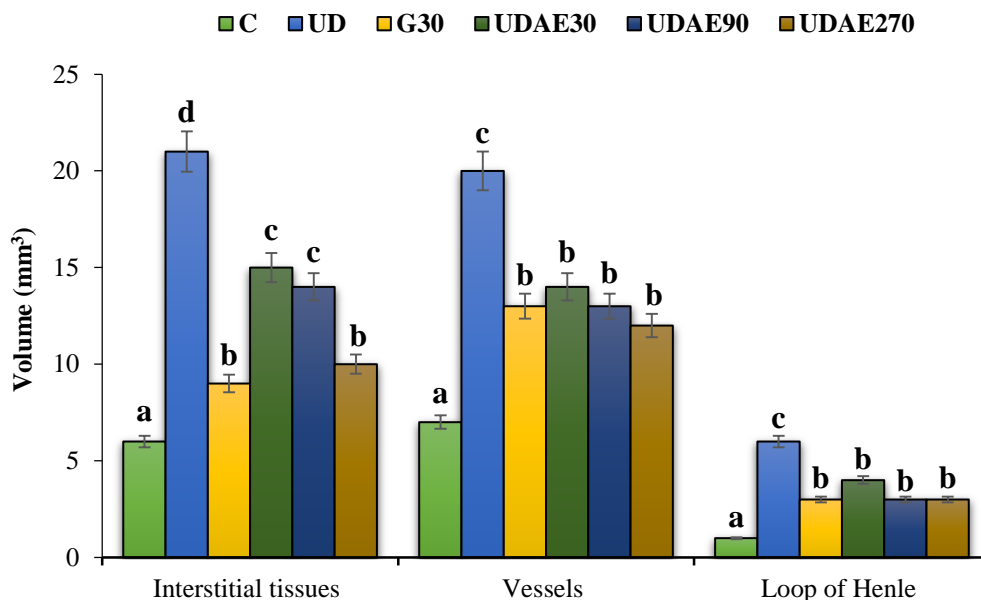


Figure 5. Absolute volume of interstitial tissues, vessels and loop of Henle in all experimental groups; C: control; UD: untreated diabetic; G30: treated diabetics with 30 mg/kg glibenclamide; UDAE30, UDAE90 and UDAE270: treated diabetics with 30, 90 and 270 mg/kg of *Urtica dioica* L. aqueous extract, respectively; non-identical letters indicate a significant difference between the groups ($p \leq 0.05$).

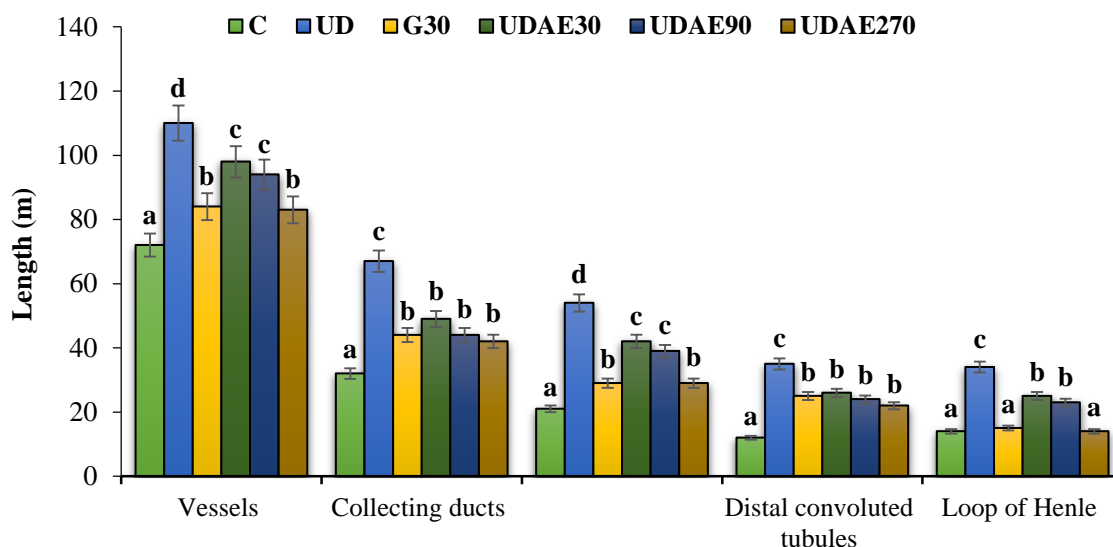


Figure 6. Absolute length (m) of the vessels, collecting ducts, proximal and distal convoluted tubules and loop of Henle; C: control; UD: untreated diabetic; G30: treated diabetics with 30 mg/kg glibenclamide; UDAE30, UDAE90 and UDAE270: treated diabetics with 30, 90 and 270 mg/kg of *Urtica dioica* L. aqueous extract, respectively; non-identical letters indicate a significant difference between the groups ($p \leq 0.05$).

The results of serum glucose levels indicated that UDAE90 and UDAE270 in 20th day had significant difference in comparison with untreated diabetic group; but, there were no significant differences between the experimental doses of *U. dioica* aqueous extract and classic anti-diabetic drug, glibenclamide in this day. The aqueous extract of plant 250 mg/kg had revealed a significant glucose lowering activity against alloxan induced diabetes in rats [49]. The fructose induced insulin resistance in male rats has been reported to reduce serum glucose level on administration of hydro- alcoholic leaf extract [50]. The cold methanol extract of leaves (250 mg/kg) has also indicated significant anti-hyperglycemic property in alloxan induced diabetes [51]. The leaf extract was administered in perfused islets of langerhans both in normal and streptozotocin induced diabetic rats which demonstrated a significant enhancement of insulin secretion thereby reducing the blood sugar level [52].

A renal inconvenience is assessed by the elevated histological examination as well as by serum levels of cytoplasmic parameters [53]. During the short term study, the administration of *U. dioica* aqueous extract ameliorated the renal morphological changes at all doses especially 270 mg/kg. Untreated mice revealed some degree of renal hypertrophy which was mainly due to the enlargement of the cortex, medullary and its subcomponents. The pathogenesis of kidney hypertrophy can be attributed to the overproduction of oxygen-free radicals following administration of toxins such as STZ, which is expressed in response to cytokines [8]. These changes were improved significantly with UDAE. The increased serum parameter levels such as creatinine and urea have been attributed to the blemished structural integrity of the kidney, because these are cytoplasmic in location and are released into the circulation after cellular injury [53]. In this study, we observed acute renal damage in toxic group mice following STZ administration manifested by: normal shifts in renal function tests (by increasing urea and creatinine) in renal tissue with altered histopathological signs as compared to the control mice; however, *U. dioica* aqueous extract at all doses and glibenclamide could significantly ($p \leq 0.05$) decrease the above parameters.

Finally, it can be concluded that the high dose of *U. dioica* aqueous extract had a nephroprotective

activity against renal structural changes induced by STZ in mice. Additional clinical trial studies would be needed to justify the potential of the plant as a nephroprotective agent in human.

Acknowledgments

The authors would like to thank the Razi University, Kermanshah, Iran for the financial support.

Author contributions

Mohammad Mahdi Zangeneh designed and performed the stereological plan and prepared the manuscript; Mohammad Mahdi Zangeneh and Akram Zangeneh performed the biochemical analysis; Ghobad Mohammadi prepared the plant extract and contributed in the statistical analysis; Khodabakhsh Rashidi, Saman Salmani, and Payam Razeghi Tehrani were involved in animal handling and treatments.

Declaration of interest

The authors declare that there is no conflict of interest. The authors alone are responsible for the content of the paper.

References

- [1] Kitabchi AE, Umpierrez GE, Miles JM, Fisher JN. Hyperglycemic crises in adult patients with diabetes. *Diabetes Care*. 2009; 32(7): 1335-1343.
- [2] De Fronzo RA. From the triumvirate to the ominous octet: a new paradigm for the treatment of type 2 diabetes mellitus. *Diabetes*. 2009; 58(4): 773-795.
- [3] Druker DJ. Enhancing incretin action for the treatment of type 2 diabetes. *Diabetes Care*. 2003; 26(10): 2929-2940.
- [4] Breyer MD, Bottinger E, Brosius FC, Coffman TM, Harris RC, Heilig CW, Sharma K. Mouse models of diabetic nephropathy. *J Am Soc Nephrol*. 2005; 16(1): 27-45.
- [5] Brosius FC, Alpers CE, Bottinger EP, Breyer MD, Coffman TM, Gurley SB, Harris RC, Kakoki M, Kretzler M, Leiter EH, Levi M, McIndoe RA, Sharma K, Smithies O, Susztak K, Takahashi N, Takahashi T. Mouse models of diabetic nephropathy. *J Am Soc Nephrol*. 2009; 20(12): 2503-2512.
- [6] Lenzen S. The mechanisms of alloxan- and streptozotocin-induced diabetes. *Diabetologia*. 2008; 51(2): 216-226.

- [7] Tesch GH, Allen TJ. Rodent models of streptozotocin induced diabetic nephropathy. *Nephrology (Carlton)*. 2007; 12(3): 261-266.
- [8] Rerup CC. Drugs producing diabetes through damage of the insulin secreting cells. *Pharmacol Rev*. 1970; 22(4): 485-518.
- [9] Weiss RB. Streptozocin: a review of its pharmacology, efficacy, and toxicity. *Cancer Treat Rep*. 1982; 66(3): 427-438.
- [10] Kraynak AR, Storer RD, Jensen RD, Kloss MW, Soper KA, Clair JH, DeLuca JG, Nichols WW, Eydeloth RS. Extent and persistence of streptozotocin-induced DNA damage and cell proliferation in rat kidney as determined by in vivo alkaline elution and BrdUrd labeling assays. *Toxicol Appl Pharmacol*. 1995; 135(2): 279-286.
- [11] Palm F, Ortster H, Hansell P, Liss P, Carlsson PO. Differentiating between effects of streptozotocin per se and subsequent hyperglycemia on renal function and metabolism in the streptozotocin diabetic rat model. *Diabetes Metab Res Rev*. 2004; 20(6): 452-459.
- [12] Tay YC, Wang Y, Kairaitis L, Rangan GK, Zhang C, Harris DCH. Can murine diabetic nephropathy be separated from superimposed acute renal failure? *Kidney Int*. 2005; 68(1): 391-398.
- [13] Farzaei MH, Zangeneh MM, Goodarzi N, Zangeneh A. Stereological assessment of nephroprotective effects of *Trachyspermum ammi* essential oil against carbon tetrachloride-induced nephrotoxicity in mice. *Int J Morphol*. 2018; 36(2): 750-757.
- [14] Hagh-Nazari L, Goodarzi N, Zangeneh MM, Zangeneh A, Tahvilian R, Moradi R. Stereological study of kidney in streptozotocin-induced diabetic mice treated with ethanolic extract of *Stevia rebaudiana* (bitter fraction). *Comp Clin Pathol*. 2007; 26(2): 455-463.
- [15] Najafi F, Goodarzi N, Zangeneh MM, Zangeneh A, Hagh-Nazari L. Antidiabetic and hepatoprotective effects of bitter fraction of *Stevia rebaudiana* alcoholic extract on streptozotocin-induced diabetic male mice. *J Rafsanjan Univ Med Sci*. 2007; 16(6): 493-504.
- [16] Zangeneh MM, Goodarzi N, Zangeneh A, Tahvilian R, Najafi F. Amelioration of renal structural changes in STZ-induced diabetic mice with ethanolic extract of *Allium saralicum* R.M. Fritsch. *Comp Clin Pathol*. 2018; 27(4): 861-867.
- [17] Zangeneh MM, Goodarzi N, Zangeneh A, Najafi F, Tahvilian R. Hypoglycemic, nephroprotective effects of aqueous extract of *Stevia rebaudiana* (sweet fraction) in streptozotocin-induced diabetic mice. *J Ardabil Univ Med Sci*. 2018; 17(4): 437-446.
- [18] Goodarzi N, Zangeneh MM, Zangeneh A, Najafi F, Tahvilian R. Protective effects of ethanolic extract of *Allium saralicum* R.M. Fritsch on CCl₄- induced hepatotoxicity in mice. *J Rafsanjan Univ Med Sci*. 2017; 16(3): 227-238.
- [19] Sherkatolabbasieh H, Hagh-Nazari L, Shafieezadeh S, Goodarzi N, Zangeneh MM, Zangeneh A. Ameliorative effect of the ethanolic extract of *Allium saralicum* R.M. Fritsch on CCl₄-induced nephrotoxicity in mice: A stereological examination. *Arch Biol Sci*. 2017; 69(3): 535-543.
- [20] Faramarzi E, Zangeneh MM, Zangeneh A, Moradi R. Effect of *Cinnamomum zelanicum* oil on hyponeophagia anxiety test in Balb C male mice. *Online J Vet Res*. 2017; 21(2): 77-80.
- [21] Ghashghaii A, Hashemnia M, Nikousefat Z, Zangeneh MM, Zangeneh A. Wound healing potential of methanolic extract of *Scrophularia striata* in rats. *Pharm Sci*. 2017; 23(4): 256-263.
- [22] Khare CP. Indian medicinal plants an illustrated dictionary. New York: Springer Science Business Media LLC, 2007.
- [23] Guil- Guerrero J, Rebollosa-Fuentes M, Torija Isasa M. Fatty acids and carotenoids from stinging nettle (*Urtica dioica* L.). *J Food Compost Anal*. 2003; 16(2): 111-119.
- [24] Wetherilt H. Evaluation of *Urtica* species as potential sources of important nutrients. *Dev Food Sci*. 1992; 29(1): 15-25.
- [25] Krystofova O, Adam V, Babula P, Zehnalek J, Beklova M, Havel L, Kizek R. Effects of various doses of selenite on stinging nettle (*Urtica dioica* L.). *Int J Environ Res Public Health*. 2010; 7(10): 3804-3815.
- [26] Rafajlovska V, Kavrakovski Z, Simonovska J, Srbinska M. Determination of protein and mineral contents in stinging nettle. *Qual Life*. 2013; 4(1-2): 26-30.
- [27] Kataki MS, Murugamani V, Rajkumari A, Mehra PS, Awasthi D, Yadav RS. Antioxidant, hepatoprotective and

- anthelmintic activities of methanol extract of *Urtica dioica* L. Leaves. *Pharm Crops*. 2012; 3(1): 38- 46.
- [28] Shackebaei D, Godini A, Abolghazi M, Majnoui M, Hesari M. Protection of ischemic and reperfused rat heart by aqueous extract of *Urtica dioica*. *Int Cardiovasc Res J*. 2010; 4(3): 107- 111.
- [29] Gulcin I, Kufrevioglu OI, Oktay M, Buyukokuroglu ME. Antioxidant, antimicrobial, antiulcer and analgesic activities of nettle (*Urtica dioica* L.). *J Ethnopharmacol*. 2004; 90(2-3): 205-215.
- [30] Hadizadeh I, Peivastegan B, Kolahi M. Antifungal activity of nettle (*Urtica dioica* L.), colocynth (*Citrullus colocynthis* L. Schrad), oleander (*Nerium oleander* L.) and konar (*Ziziphus spina-christi* L.) extracts on plants pathogenic fungi. *Pak J Biol Sci*. 2009; 12(1): 58- 63.
- [31] Modarresi-Chahardehi A, Ibrahim D, Fariza-Sulaiman S, Mousavi L. Screening antimicrobial activity of various extracts of *Urtica dioica*. *Rev Biol Trop*. 2012; 60(4): 1567- 1576.
- [32] Zlatko J, Miroslav K, Zorica P. Grain-protective properties of herbal extracts against the bean weevil *Acanthoscelides obtectus* Say. *Ind Crops Prod*. 2007; 26(1): 100- 104.
- [33] Alisi CS, Emejulu AA, Nwagou LA, Onyema OO. Decreased cardiovascular risk and resistance to hyperlipemia-induced hepatic damage in rats by aqueous extract of *Urtica dioica*. *Afr J Biochem Res*. 2008; 2(4): 102- 106.
- [34] Golalipour J, Khori V. The protective activity of *Urtica dioica* leaves on blood glucose concentration and beta-cells in streptozotocin-diabetic rats. *Pak J Biol Sci*. 2007; 10(8): 1200- 1204.
- [35] Wetherilt H. Nutritional evaluation of *Urtica* species. In: Kavalali G, Ed. *Urtica*. London: Taylor and Francis, 2003.
- [36] Koch E. Extracts from fruits of saw palmetto (*Sabal serrulata*) and roots of stinging nettle (*Urtica dioica*): viable alternatives in the medical treatment of benign prostatic hyperplasia and associated lower urinary tracts symptoms. *Planta Med*. 2001; 67(6): 489- 500.
- [37] Tahri A, Yamani S, Legssyer A, Aziz M, Mekhfi H, Bnouham M, Ziyat A. Acute diuretic, natriuretic and hypotensive effects of a continuous perfusion of aqueous extract of *Urtica dioica* in the rat. *J Ethnopharmacol*. 2000; 73(1-2): 95- 100.
- [38] Nahata A, Dixit VK. Evaluation of 5 α -reductase inhibitory activity of certain herbs useful as antiandrogens. *Andrologia*. 2014; 46(6): 592- 601.
- [39] Akbay P, Basaran AA, Undeger U, Basaran N. *In vitro* immunomodulatory activity of flavonoid glycosides from *Urtica dioica*. *Phytother Res*. 2003; 17(1): 34- 37.
- [40] Kanter M, Coskun O, Budancamanak M. Hepatoprotective effects of *Nigella sativa* L. and *Urtica dioica* Linn. on lipid peroxidation, antioxidant enzyme systems and liver enzymes in carbon tetrachloride-treated rats. *World J Gastroenterol*. 2005; 11(42): 6684- 6688.
- [41] Riehemann K, Behnke B, Schulze-Osthoff K. Plant extracts from stinging nettle (*Urtica dioica*), an anti-rheumatic remedy, inhibit the pro-inflammatory transcription factor NF- κ B. *FEBS Lett*. 1999; 442(1): 89- 94.
- [42] Braendgaard H, Gundersen HJ. The impact of recent stereological advances on quantitative studies of the nervous system. *J Neurosci Methods*. 1986; 18(1-2): 39-78.
- [43] Gundersen HJ, Bendtsen TF, Korbo L, Marcussen N, Møller A, Nielsen K, Nyengaard JR, Pakkenberg B, Sorensen FB, Vesterby A. Some new, simple and efficient stereological methods and their use in pathological research and diagnosis. *Acta Pathol Microbiol Immunol Scand*. 1992; 96(5): 379-394.
- [44] Mandarim-de-Lacerda CA. Stereological tools in biomedical research. *An Acad Bras Cienc*. 2003; 75(4): 469-486.
- [45] Moradi R, Hajialiani M, Zangeneh MM, Zangeneh A, Tahvilian R, Hidaryan H, Rezaeeasl N, Kohneshin A. Antibacterial properties of an Iranian ethnomedicinal plant. *Int J Ayu Pharm Chem*. 2017; 6(3): 128-137.
- [46] Poorshamohammad C, Souri N, Amini Z, Kosari F, Jamshidpour R, Zangeneh MM, Zangeneh A. *Cucurbita moschata*: a plant with antibacterial properties. *Int J Curr Med Pharm Res*. 2017; 3(2): 1356-1359.
- [47] Pooyanmehr M, Zangeneh MM, Zangeneh A, Almasi M. Effect of *Verbascum thapsus* aqueous extract on *Escherichia coli* O157:H7.

- Online J Vet Res.* 2017; 21(9): 580-583.
- [48] Mohana-Lakshmi S, Usha-Kiran-Reddy T, Sandhya-Rani KS. A review on medicinal plants for nephroprotective activity. *Asian J Pharm Clin Res.* 2012; 5(4): 8-14.
- [49] Grevsen K, Frette XC, Christensen LP. Concentration and composition of flavonol glycosides and phenolic acids in aerial plants of stinging nettles (*Urtica dioica* L.) are affected by nitrogen fertilization and by harvest time. *Eur J Horticult Sci.* 2008; 73(1): 20- 27.
- [50] Ahangarpour A, Mohammadian M, Dianat M. Antidiabetic effect of hydroalcoholic *Urtica dioica* leaf extract in male rats with fructose- induced insulin resistance. *Iran J Med Sci.* 2012; 37(3): 181- 186.
- [51] Al- Wasfi RM, Jabaar Al- Kaabee HJ, Dergham M, Hameed AF. Studying the hypoglycemic and the antibacterial activity of various plant extract of *Urtica dioica*. *Al- kufa J Biol.* 2012; 4(2): 232- 242.
- [52] Farzami B, Ahmadvand D, Vardasbi S, Majin FJ, Khaghani Sh. Induction of insulin secretion by a component of *Urtica dioica* leave extract in perfused Islets of Langerhans and its *in vivo* effects in normal and streptozotocin diabetic rats. *J Ethnopharmacol.* 2003; 89(1): 47- 53.
- [53] Mishra S, Ranjan-Pani S, Sahoo S. Anti-nephrotoxic activity of some medicinal plants from tribal rich pockets of Odisha. *Pharmacogn Res.* 2014; 6(3): 210-217.

Abbreviations

UDAЕ: *Urtica dioica* L. aqueous extract