

Neonatal Urinary Ascites: A Case Report

*Gholamreza Sarvari ¹, Fateme Ghane Sharbaf ²

¹Assistant Professor of Pediatric Nephrology, Department of Pediatric Nephrology, Dr. Sheikh Hospital, Mashhad University of Medical Sciences, Mashhad, Iran.

²Associate Professor of Pediatric Nephrology, Department of Pediatric Nephrology, Dr. Sheikh Hospital, Mashhad University of Medical Sciences, Mashhad, Iran.

Abstract

Introduction

One of the rare problems in newborns is ascites. Almost 30 percent of neonatal ascites is caused by urinary disease. The most common cause is urinary tract obstruction from posterior urethral valve.

Case Report

In this case report, we present a two-day boy with urinary ascites at Akbar hospital Mashhad, Iran, it was initially thought the ascites have liver origin.

Conclusion

In conclusion the causes of the ascites should be determined for treatment management. This can be achieved by analysis of the ascites fluid. Although urinary ascites is a very rare condition, it needs rapid management to gain a good outcome.

Key Words: Hyperbilirubinemia, Neonate, Urinary ascites.

*Please cite this article as: Sarvari Gh, Ghane Sharbaf F. Neonatal Urinary Ascites: A Case Report. Int J Pediatr 2019; 7(12): 10481-484. DOI: **10.22038/ijp.2019.41642.3508**

*Corresponding Author:

Gholamreza Sarvari (M.D), Department of Pediatric Nephrology, Dr. Sheikh Hospital, Mashhad University of Medical Sciences, Mashhad, Iran.

Email: sarvarir@mums.ac.ir

Received date: Aug.14, 2019; Accepted date: Nov.12, 2019

1- INTRODUCTION

One of the rare problems in newborns is ascites and various reasons can be responsible for this condition such as liver and biliary nature, infectious disease, urinary disease or unknown nature (1). Almost 30 percent of neonatal ascites is caused by urinary disease. The most common cause is urinary tract obstruction from posterior urethral valve (2). Diagnosis is based on renal function and is confirmed by imaging (3). In this case report, we present a patient with urinary ascites that was initially thought to have liver origin.

2- CASE REPORTS

A two-day old boy was born as full term weighing 2,700 grams by uncomplicated vaginal delivery in a hospital and was referred to PICU at Akbar hospital Mashhad, Iran, due to icter

(total bilirubin 21.2 mg/dl and direct bilirubin 2.9 mg/dl), and distention of abdomen. He was oliguric. Abdominal ultrasonography was done and showed ascites with left lateral mild hydronephrosis and thick and irregular bladder wall. At first, due to neonatal direct hyperbilirubinemia ascites was thought to have liver origin. The TORCH study (Toxoplasmosis, Others, Rubella, Cytomegalovirus, Herpes) was done to determine intrauterine infections and it was negative. Ascites tap was performed and revealed high creatinine 2mg/dl compared to serum creatinine of 1.1mg/dl. Other biochemical values are shown in the **Table.1**. Urinary output was improved after catheterization and blood creatinine was dropped from 1.1mg/dl to 0.4mg/dl. Ascites recovered after 150 mL paracentesis.

Table-1: Biochemical values for plasma, ascetic fluid, and urine taken simultaneously in neonate.

Biochemical parameters	Ascetic Fluid	Plasma	Urine
Urea (mg/dl)	63	45	382
Creatinine (mg/dl)	2	1.1	10.5
Protein (g/dl)	1	6	-
Albumin (g/dl)	0.5	4.1	-

Micturition cystourethrography was performed 22 days later and showed posterior urethral valve and trabeculated bladder wall and a grade 5 vesicoureteral reflux in right side. Urinary extravasation or bladder perforation on MCU was not detected. The patient underwent

cystoscopy and valvectomy after stabilization. Liver biopsy was done due to cholestasis and revealed cholestatic liver disease with mild interlobular fibrosis and due to being a small specimen with only two portal tracts, precise evaluation of portal bile duct was impossible.

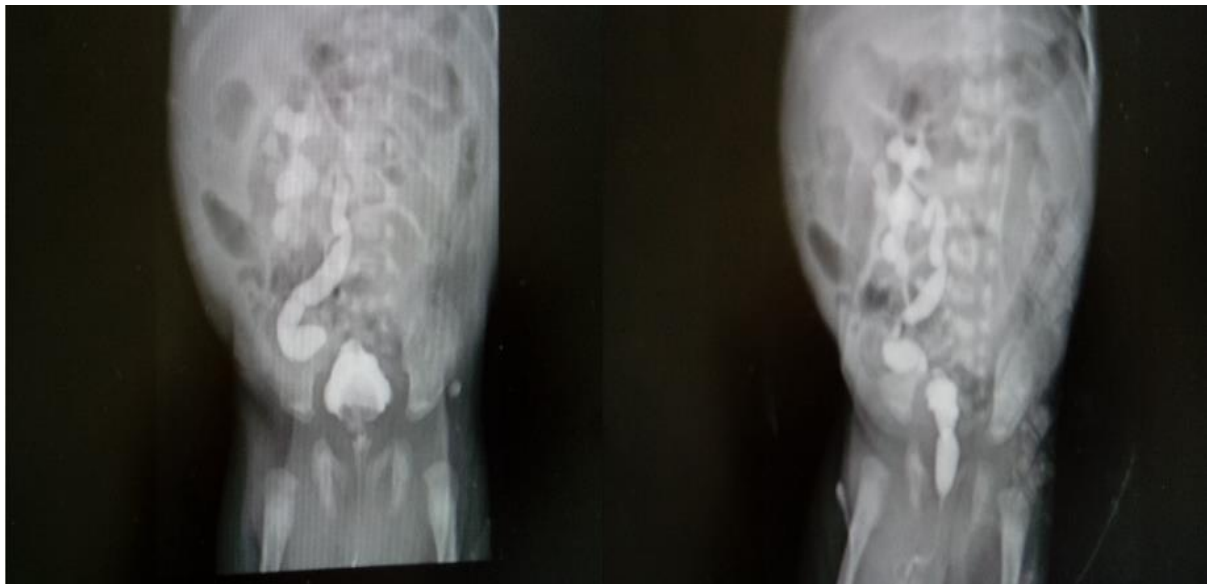


Fig.1: Micturition Cystourethrography in neonate.

3- DISCUSSION

Urinary ascites occurs more often in boys who have urinary tract obstruction. The major sign is renal insufficiency in these patients (4). Different reasons have been stated for the urinary ascites that is a very rare condition. The most common cause is posterior urethral valve that includes almost 70% of the etiology. It usually happens when the internal pressure rises and makes calyceal fornixes rupture, urinary bladder perforation rarely happens in posterior urethral valve (1, 5).

Other predisposing factors besides posterior urethral valves include neurogenic bladder, congenital bladder diverticulum, and detrusor areflexia. Spontaneous or iatrogenic bladder rupture is also another cause of urinary ascites. Rupture may occur after long-term exposure to hypoxia that lead to bladder ischemic lesions (2). Rattan et al. reported a rare case of urinary ascites due to spontaneous bladder rupture in a preterm female newborn. The symptoms of neonatal bladder rupture are the ascites becoming worse, oliguria, deranged renal functions, and respiratory distress (6). There are also no obvious predisposing factors for the rupture and it is likely

associated with obstructive uropathy, abdominal trauma, neurogenic bladder, difficult obstetric delivery, and iatrogenic injuries during urethral and umbilical catheterization (2). By reviewing the literature, we found a case with neonatal bladder rupture after umbilical catheterization (7). Urinary retention as a result of morphine administration is another cause of bladder rupture (2). The diagnosis procedure of ascites is done by abdominal X-ray or ultrasound but diagnosing the origin of it is important for further management (2).

Only urinary ascites can increase the urea and creatinine concentrations of the ascetic fluid are more than those of plasma. In addition, in ascites fluid of another origin the protein concentration is much higher (8). This distinction can help the diagnosis. In our patient the creatinine level of the ascites fluid was higher than the plasma, and its lower protein revealed urinary origin of ascites. We did not see any evidence of fluid extravasation into the abdominal cavity in voiding cystourethrography due to the fact that voiding cystourethrography (VCUG) was done with delay after ascites improvement.

4- CONCLUSION

Although urinary ascites is a very rare problem in neonates, it is important to diagnose and treat it quickly. The causes of the ascites should be determined for the treatment management. There are many differential diagnoses in patients with urinary ascites. This can be diagnosed by ultrasonography and analysis of the ascites fluid. We should also consider the renal cause of the ascites in the hydronephrosis or thick bladder wall cases and especially in the male patients. Finally, although urinary ascites is very rare condition, it needs rapid management to gain a good outcome.

5- ACKNOWLEDGEMENTS

The authors would like to thank Akbar Pediatric Hospital for their cooperation and also Ms. Shiva Ghaderifar for editing the manuscript.

6- CONFLICT OF INTEREST: None.

7- REFERENCES

1. Singh J, Khanna A, Arora S. A Rare Case of Urinary Ascites in Newborn. *International Journal of Medical and Dental Sciences*. 2016;5(1):1098-100.
2. Oei J, Garvey P, Rosenberg A. The diagnosis and management of neonatal urinary ascites. *Journal of paediatrics and child health*. 2001;37(5):513-5.
3. Solarin A, Gajjar P, Nourse P. Neonatal urinary ascites: a report of three cases. *Case reports in nephrology*. 2015;2015.
4. Zani-Ruttenstock E, Zani A. Neonatal Ascites. Puri P, editor: Springer, Berlin, Heidelberg; 2017. pp.1-8.
5. Gupta P, Gupta AK, Aggarwala S. Urinary ascites secondary to bladder perforation in a neonate with posterior urethral valves. *Oman Med J*. 2013;28:42-3.
6. Rattan KN, Singh J, Dalal P, Rattan A. Urinary ascites in a preterm female neonate: a

rare case report. *Annals of Pediatric Surgery*. 2017;13(4):228-31.

7. Sayan A, Demircan M, Erikci V, Çelik A, Arikan A. Neonatal bladder rupture: an unusual complication of umbilical catheterization. *European journal of pediatric surgery*. 1996;6(06):378-9.

8. Morrell P, Coulthard M, Hey E. Neonatal urinary ascites. *Archives of disease in childhood*. 1985;60(7):676-8.