

Unusual Presentation of Orf Disease on a Thermal Burn Scar

Sadegh Vahabi-Amlashi¹, Faezeh Taghavi², Naser Tayyebi Meibodi³, *Maryam Mahdavi²

¹Cutaneous Leishmaniasis Research Center, Mashhad University of Medical Sciences, Mashhad, Iran.

²Student Research Committee, Mashhad University of Medical Sciences, Mashhad, Iran.

³Professor of Pathology, Cutaneous Leishmaniasis Research Center, Mashhad University of Medical Sciences, Mashhad, Iran.

Abstract

Introduction

Orf disease is a viral disease of sheep and goats that can appear in humans too. The usual presentation is in sites that have direct contact. Clinical manifestation of Orf disease may be unusual in burn patients.

Case Report

In this case report, we described a rare presentation of Orf disease on a burn scar of a two-year girl. The patient had a history of animal contact and the presence of Orf virus was confirmed using pathologic studies and Polymerase Chain Reaction (PCR).

Conclusion

Few other reports of Orf disease on a burn scar are also available in scientific literature which propose the higher risk of these patients for development of Orf disease.

Key Words: Burn, Child, Orf, Scar.

*Please cite this article as: Vahabi-Amlashi S, Taghavi F, Tayyebi Meibodi N, Mahdavi M. Unusual Presentation of Orf Disease on a Thermal Burn Scar. Int J Pediatr 2019; 7(12): 10493-497. DOI: **10.22038/ijp.2019.41939.3534**

*Corresponding Author:

Maryam Mahdavi (MD), Student Research Committee, Mashhad University of Medical Sciences, Mashhad, Iran. Fax: +985138583845

Email: mahdaviam951@mums.ac.ir

Received date: Mar.24, 2019; Accepted date: Nov.12, 2019

1- INTRODUCTION

Orf disease is caused by the *Parapox* virus and usually infects sheep and goats, but can also cause disease in humans. Its incubation period is around 3 to 7 days. The classic clinical manifestations include a few individual lesions in the location of direct contact with the infected animal - usually the fingers. Initially the lesion is a small firm erythematous papule that evolves into a vesicle, pustule and finally a hemorrhagic bullae. Sometimes fever and lymphadenopathy accompany the lesions. Uncomplicated lesions heal spontaneously during a period of 3 to 6 weeks. Large and treatment resistant lesions were reported in immunosuppressed patients and patients with atopic dermatitis (1). Parapoxvirus infection in an immunocompromised or immunosuppressed individual can lead to the development of more severe infections or lesions that are confused with tumors (2). Here we describe an unusual presentation of Orf disease on a burn scar of a patient.

2- CASE REPORTS

Our patient was a 2-year and 8 month-old girl without any significant past medical history that was presented to our dermatology clinic in Imam Reza hospital in Mashhad, Iran, with papulonodular erythematous exophytic lesions. She was hospitalized one month earlier in the burn ward due to second and third degree thermal burns with boiling water on her

shoulder, arm and upper thorax. Eleven days after the burning she developed papular erythematous lesions on his burn scars that continued to expand in size. At the time she referred to the dermatology clinic she had multiple diffuse papular and nodular lesions on the burn scars that were erythematous, firm and had a diameter of 2 to 15 mm (**Figures 1A, 1B**). Patient's father was a stockman and the patient herself had a history of multiple direct contacts with domesticated animals. Her general appearance was good and she had no fever or lymphadenopathy. Patient underwent biopsy from lesions with a differential diagnosis of pyogenic granuloma and granulomatous diseases such as typical or atypical mycobacterium, deep fungal infections, sarcoidosis, and granuloma annulare. Pathologic assessment of acquired specimens with routine *H&E* (Haematoxylin and Eosin *stains*) showed epidermal hyperplasia, focal degeneration of keratinocytes and pale keratinocytes with a few eosinophilic cytoplasmic inclusions, edema of the superficial dermis, vascularization that were compatible with a viral disease (**Figure.1**). Orf virus's DNA was detected using real-time PCR on paraffin fixed samples. The patient was diagnosed with Orf disease and received supportive treatment. Two weeks later the lesions had regressed significantly and 4 weeks later lesions healed without any complications or residual scarring (**Figure.2C**).

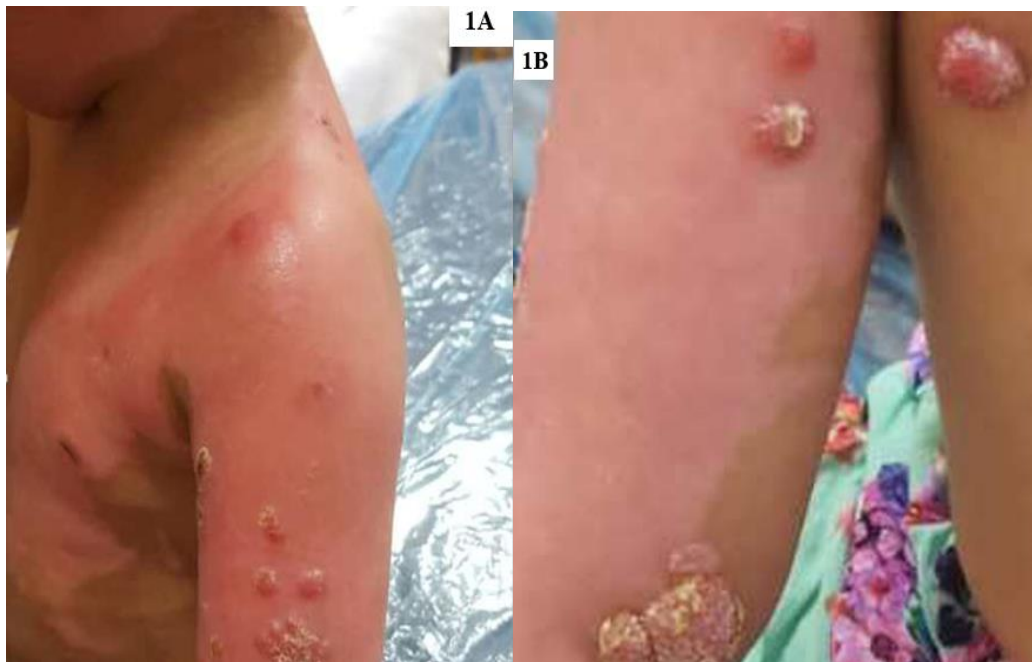

Fig.1 (A & B): Epidermal hyperplasia, focal degeneration of keratinocytes and pale keratinocytes with a few eosinophilic cytoplasmic inclusions (haematoxylin–eosin, original magnification A× 40 - B ×100).

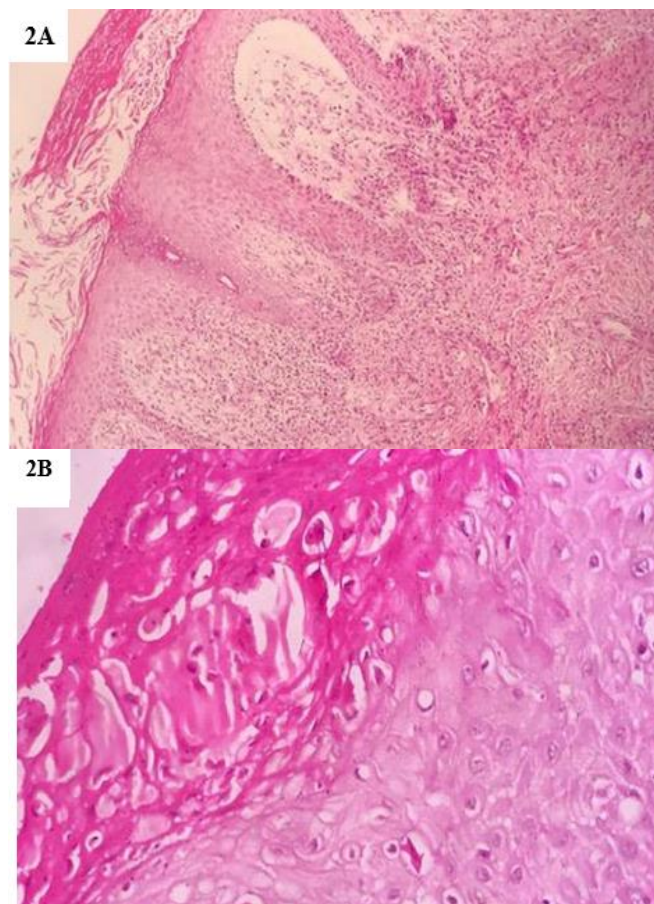

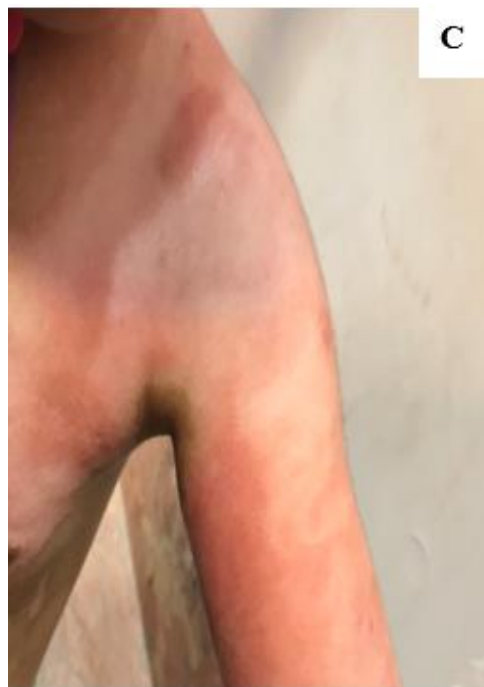


Fig.2: (A & B) Multiple papular and nodular lesions on the shoulder and arm burn scars in a 32 month-old girl; (C) 4 weeks later lesions disappear without any scar.

3- DISCUSSION

Clinical manifestation of Orf disease may be unusual in burn patients due to the damage of the epidermal barrier. Lesions can be large, multiple and sometimes exophytic that spread to adjacent skin (3). Moreover, the wound healing process of burns may be a trigger for development of the pyogenic granuloma (4). Parapoxvirus infections are generally self-limiting; however, burn patients are uniquely at risk for complicated Orf virus infections because of the breakdown of the epidermal barrier (4, 5). The focal immunosuppression present at the burn lesion may hamper the response to infectious agents; this may explain the unusual manifestations of the disease in burn location. Detection of the Orf specific monoclonal antibody in the blood using ELISA or western blot techniques can be used in diagnosis of the disease. The virus grows slowly and inconsistently in vitro, therefore, cultures are not used as a diagnostic method. PCR diagnostic test has

a high specificity for detection of Orf virus and recently, the real-time PCR has been used for the detection of *Parapox* DNA (6). No specific treatment is available for Orf disease due to its self-limiting nature. The management consists of supportive measures and treatment of secondary infections. Previously, successful treatment of complicated Orf with Imiquimod was reported. Other treatment options for Orf include cidofovir cream and cryotherapy especially in immunocompromised patients (6).

4- CONCLUSION

Atypical manifestations of Orf disease should be considered in patients with burn lesions and immunosuppressed patients, especially those with a history of animal contact. Considering the self-limiting nature of Orf disease, its accurate diagnosis can prevent the administration of unnecessary treatments.

5- CONFLICT OF INTEREST: None.

6- REFERENCES

1. Contagiosum E, Stomatitis CP, Mouth S. Species Affected. 2005.
2. Griffin GE. Measles virus. Fields virology. 2007.
3. Osadebe LU, Manthiram K, McCollum AM, Li Y, Emerson GL, Gallardo-Romero NF, et al. Novel poxvirus infection in 2 patients from the United States. Clin Infect Dis. 2014; 60(2):195-202.
4. Biyik Ozkaya D, Taskın B, Tas B, Asıran Serdar Z, Demirkesen C, Su O, et al. Poxvirus-induced angiogenesis after a thermal burn. J Dermatol. 2014; 41(9):830-3.
5. Midilli K, Erkılıç A, Kuşkuçu M, Analay H, Erkılıç S, Benzonana N, et al. Nosocomial outbreak of disseminated orf infection in a burn unit, Gaziantep, Turkey, October to December 2012. Euro surveill. 2013; 18(11):20425.
6. Cubells JR, Braverman I, Kashgarian M, Lazova R. A 65-year-old female from Connecticut with orf infection. Dermatopathology. 2016; 3(2):55-60.