

## Mumijo Protection against Acetaminophen-Induced Acute Hepatic Injury: Role of Oxidative Stress

Jabber Atashbar, B.Sc.<sup>1</sup>, Nader Shahrokhi, Ph.D.<sup>2</sup>, Mohammad Khaksari Haddad, Ph.D.<sup>3</sup>, Gholamreza Asadi Karam, Ph.D.<sup>4</sup>, Nava Shahrokhi,<sup>5</sup> Farhood Ghazi, B.Sc.<sup>6</sup>

1- MSc Student in Physiology, Physiology Research Center, Institute of Basic and Clinical Physiology Sciences, Kerman University of Medical Sciences, Kerman, Iran

2- Associate Professor of Physiology, Physiology Research Center, Institute of Basic and Clinical Physiology Sciences, Kerman University of Medical Sciences, Kerman, Iran (Corresponding author; nshahrokhisa@yahoo.com)

3- Professor of Physiology, Endocrinology and Metabolism Research Center, Kerman University of Medical Sciences, Kerman, Iran

4- Professor of Biochemistry, Cardiovascular Research Center, Institute of Basic and Clinical Physiology Sciences, Kerman University of Medical Sciences, Kerman, Iran

5- Medical Student, Afzalipour School of Medicine, Kerman University of Medical Sciences, Kerman, Iran

6- MSc Student in Physiology, Gastroenterology and Hepatology Research Center, Kerman University of Medical Sciences, Kerman, Iran

Received: 4 July, 2017

Accepted: 22 February, 2018

### ARTICLE INFO

#### Article type:

Original article

#### Keywords:

Acetaminophen

Mumijo

Liver

Oxidative stress

### Abstract

**Background:** A majority of people widely use acetaminophen as a sedative. Overusing the drug for prolonged periods of time can lead to acute liver damage. Mumijo, as a strong antioxidant and anti-inflammatory drug, could possibly reduce some of the acetaminophen-induced side effects on the liver. Thus, the aim of this study is to evaluate the effect of Mumijo on the liver damage caused by the use of acetaminophen.

**Methods:** 40 male Wistar rats were randomly divided into five groups: sham, acetaminophen, low and high doses of mumijo, and vehicle. All groups except the sham group received a single dose of 500 mg/kg acetaminophen via ip injection. Then the groups that were under treatment received 150 mg/kg (low dose) and 250 mg/kg (high dose) of mumijo, and the vehicle group received distilled water as vehicle. After 24 hours, blood samples were taken for biochemical tests, and a part of the liver was extracted for histopathological examination.

**Results:** acetaminophen increases the activities of functional liver enzymes including alanine aminotransferase (ALT), aspartate aminotransferase (AST), and gamma glutamine transferase (GGT). In groups under treatment, values of the mentioned enzymes were significantly reduced in comparison with the acetaminophen and vehicle groups ( $P < 0.05$ ), and on the other hand, malondialdehyde (MDA), nitric oxide (NO), and protein carbonyl (PC) increase caused by acetaminophen were reduced by mumijo. Furthermore, the amount of glutathione (GPX) was increased by mumijo ( $P < 0.05$ ). From a histopathological point of view, necrosis and liver damage caused by acetaminophen was decreased by mumijo.

**Conclusion:** The findings showed that mumijo is salient in preventing liver damage caused by consumption of high doses of acetaminophen probably through reducing oxidant activities and also through increasing anti-inflammatory and antioxidant activities.

### Introduction

Acetaminophen is one of the most widely used analgesic and anti-fever drugs readily available to the public (1). Toxicity

(overdose) of acetaminophen is a cause of liver damage. After consuming this drug, a part of it is metabolized by cytochrome isomers P450 (cyp450) including CYP2E1, CYP3A, and

CYP1A2 (2). As a result, the toxic metabolite of acetaminophen, N-acetyl-p-benzoquinoneimine (NAPQI), which is detoxified by coupling of the glutathione under natural conditions, is produced (2). In acetaminophen overdose, after the removal of cellular glutathione, NAPQI is attached to cellular macromolecules causing liver cell damage and cell death (3). It has been reported that when the reserves of glutathione is less than 30%, acetaminophen toxicity is created in the liver (3). In this case, the toxic metabolite of acetaminophen with mitochondrial and cytosolic proteins and leads to dysfunction of mitochondria and consequently, cell death (4, 5).

Among mechanisms through which acetaminophen causes liver damage, one can name cytochrome P450, a reactive metabolite that results in the removal of glutathione and increased formation of active oxygen and nitrogen species in liver cells. In addition, the use of acetaminophen may lead to increased oxidative stress, altered calcium homeostasis, immediate mitochondrial permeability, removal of membrane potential of mitochondria, removal of the ability of mitochondria to make ATP, and necrosis (1).

The main risk of acetaminophen toxicity is liver necrosis, which is accompanied by a significant increase in serum levels of AST, ALT and LDH 500 times above normal (6,7).

Herbal treatment is one of the basic methods in traditional medicine and has been primarily used to prevent disease and to enhance health (8). It has been reported that the antioxidant and anti-inflammatory substances, including the antioxidant activity of *Boerhaavia diffusa* leaf extract, whose hepatoprotective role in acetaminophen-induced liver damage has been determined, play a protective role in liver damage (9).

Natural mumijsubstance, under the scientific name of Shilajit, is a light brownish material obtained from rocks in some mountain ranges (10). According to recent reports, Mumijohas a very strong anti-inflammatory (11-13), antioxidant (14-16), and relaxing effects (10). It can cause an increase in the activity of superoxide dismutase (SOD), catalase (CAT) and glutathione peroxidase (GPX) in the striatum and frontal cortex in rats (14). Our group's research also showed that the substance has antioxidant and anti-inflammatory effects on traumatic brain damage (17).

With regard to the above-mentioned points, compounds that have antioxidant and anti-inflammatory properties could possibly play a protective role in acetaminophen-induced liver damage. Since mumijo has anti-inflammatory and antioxidant effects and there are few studies on the possible protective effects of this substance on the types of toxicity in the liver disorders, the aim of this study is to investigate the effects of mumijoon acetaminophen-induced liver damage and to determine some of its mechanisms in male rats.

### Materials and methods

In this experimental study, male Wistar rats weighing 250-300 g were used. The animals were kept in natural conditions for 12 hours of light and 12 hours of darkness with standard diet at 25°C in the animal house of Afzalipour Medical School. There were 7 rats in each group, and they were randomly put into 5 groups. This study was done in Kerman University of Medical Sciences under the permission of the Research Ethics Committee (license number: kmu.REC.1394.314.)

1-Sham group (sh): the animals of this group received no operation and they were normal.

2-Acetaminophen group (A): the animals of this group were kept without food for 16 hours, and then they received a single dose of 500 mg / kg acetaminophen via IPinjection (18).

3. Vehicle group (V): rats that received a single dose of 500 mg/kg acetaminophen. After 2 hours, they received 0.5 ml of mumijo vehicle (distilled water), equal to the volume of drugs, via IPinjection.

4. Low-dosemumijo group (L): after creating the liver damage, the rats were treated with a dose of 150 mg/kg of mumijo via IPinjection.

5 High-dosemumijo group (H): 2 hours after receiving acetaminophen, the rats were treated with a dose of 250 mg/kg of mumijo via IPinjection.

#### Liver damage by acetaminophen:

The animals were kept without food for 16 hours before the damage (18). Water was freely available to them. For creating liver damage, a single dose 500 mg/kg was injected intra peritoneally (18). Two hours after the administration of acetaminophen, 150 mg/kg and 250 mg/kg of mumijowere given to the test animals via IPinjection. 24 hours after administration of acetaminophen, they were killed after anesthesia with ether (18), and their blood samples were collected through the carotid artery. To separate serum, the blood samples were centrifuged for ten minutes at 3000 rpm, and the separated serum was kept in a temperature of -70 °C (18).

#### Histopathology of Liver

After the laparotomy, a part of the liver was removed and placed in 10% formalin and then embedded in paraffin. It was

stained usinghematoxylin-eosin, and the tissue condition was examined. Tissue sections were examined in terms of morphological changes including peri-portal necrosis, intra lobular destruction, portal inflammation, and infiltration of lymphocytes and Kupffer cells (18).

#### Biochemical analysis

Kits manufactured by Pars Azmoon (Iran) company and kits of Zell bio (Germany) were used to measure the amount of hepatic transaminase (ALT, AST, GGT) in the serum and for evaluating the antioxidant agents (GPX, PC) of serum and liver tissue, respectively. MDA was determined using the method of Rao et al , in which MDA is evaluated by thiobarbituric acid (TBA). Samples of light absorbance were read at 534 nm wavelength by spectrophotometer, and MDA concentration ( $\mu\text{mol}/\text{mg}$  protein) was reported (19).

*Nitric oxide (NO)* determination was done by Griess reaction for nitrite plus nitrate quantification using a two-step procedure. First, the nitrate in the samples was reduced to nitrite in a conversion buffer containing glucose-6-phosphate (2.5 mM), glucose-phosphate dehydrogenase (final concentration 400 U/l), and NADPH-dependent nitrate reductase (final concentration 200 U/l) in 14 mM sodium phosphate buffer, pH 7.4, and a solution of NADPH (0.02 mM). After incubation, the proteins were precipitated with 3.5 M ZnSO<sub>4</sub> solution and the supernatants were treated with Griess reactive (equal parts of 0.1 g N-(1-naphthyl)-ethylenediamine dihydrochloride in 100 ml water and 1 g sulfanilamide in 100 ml orthophosphoric acid 5%. The samples absorbance was read at 540 nm. The nitrite

concentration was calculated from a nitrite-standard curve and expressed as nM/mg protein (20)

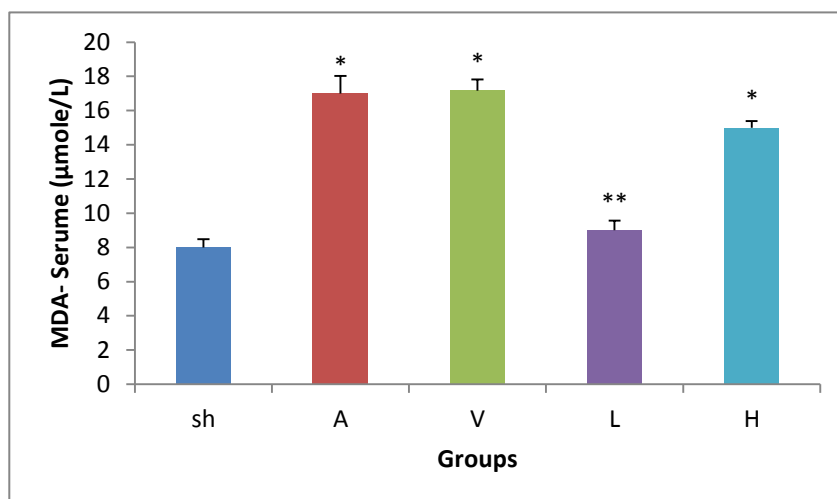
### Statistical analysis

Values are expressed as mean $\pm$ S.E.M. one-way analysis of variance (ANOVA) followed by the Tukey's test for post hoc comparisons were used for the statistical evaluation.  $P < 0.05$  was considered to be statistically significant.

## Results

### Effect of Mumijo on oxidant indices

Changes in serum and liver tissue MDA are shown in Figs 1-A and 1-B. As shown in Figure 1-A, MDA levels of sham group is  $8 \pm 0.49 \mu\text{mol/L}$ , which has increases significantly with use of acetaminophen ( $17 \pm 1.03 \text{nmol/mgprotein}$ ,  $P \leq 0.05$ ). Although there was no significant difference between the vehicle and acetaminophen group, in the low- and high-dose mumijo groups, the index showed a significant decrease compared with the vehicle and acetaminophen groups ( $P \leq 0.01$ ,  $P \leq 0.05$  respectively).



**Figure1-A.** The mean serum malondialdehyde in the different groups

\* Significant difference of the acetaminophen, vehicle and high-dose mumijo groups with the sham group  $p < 0.05$  24 hours after administration of acetaminophen. \*\* The difference of the low-dose group with acetaminophen and vehicle groups  $p < 0.01$ . Values are shown as Mean  $\pm$  SEM). Sh: sham, A: acetaminophen, V: vehicle, L: low-dose, H: high-dose.

Changes in liver tissue MDA are displayed in Fig B-1. As shown in this Fig, the value of this index in the sham group is  $0.98 \pm 0.4 \text{nmol/mgprotein}$ , which significantly increased after the consumption of acetaminophen ( $5.09 \pm 0.97 \text{nmol/mg protein}$   $P \leq 0.05$ ). Although there was no significant difference

between the vehicle and acetaminophen group, in the groups treated with mumijo, the index showed a significant decrease compared with the vehicle and acetaminophen groups ( $P \leq 0.05$ ).

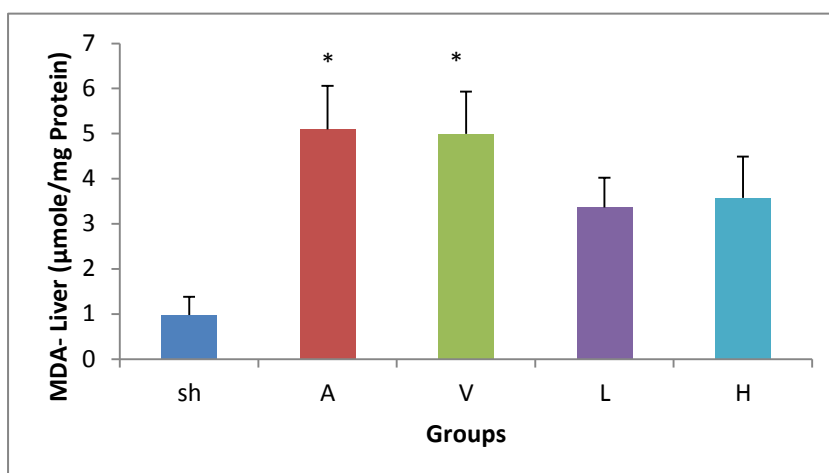


Figure 1-B. The mean liver malondialdehyde in different groups

\*Significant difference of acetaminophen and vehicle groups with low- and high-dose mumijo groups  $p < 0.05$ . Values are shown as Mean  $\pm$  SEM. Sh: sham, A: acetaminophen, V: vehicle, L: low-dose, H: high dose.

### Mumijo impact on antioxidant indices

#### A-Glutathione

In Figure 2, the effect of different doses of mumijo on the level of liver glutathione is shown. As you can see, this index in the sham group is  $27.22 \pm 1.5$  nmol/mg protein, decreased by acetaminophen  $2.7 \pm 0.57$  nmol / mg protein ( $p < 0.01$ ). As

with other antioxidant indices, this index does not affected by the use of vehicles. Similar to the vehicle group, high dose of mumijo did not block the reductive impact of acetaminophen. However, mumijo low dose showed significant increase  $p < 0.05$  in comparison with vehicle and acetaminophen group.

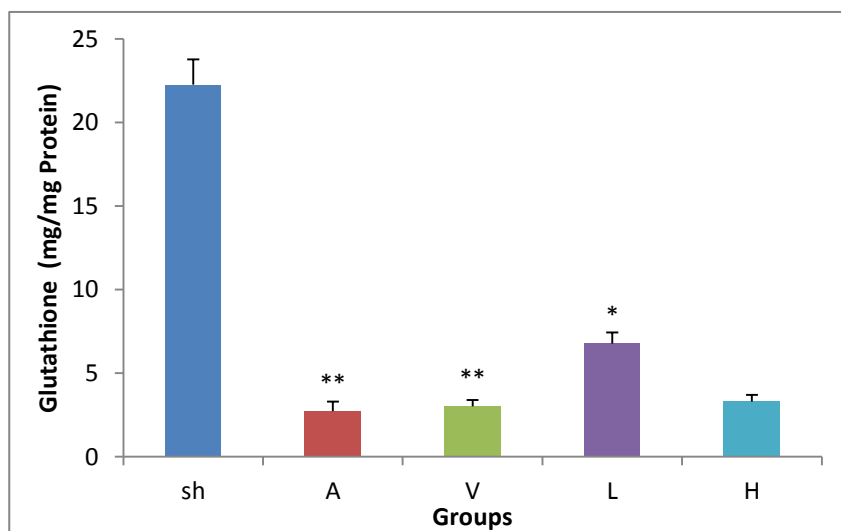


Figure 2. The mean liver glutathione in the different groups

\*  $P < 0.05$  Significant difference of low-dose group with acetaminophen and vehicle groups 24 h after administration of acetaminophen. Values are shown as Mean  $\pm$  SEM).

\*\*  $P < 0.01$  significant difference of acetaminophen and vehicle groups with the sham group. Sh: sham, A, acetaminophen, V: vehicle, L: low-dose, H: high-dose.

### B-NO metabolites

In Figure 3, changes in the level of liver NO are shown. NO in the sham group is  $1.3 \pm 0.25$  nmol/mg protein, and increased to  $16.8 \pm 3.1$  nmol/mg protein after consuming acetaminophen ( $P \leq 0.01$ ). There was no significant difference between the acetaminophen and vehicle groups; both doses of mumijo decrease NO. This decrease was  $1.48 \pm 0.16$  nmol/mg

protein and  $1.55 \pm 0.28$  nmol/mg protein respectively for low and high doses of mumijo, which shows a significant difference with acetaminophen and vehicle groups ( $P \leq 0.01$ ). Furthermore, there was no significant difference between the treatment and sham groups.

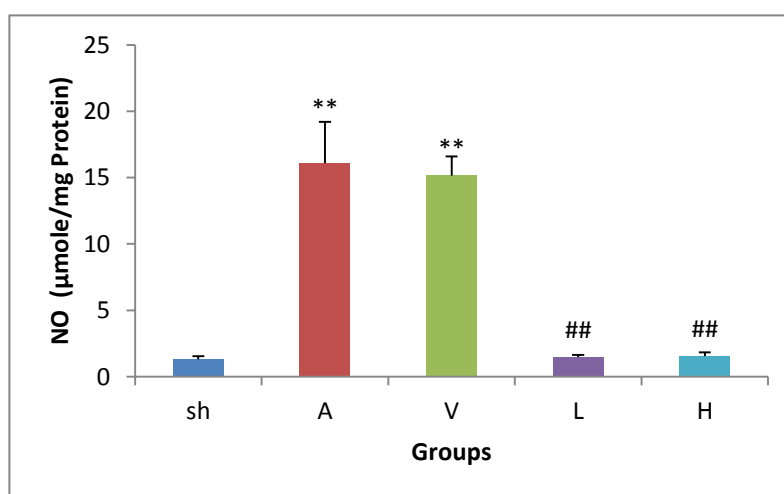


Figure 3. The mean liver NO in the different groups

\*\*  $P \leq 0.01$  Significant difference of acetaminophen and vehicle groups with the sham group. ##  $p \leq 0.01$  significant difference of low- and high-dose mumijo groups with the acetaminophen and vehicle groups 24 h after administration of acetaminophen. Values are shown as Mean  $\pm$  SEM). Sh: sham, A: acetaminophen, V: vehicle, L: low-dose, H: high-dose.

### C- carbonil protein

In Figure 4, changes in the carbonil protein (PC) level are shown in various groups. Consumption of acetaminophen increased PC level to  $22 \pm 8$  nmol/mg protein compared with the sham group  $4 \pm 0.63$  nmol/mg protein ( $P \leq 0.05$ ). Vehicle consumption cannot change the increase induced by

acetaminophen. This index in the groups treated with low and high doses was respectively  $8 \pm 2$  nmol/mg protein and  $11 \pm 3$  nmol/mg protein, which is significantly less than it is in the acetaminophen and vehicle groups ( $P \leq 0.01$ ,  $P \leq 0.05$ ).

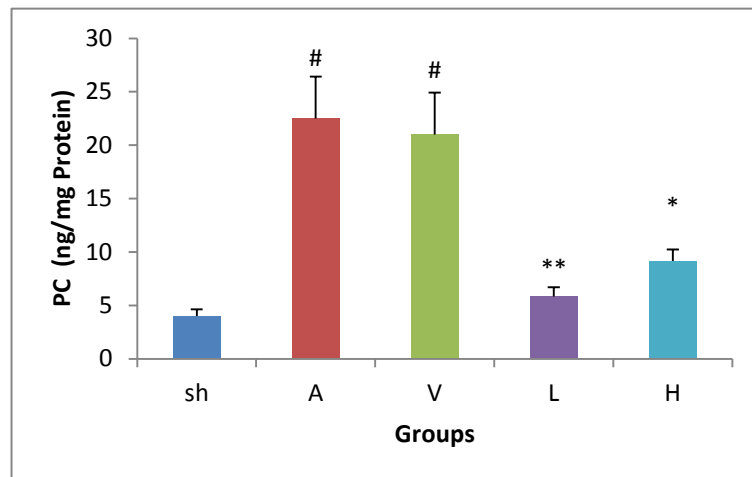


Figure 4. The mean liver PC in the different groups

\*  $P < 0.05$  significant difference of high-dose group sand acetaminophen and vehicle groups. #  $P < 0.05$  significant difference of acetaminophen and vehicle groups with sham group. \*\* $P < 0.01$  significant difference of low-dose group with acetaminophen and vehicle groups 24 h after the administration of acetaminophen. Values are shown as Mean  $\pm$  SEM). Sh: sham, A: acetaminophen, V: vehicle, L: low-dose, H: high-dose.

Mumijo impact on liver enzymes

AST

Figure 5-A shows AST enzyme activity in liver in different groups. Accordingly, after taking acetaminophen, the activity of this enzyme increases to  $505.33 \pm 10.94$  IU/L, which is more than the sham group ( $178.57 \pm 10.12$  IU/L,  $P < 0.01$ ). Using

vehicle did not reduce this increase caused by consumption of acetaminophen. Low and high doses of mumijo significantly decreased AST  $290.63 \pm 11.34$  IU/L and  $491.87 \pm 7.06$  IU/L respectively as compared with the acetaminophen group and the vehicle group ( $P < 0.01$  and  $P < 0.05$ ).

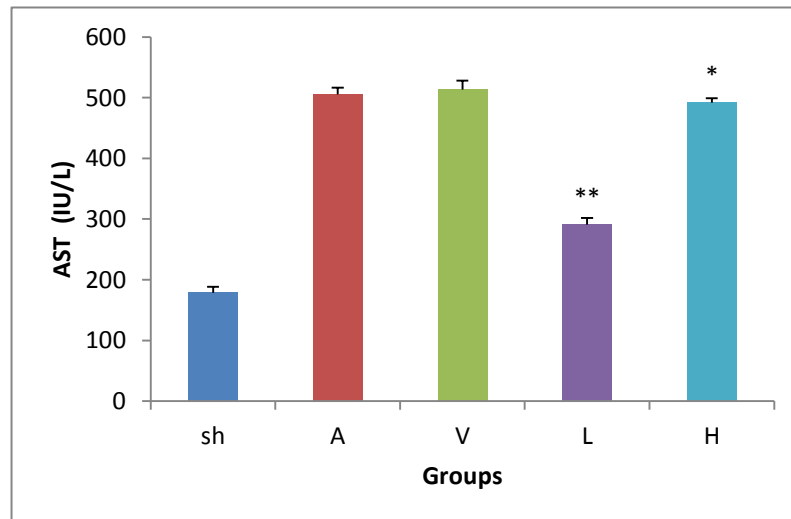


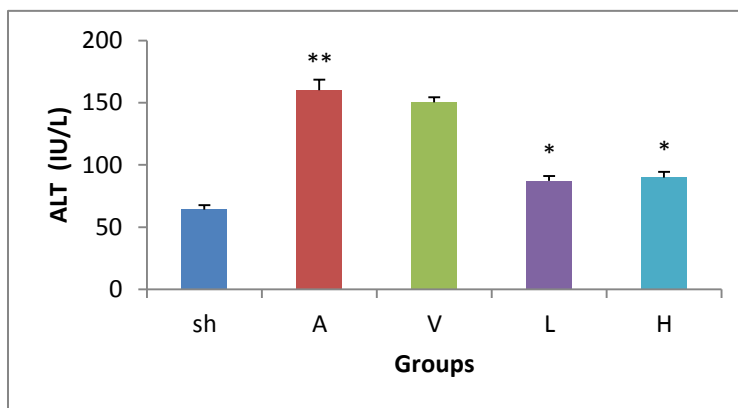
Figure 5-A. The mean serum AST activity in the different groups

\* Significant difference between the high-dose group sand acetaminophen and vehicle groups ( $p < 0.05$ ), \*\* Significant difference between the low-dose group and the acetaminophen and vehicle groups ( $p < 0.01$ ) 24 h after the administration of acetaminophen. Values are shown as Mean  $\pm$  SEM. Sh: sham, A: acetaminophen, V: vehicle, L: low-dose, H: high-dose.

**ALT enzyme**

Changes in ALT enzyme are shown in Fig. 5-B. Similar to AST enzyme, the activity of this enzyme reached from  $64 \pm 3.61$  IU/L in the sham group to  $160 \pm 8.55$  IU/L in the acetaminophen group after using acetaminophen ( $P \leq 0.01$ ).

Although this increase could not be blocked by using the vehicle, both doses of mumijo decreased it significantly compared with the vehicle and acetaminophen groups ( $P \leq 0.05$ ).



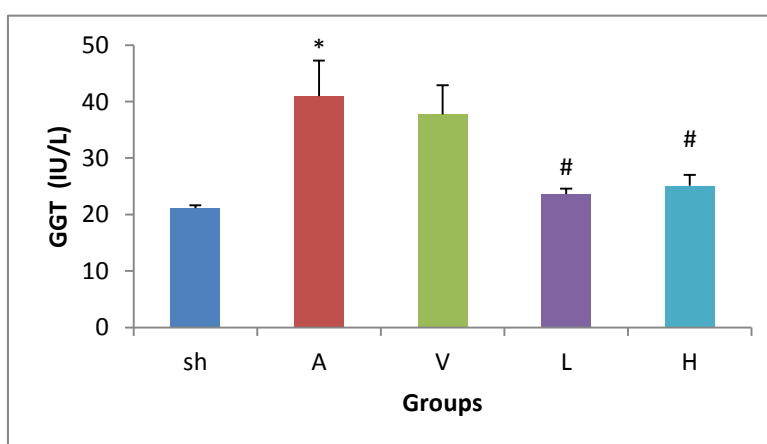
**Figure 5-B.** The mean serum ALT activity in the different groups

\* Significant difference of high- and low-dose groups with acetaminophen and vehicle groups ( $p \leq 0.05$ ) 24 h after the administration of acetaminophen. \*\* ( $p \leq 0.01$ ) significant difference between acetaminophen and sham groups. Values are shown as Mean  $\pm$  SEM. Sh: sham, A: acetaminophen, V: vehicle, L: low-dose, H: high-dose.

**C-GGT enzyme**

Figure 5-C shows GGT enzyme activity in liver in different groups. The activity of this enzyme in the sham group is  $21.1 \pm 0.52$  IU/L, which significantly increased to  $40.97 \pm 6.26$  IU/L after taking acetaminophen ( $P \leq 0.01$ ). Although using

the vehicle did not inhibit the increase caused by the consumption of acetaminophen, the use of low and high doses of mumijo significantly decreased GGT compared with acetaminophen and vehicle groups ( $P \leq 0.05$ ). There was no significant difference with the sham group.



**Figure 5-C.** The mean serum GGT activity in the different groups

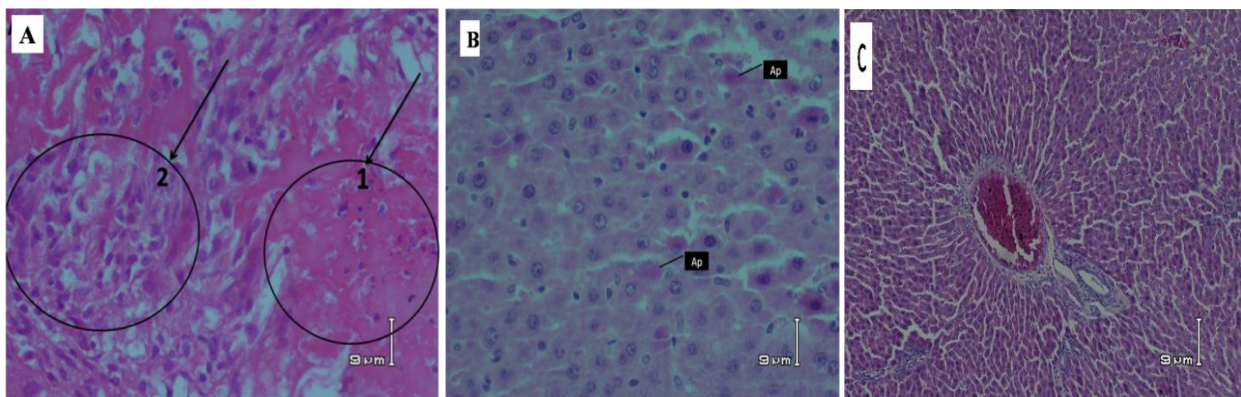
# Significant difference of high and low doses of mumijo with acetaminophen and vehicle groups ( $p \leq 0.01$ ) 24 h after the administration of acetaminophen. \* $P < 0.01$  Significant difference between acetaminophen and sham groups. Values are shown as Mean  $\pm$  SEM. Sh: sham, A: acetaminophen, V: vehicle, L: low-dose, H: high-dose.



**Liver histopathology**

Liver histopathology observations indicate that hepatocytes in the sham group had normal nuclei and cytoplasm. There were no signs of necrosis, inflammation and accumulation of immune cells in the liver (Figure 6-C). However, extensive necrosis and accumulation of immune

cells could be observed in the acetaminophen group (Fig. 6-A). Necrosis was reduced in the low dose group, and only a few scattered instances of apoptosis were observed. Furthermore, accumulation of inflammatory cells was not observed in this group (Fig. 6-B).



**Figure 6** liver sample 24 hours after administration of 500 mg/kg of acetaminophen in the low dose group: no necrosis and accumulation of immune cells was observed, and apoptosis was seen only sporadically. A: liver tissue sample from the acetaminophen group, 1- severe necrosis, 2- accumulation of immune cells (macrophages and lymphocytes). B: sample of the liver from the low-dose group - AP: scattered apoptosis C: the liver sample from the sham group

**Discussion**

In this study, for the first time, the effect of mumijo on acetaminophen-induced liver damage and some of its possible mechanisms in rats were studied.

The results of the study showed that consuming a certain amount of mumijo reduced acute liver damage caused by acetaminophen. It also reduced the increase in liver enzymes AST, ALT, and GGT caused by high doses of acetaminophen. In addition, mumijo use reduced hepatocyte apoptosis and necrosis, and it also prevented the infiltration of inflammatory cells in the liver. Since acetaminophen increases oxidant factors (MDA, NO, PC) and reduces glutathione in liver tissue, and consumption of mumijo decreases oxidant factors and increases glutathione, it can be suggested that mumijo's mechanism for protecting the liver is a result of its antioxidant

properties. Therefore, oral consumption of mumijo can be used as an effective treatment for reducing the acute effects of hepatic toxicity caused by large doses of acetaminophen.

Liver cells are subject to damage as a result of the effects of various poisons, toxins, and infections with metabolic origin (21).

In addition, cholestasis leads to damage and death of liver cells, fibrosis, cirrhosis, and eventually liver failure (3). The connection of cytochrome C to cytoplasmic scaffold apaf-1 and pro-caspase9 and the formation of complex "apoptosome", which activates pro-caspase9 signaling (22), the severe decrease of adenosine triphosphate in cells, glutathione depletion, damage to cytochrome P450, and loss of NAD and NADP are all among the causes of liver damage (23). Various types of nitrogen and oxygen (ROS/NOS) are often involved

in liver toxicity. By increasing the production of ROS and NOS, inducing nitric oxide synthase enzyme, increasing intracellular  $Ca^{2+}$  and provoking phagocytic activity, toxic agents can cause liver damage. It has been proved that Galactoseamin that initiates the activity of free radicals also plays a role in liver toxicity (24).

Acetaminophen overdose is one of the major causes of liver damage (2). It is known that the mechanism of liver injury caused by acetaminophen is not due to acetaminophen itself, but is because of its toxic metabolite i.e. N-Acetyl-p-benzoquinoneimine, which is created through the cytochrome P450 system (2). Naturally, glutathione reserves in liver prevent liver cell damage via connection to toxic metabolites (1, 4, 5). The results of this study showed the reductive effect of acetaminophen on the level of liver glutathione. Liver toxicity is caused when glutathione reserves become less than 30% (3). Lipid peroxidation is also effective in liver damage and cell death due to free radicals (21). In this study, MDA, which is a marker of lipid peroxidation, increased due to acetaminophen increase. One of the risks of acetaminophen toxicity is hepatic necrosis. With the significant increase in levels of serum ALT, AST enzymes, and lactate dehydrogenase, hepatic necrosis rises to 500 times above normal (6, 7). These results are consistent with the results of this study. These enzymes increase following the use of acetaminophen. Therefore, in this study, toxicity caused by this dose of acetaminophen emerged in the form of hepatic necrosis, apoptosis, and increase in the above-mentioned enzymes. Increased lipid peroxidation and reduced glutathione were introduced as the mechanism of action of acetaminophen.

It is reported that some anti-hepatotoxic agents can play a protective role in liver by preventing activation of the enzyme system associated with cytochrome P-450 (25-26), supplying glutathione or its precursors, creating an antioxidant effect, and eliminating free radicals (26).

In this study, it was shown that mumijo treatment can block the increase of MDA, NO, ALT, AST, PC, and GGT caused by acetaminophen. It also prevents the decrease of glutathione caused by taking too much acetaminophen. Therefore, mumijo has anti-oxidant and anti-inflammatory impacts that can prevent lipid peroxidation, accumulation of free radicals, and oxidant and inflammatory agents in liver tissue.

In line with the findings of this study, numerous studies have shown that mumijo can inhibit lipid peroxidation and increase glutathione content in hepatotoxicity induced by cumenehydroperoxide (16). Mumijo probably increases the potential for liver detoxification by increasing the activity of glutathione transferase, which raises the level of hepatic glutathione via disabling NAPQI toxic metabolites (2). Mumijo also prevents lipid peroxidation induced by cumenehydroperoxide and ADP/Fe<sup>2+</sup> Complex in rat liver, which is another mechanism for liver protection (16, 27). In addition, numerous reports have shown that mumijo has anti-inflammatory (11) and antioxidant (14) impacts. In the striatum and frontal cortex in rats, this substance can increase activity of superoxide dismutase (SOD), catalase (CAT), and glutathione peroxidase (GPX) (14). In agreement with this study, several other reports on the damage to other organs, including Khaksari et al., who showed that this substance reduces the antioxidant agents in brain trauma indicate mumijo's anti-oxidant impact (17). Jouka et al. reported that

mumijo decreased lipid peroxidation and increased antioxidant capacity in damage to experimental myocarditis (15). Such antioxidant effects of mumijo extract may be mainly because of dibenzo-pyrone and Folic acid in its constituents (28).

Evidence has shown that hepatocyte apoptosis plays a major role in inducing liver damage caused by acetaminophen (29).

Apoptosis inhibition can prevent acute liver damage (30). Accordingly, in another part of this study, the investigation of histopathology showed that acetaminophen use may cause hepatocyte apoptosis, and treatment of liver with mumijo could significantly decrease cell apoptosis in liver. Furthermore, mumijo inhibited the increase in AST, ALT, PC, and GGT induced by acetaminophen. This could be another potential mechanism for mumijo's detoxification action (30).

Previous studies also have reported anti-inflammatory effects for mumijo (11), and it has been shown that in response to hepatic damage, a series of toxic mediators such as tumor necrosis factor-alpha (TNF- $\alpha$ ), interleukin 1 (IL-1), and nitric oxide are released from macrophages (25). In this study, we have shown that NO levels that significantly increased after taking acetaminophen had a significant decrease as a result of using mumijo.

Other studies conducted on a variety of other inflammations correspond to the findings of this study. For

example, it was reported that mumijo reduced carrageenan-induced inflammation in rats (11). It was also reported that administration of mumijo in Syrian rats reduced inflammation and pain in the first phase of the formalin test and also in the writhing tests (13).

Histopathological analyses of the present study showed decrease in the accumulation of inflammatory cells (macrophages and neutrophils) in liver after using mumijo. Since some studies have shown that macrophages are disabled by dextran sulfate and Gadolinium, and this reduced the hepatic toxicity of acetaminophen (31,32), reducing the accumulation of inflammatory cells may be another detoxification mechanism of mumijo in hepatic toxicity induced by acetaminophen.

Observations of the present study show that consumption of mumijo has a protective role in acetaminophen-induced hepatic toxicity.

Given the multiple mechanisms of mumijo referred to in the present study, it can be expected that mumijo disables toxic metabolite of acetaminophen (NAPQI) and increases the potential for liver detoxification through its antioxidant, anti-inflammatory, and anti-apoptotic effects, and by improving liver function. Thus, mumijo has a protective role in acute hepatic damage caused by acetaminophen. There is a need for further investigation on Mumijo's other possible mechanisms and protective effects on hepatic damage.

## References

1. Hinson JA, Roberts DW, James LP. Mechanisms of acetaminophen-induced liver necrosis. *Handb Exp Pharmacol* 2010; (196):369-405
2. Dong H, Haining RL, Thummel KE, Rettie AE, Nelson SD. Involvement of human cytochrome P450 2D6 in the bioactivation of acetaminophen. *Drug Metab Dispos* 2000;28 (12):1397-400.
3. Potter WZ, Thorgeirsson SS, Jollow DJ, Mitchell JR. Acetaminophen-induced hepatic necrosis. V. Correlation of hepatic necrosis, covalent binding and glutathione depletion in hamsters. *Pharmacology* 1974;12 (3):129-43.
4. McGill MR, Sharpe MR, Williams CD, Taha M, Curry SC, Jaeschke H. The mechanism underlying acetaminophen-induced hepatotoxicity in humans and mice involves mitochondrial damage and nuclear DNA fragmentation. *J Clin Invest* 2012;122 (4):1574-83.
5. Jiang J, Briede JJ, Jennen DG, Van Summeren A, Saritas-Brauers K, Schaart G, et al. Increased mitochondrial ROS formation by acetaminophen in human hepatic cells is associated with gene expression changes suggesting disruption of the mitochondrial electron transport chain. *ToxicolLett* 2015;234 (2):139-50.
6. Dirksen K, Burgener IA, Rothuizen J, van den Ingh T, Penning LC, Spee B, et al. Sensitivity and specificity of plasma ALT, ALP, and Bile Acids for hepatitis in Labrador retrievers. *J Vet Intern Med* 2017;31 (4):1017-27.
7. Sheen CL, Dillon JF, Bateman DN, Simpson KJ, Macdonald TM. Paracetamol toxicity: epidemiology, prevention and costs to the health-care system. *QJM* 2002;95 (9):609-19.
8. Grace E, Herbert M, Essien G, Nsikan U, Akpan H, Ubana E, et al. The protective effect of combined leaf extracts of gongronema latifolium and nauclea latifolia on acetaminophen-induced liver toxicity in rats. *British Journal of Applied Science & Technology* 2014;4 (15):21-52.
9. Golestan Jahromi M, Nabavizadeh F, Vahedian J, Nahrevanian H, Dehpour AR, Zare-Mehrjardi A. Protective effect of ghrelin on acetaminophen-induced liver injury in rat. *Peptides* 2010;31 (11):2114-7.
10. Agarwal SP, Khanna R, Karmarkar R, Anwer MK, Khar RK. Shilajit: a review. *Phytother Res* 2007;21 (5):401-5.
11. Goel RK, Banerjee RS, Acharya SB. Antiulcerogenic and antiinflammatory studies with shilajit. *J Ethnopharmacol* 1990;29 (1):95-103.
12. Stohs SJ. Safety and efficacy of shilajit (mumie, moomiyo). *Phytother Res* 2014;28 (4):475-9.
13. Malekzadeh G, Dashti-Rahmatabadi MH, Zanbagh S, Akhavi Mirab-bashii A. Mumijo attenuates chemically induced inflammatory pain in mice. *Altern Ther Health Med* 2015;21 (2):42-7.
14. Bhattacharya SK, Sen AP, Ghosal S. Effects of shilajit on biogenic free radicals. *Phytotherapy Research* 1995;9 (1):56-9.
15. Joukar S, Najafipour H, Dabiri S, Sheibani M, Sharokhi N. Cardioprotective effect of mumie (shilajit) on experimentally induced myocardial injury. *Cardiovasc Toxicol* 2014;14 (3):214-21.
16. Ghosal S. Free radicals, oxidative stress and antioxidant defense. *Phytomedica* 2000;21 (1/2):1-8.
17. Khaksari M, Mahmmodi R, Shahrokhi N, Shabani M, Joukar S, Aqapour M. The effects of shilajit on brain edema, intracranial pressure and neurologic

- outcomes following the traumatic brain injury in rat. *Iran J Basic Med Sci* 2013;16 (7):858-64.
18. Lin CC, Hsu YF, Lin TC, Hsu HY. Antioxidant and hepatoprotective effects of punicalagin and punicalin on acetaminophen-induced liver damage in rats. *Phytother Res* 2001;15 (3):206-12.
  19. Kesavulu MM, Giri R, KameswaraRao B, Apparao C. Lipid peroxidation and antioxidant enzyme levels in type 2 diabetics with microvascular complications. *Diabetes Metab* 2000;26 (5):387-92.
  20. Titheradge MA. The Enzymatic Measurement of Nitrate and Nitrite. In: Titheradge MA, editor. Nitric Oxide Protocols. Totowa, NJ: Humana Press; 1998;P 83-91.
  21. Lee BM, Kacew S. Lu's Basic Toxicology: Fundamentals, Target Organs, and Risk Assessment. 6th ed. London (UK): Taylor & Francis; 2012.
  22. Slee EA, Adrain C, Martin SJ. Executioner caspase-3, -6, and -7 perform distinct, non-redundant roles during the demolition phase of apoptosis. *J Biol Chem* 2001;276 (10):7320-6.
  23. Grattagliano I, Bonfrate L, Diogo CV, Wang HH, Wang DQ, Portincasa P. Biochemical mechanisms in drug-induced liver injury: certainties and doubts. *World J Gastroenterol* 2009;15 (39):4865-76.
  24. Myagmar BE, Shinno E, Ichiba T, Aniya Y. Antioxidant activity of medicinal herb *Rhodococcum vitis-idaea* on galactosamine-induced liver injury in rats. *Phytomedicine* 2004;11 (5):416-23.
  25. Bourdi M, Masubuchi Y, Reilly TP, Amouzadeh HR, Martin JL, George JW, et al. Protection against acetaminophen-induced liver injury and lethality by interleukin 10: role of inducible nitric oxide synthase. *Hepatology* 2002;35 (2):289-98.
  26. Testa B, Perrissoud D. Liver Drugs: From Experimental Pharmacology to Therapeutic Application: CRC PressI Llc; Boca Raton. pp 113-143
  27. Tripathi YB, Shukla S, Chaurasia S, Chaturvedi S. Antilipid peroxidative property of shilajit. *Phytotherapy Research* 1996;10 (3): 269-73.
  28. Schepetkin I, Khlebnikov A, Kwon BS. Medical drugs from humus matter: Focus on mumie. *Drug Development Research* 2002;57 (3):140-59.
  29. Kass GE, Macanas-Pirard P, Lee PC, Hinton RH. The role of apoptosis in acetaminophen-induced injury. *Annals of the New York Academy of Sciences*. 2003;1010 (1):557-9.
  30. Hu J, Yan D, Gao J, Xu C, Yuan Y, Zhu R, et al. rhIL-1Ra reduces hepatocellular apoptosis in mice with acetaminophen-induced acute liver failure. *Lab Invest* 2010;90 (12):1737-46.
  31. Goldin RD, Ratnayaka ID, Breach CS, Brown IN, Wickramasinghe SN. Role of macrophages in acetaminophen (paracetamol)-induced hepatotoxicity. *J Pathol* 1996;179 (4):432-5.
  32. Laskin DL, Gardner CR, Price VF, Jollow DJ. Modulation of macrophage functioning abrogates the acute hepatotoxicity of acetaminophen. *Hepatology* 1995;21 (4):1045-50.