

The Effects of Opium Administration on Histology of Testes and Spermatogenesis Indexes in Adult Male Rats

Fateme Hasani, M.Sc.¹, Zohreh Safi, M.Sc.², Behzad Razavi, M.D.², Kouros Divsalar, M.Sc.³, Arezoo Saberi, M.Sc.⁴

1- Physiology Research Center, Institute of Basic and Clinical Physiology Sciences, Kerman University of Medical Sciences, Kerman, Iran

2- Cardiovascular Research Center, Institute of Basic and Clinical Physiology Sciences, Kerman University of Medical Sciences, Kerman, Iran

3- Neuroscience Research Center, Institute of Neuropharmacology, Kerman University of Medical Sciences, Kerman, Iran

4- Neuroscience Research Center, Institute of Neuropharmacology, Kerman University of Medical Sciences, Kerman, Iran (Corresponding author; E-mail: arezoo_saberi222@yahoo.com)

Received: 24 November, 2019

Accepted: 23 May, 2020

ARTICLE INFO

Article type:

Original Article

Keywords:

Opium

Spermatogenesis Indexes

Testis Histology

Abstract

Background: Opium, as the most widely known opioid in the world, has significant effects on reproductive organs, which can affect fertility and influence the next generation. This study was performed to investigate the effects of opium administration on histological changes and spermatogenesis indexes in the testis of adult male rats.

Methods: A total of 50 adult male Wistar rats were used. Animals were divided into 5 groups (n=10). Control (intact), Vehicle (received saline for 7 and 14 days) and Opium (received 2 mg/kg opium i.p. For 7 and 14 days) groups. Sample of testes were stained by H&E, then the number of spermatogonia, spermatocytes and Leydig cells were counted and spermatogenesis indexes which included tubular differentiation index (TDI), spermatogenesis index (SI), repopulation index (RI) and means of seminiferous tubules diameter (MSTD) were determined.

Results: In opium groups, the number of seminiferous tubules cells and spermatogenesis decreased compared with the control group ($P<0.001$). Moreover, the results showed that TDI, SI, RI and STD parameters significantly decreased in 7th and 14th days, compared with the control group ($P<0.001$).

Conclusion: The data showed the adverse effects of opium administration (for 7 and 14 days) on spermatogenesis and its indexes in rat testis tissue. The underlying mechanisms need further investigation.

Introduction

Opium is the dried latex obtained from the unripe seed capsules of the poppy plant, *Papaver somniferum*, which contains up to 40 alkaloids, including morphine (8-17 %), codeine (0.7-5 %), thebaine (0.1 -2.5 %), papaverine (0.5-1.5 %) and noscapine (1-10%) (1). Previous studies showed that Iran has the highest rate of opium (2.8% of Iranians over age 15) addiction in the world (2). The precise estimate of the number

of substance users in Iran is not possible, however, using indirect estimations, the total number is estimated to be more than two millions (3). Moreover, despite the increased use of a wide range of new synthetic and psychoactive drugs, the use of opioids, continues to be a major drug problem globally and it is reported that over the last decades, the rate of opioid misuse among teenagers is increased (4). The United Nations office on drugs and crime reported that about 16.5 million people, 0.4%

of the world's adult population, aged 15 or older use opiates such as heroin and opium (5).

Opiate use is more prevalent in males and people who are younger than 30 years of age (6). A recent study conducted in Kerman province in southeast Iran, has shown that 11.5% of the male individuals abuse opiates (7). Menati et al reported that 6.0% of high school and university male students under age of 20 were using opium (2). Short term use of opium may result in periods of sleep or insomnia and long term opioid use could be associated with serious adverse effects and physical dependence (8). There are many reports showing that, opium and its derivatives have exerted important physiologic effects on multiple organ systems including brain (9), cardiovascular (10,11), pulmonary (12), renal (13), liver (14) and reproductive organs (15-17). Opioids can interfere with hypothalamic-pituitary-gonadal axis (HPG axis) activity inhibiting the secretion of GnRH and suppression of luteinizing hormone (LH), follicle-stimulating hormone (FSH) release and the subsequent reduction in testosterone levels and abnormal spermatogenesis in long-term opioid abusers (18-20).

Opioids may regulate some of the processes involved in reproductive function including sperm motility (21). Moreover, opium consumption is associated with significant decrease in sperm DNA integrity, sperm concentration and sperm quality (20). These structural and functional changes can be caused by two possible synergistic mechanisms of action, oxidative stress and apoptosis. Oxidative stress which is caused by elevation of lipid peroxide production, damages cellular macromolecules including lipids, proteins, and DNA. It changes gene expression and pushes the cells toward apoptosis (19,22).

Most previous studies reported the effects of specific opioids on reproductive function and since opium comprises several alkaloids, this study was designed to investigate the effects of opium administration on histological and spermatogenesis indexes of testes in adult male rats.

Materials and Methods

All animal experimental procedures and protocols of the study were approved by the Ethics Committee for Animal Experiments of Kerman University of Medical Sciences. A total of 50 adult male Wistar rats, weighing 250–270 g, were provided by the Kerman Neuroscience Research Center. Drinking water and commercial animal feed were available in standard pellet form. The animal room was maintained at approximately 22 °C and 50% relative humidity with a 12 h light/dark cycle.

After the acclimatization period, the animals were randomly divided into 5 groups (n = 10), group I control (intact), groups II and III vehicle (received saline for 7 or 14 days) and groups IV and V opium (received dose of 2 ml/kg for 7 or 14 days). All groups of animals received treatment by intraperitoneal injection. Opium was dedicated by Counter Narcotics Headquarters in Kerman Province (Iran). Based on their information, the origin of opium was Helmand in Afghanistan. It was dissolved in fresh saline (1 mg opium per 1 ml normal saline) by Heat Shaker.

Histological studies

The left testes of rats were rapidly removed and fixed at room temperature in phosphate-buffered saline (PBS; 0.1 M Sodium phosphate, 0.14 M NaCl, pH 7.4) containing 3.7% paraformaldehyde for 30 minutes and then fixed in 10% neutral

buffered formalin for 48 h. Testes tissues were washed through graded concentrations of ethanol. Then, the samples were dehydrated, cleared and embedded in paraffin wax. Serial transverse sections were cut at 5 mm thicknesses by a rotary microtome, and stained with hematoxylin and eosin (H&E). The sections were examined using light microscope to investigate the spermatogenesis process. For histological study, the number of spermatogonia, primary and secondary spermatocytes and Leydig cells were counted and compared with control group. For spermatogenesis indexes, tubular differentiation index (TDI), spermatogenesis index (SI), repopulation index (RI) as a measure of the length of total colonies per testis and the mean seminiferous tubule diameter (MSTD) were examined.

For measuring TDI, SI and RI, 200 seminiferous tubule cross sections were scored. The TDI is the percentage of tubules containing three or more differentiated spermatogenic cells more advanced than primary spermatogonia (i.e., secondary spermatogonia, spermatocytes, or spermatids) and is a measure of survival and differentiation of the stem, type A spermatogonia. The RI is the ratio of active to inactive spermatogonia cells. For the SI, the ratio of seminiferous tubules containing sperm to the tubules without sperm was calculated and MSTD of each testis was measure by Image Tools 2 (23,24).

Statistical analysis

The data of the spermatogenesis indexes and the number of seminiferous tubules cells were presented as mean \pm SEM and

analyzed by one-way ANOVA coupled with *Dunnnett's* post hoc analysis to determine the significance of the results. The level of statistical significance was set at $P < 0.05$. All data were processed by SPSS software 20.

Results

Considering the examination of testicular tissue samples, the results showed normal seminiferous tubules in control group and spermatogonia, primary and secondary spermatocytes exhibited normal arrangement in different stages of spermatogenesis in vehicle groups. In opium groups, especially in those with 14 days of treatment, the structure of testes and seminiferous tubules cells underwent significant changes.

Opium treatment for either 7 or 14 days caused a significant decrease in spermatogonia cells and an increase in damaged spermatogonia cells (Figure 1).

Histological Changes

In opium groups, drug did not significantly decrease the testis weight compared with the control group. In histological examination, numerous structural changes were observed in the opium groups receiving opium especially in those with 14 days of treatment, compared with the control group. Spermatogonia and primary and secondary spermatocytes decreased significantly ($P < 0.001$), but opium had no significant effect on Leydig cells (Table 1).

Table 1. Effects of 7 and 14 days of subacute opium on testis weight and structure in male rats

| Groups | Testes Weight (gr) | P Value * | Spermatogonia (n) | P Value * | 1 st Spermatocytes (n) | P Value * | 2 nd Spermatocytes (n) | P Value * | Leydig cells (n) | P Value * |
|-------------------|--------------------|-----------|-------------------|-----------|-----------------------------------|-----------|-----------------------------------|-----------|------------------|-----------|
| Control | 1.62±0.03 | - | 67.10±0.64 | - | 66.00±0.94 | - | 66.40±0.73 | - | 11.39±0.26 | - |
| Vehicle (7 Days) | 1.56±0.05 | 0.96 | 64.50±0.60 | 0.89 | 61.60±0.99 | 0.12 | 65.10±0.92 | 0.82 | 10.56±0.39 | 0.88 |
| Vehicle (14 Days) | 1.46±0.03 | 0.84 | 65.70±0.96 | 0.63 | 64.60±0.93 | 0.81 | 63.70±1.24 | 0.19 | 10.97±0.37 | 0.76 |
| Opium (7 Days) | 1.59±0.05 | 0.78 | 56.60±0.79 | 0.001 | 57.60±0.69 | 0.001 | 57.90±0.67 | 0.001 | 10.42±0.43 | 0.81 |
| Opium (14 Days) | 1.53±0.03 | 0.78 | 50.60±0.45 | 0.001 | 51.00±1.01 | 0.001 | 50.00±0.58 | 0.001 | 10.33±0.48 | 0.73 |

Rats received opium (2 mg/kg) intraperitoneally for either 7 or 14 days.

Vehicle group received saline. Control rats received no treatment.

Data are the Mean ± SEM of 10 rats in each group. * compared with control group

Spermatogenesis Indexes

The results showed that, the spermatogenesis indexes have been affected by opium treatment, including a significant

decrease in TDI, SI and RI in experimental groups compared with the control group (p<0.001). The seminiferous tubular diameter decreased in those with 14 days of treatment by opium (Table 2) (Figure 1).

Table 2. Effects of 7 and 14 days of subacute opium on spermatogenesis indexes structure in male rats

| Groups | % TDI | P Value * | % SI | P Value * | % RI | P Value * | MSTD (µm) | P Value * |
|-------------------|------------|-----------|------------|-----------|------------|-----------|-------------|-----------|
| Control | 70.60±0.83 | - | 68.70±0.94 | - | 70.70±0.56 | - | 301.10±1.37 | - |
| Vehicle (7 Days) | 68.80±0.68 | 0.50 | 67.90±3.05 | 0.92 | 67.80±0.79 | 0.71 | 303.40±1.13 | 0.89 |
| Vehicle (14 Days) | 68.20±0.66 | 0.22 | 65.90±0.84 | 0.70 | 67.40±0.82 | 0.29 | 293.50±1.94 | 0.66 |
| Opium (7 Days) | 60.90±0.97 | 0.001 | 60.40±0.54 | 0.001 | 59.40±0.99 | 0.001 | 282.30±2.10 | 0.03 |
| Opium (14 Days) | 52.00±0.79 | 0.001 | 53.70±0.84 | 0.001 | 51.30±0.56 | 0.001 | 279.30±1.06 | 0.02 |

Rats received opium (2 mg/kg) intraperitoneally for either 7 or 14 days.

Vehicle group received saline. Control rats received no treatment.

Data are the Mean ± SEM of 10 rats in each group. * compared with control group

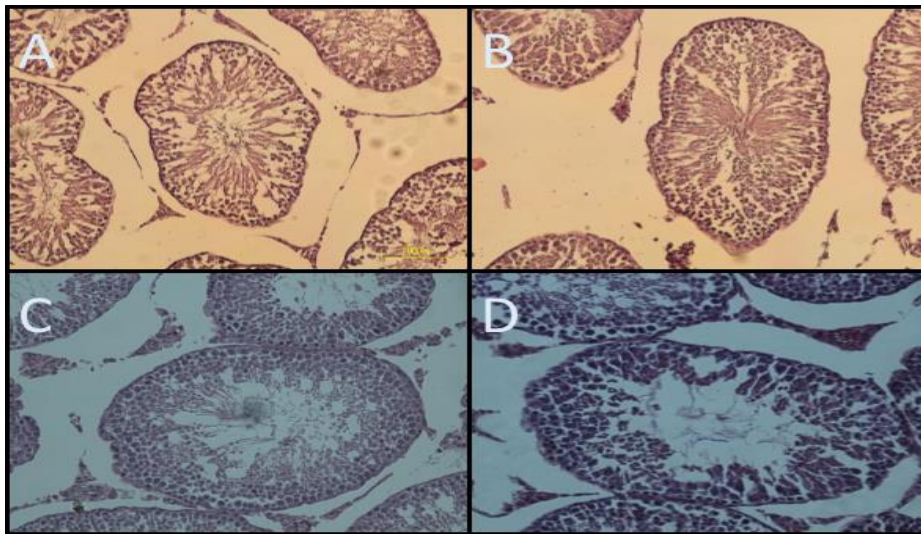


Figure 1. Optical microscopy of testis sections; Normal spermatogenesis is seen in the control group (A) and vehicle group (B); Nearly all lineage of spermatogonia cells are damaged and their number is decreased in opium groups either in 7 Days (C) or 14 Days (D) (H & E. $\times 400$).

Discussion

The results of this study showed that consecutive administration of opium for either 7 or 14 days caused significant histopathological changes in testis structure and spermatogenesis indexes in adult male rats. The structural abnormalities of testes were indicated with a significant decrease in the number of spermatocytes and primary and secondary spermatogonia and a significant decrease in spermatogenesis indexes including TDI, SI, RI and MSTD, which is in complete agreement with previous studies (15,16,,19,25,26).

Nematollahi-Mahani et al reported that opium dependence and cigarette smoking decrease semen volume and sperm quality in male partners of infertile couples (25). In agreement with our results, other researchers reported that tramadol administration is associated with a significant decrease in luteinizing hormone, follicle-stimulating hormone,

testosterone, total cholesterol and significant increase in prolactin and estradiol plasma levels, as well as oxidative stress and histological abnormalities on testicular tissues of adult male rats (15). Previous studies confirmed that opioids use is associated with a significant decrease in gonadotropins, testosterone and weights of testes, partial weights of prostate and seminal vesicle in adult male rats (16). A recent study indicated that naltrexone, an opioid growth factor (OGF) inhibitor, improved the microscopic indices of spermatogenesis such as tubular diameter and germinal epithelium height in diabetic mice (26).

Opium-induced testes structural abnormalities in our study is comparable with the results reported by Bhoir et al indicating degenerative changes in spermatogonial cells, primary spermatocytes, secondary spermatocytes and spermatids in heroin-treated male rats (27).

Mohammadzadeh et al reported impairment in preimplantation development as well as a significant decrease

in the rate of blastocyst formation and increase in apoptosis induction in survived embryos of Kerack-addicted Mice (28).

Moreover, opioids cause similar adverse effects on female reproductive system. Opioid abuse could be associated with hypogonadism, oligomenorrhea, amenorrhea and infertility in women (29,30). Eyvazzadeh et al indicated that Endogenous opioids play an important role in the GnRH secretion and carbohydrate metabolism in women with polycystic ovary syndrome (PCOS) (31).

The underlying mechanisms of opioid-induced adverse effects on reproductive functions including suppression of gonadotropins and testosterone and significant decrease in spermatogenesis indexes (TDI, SI, RI and MSTD) are not determined yet. However it could be mediated through several mechanisms including increased MDA level with decreased gene expression of the antioxidant enzymes, opioid-induced increased apoptosis, overproduction of nitric oxide and oxidative stress caused by elevation of lipid peroxidation products (15). In addition, opioid growth factor (OGF) may be involved in the growth and differentiation of the spermatocytes and related cells (26). Grachev et al reported that κ -Opioid Receptor may be involved in the suppression of the GnRH pulse generator in rats (32).

References

1. López P, Pereboom-de Fauw DP, Mulder PP, Spanjer M, de Stoppelaar J, Mol HG, et al. Straightforward analytical method to determine opium alkaloids in poppy seeds and bakery products. *Food Chem* 2018; 242:443-50.
2. Menati W, Valizadeh R, Menati R, Niazi M, Nazarzadeh M, Bidel Z. Determination of opium abuse prevalence in Iranian young people: a systematic review and meta-analysis. *Journal of Substance Use* 2017; 22(1):1-8.
3. Nikfarjam A, Shokoohi M, Shahesmaeili A, Haghdoost AA, Baneshi MR, Haji-Maghsoudi S, et al. National population size estimation of illicit drug users through the network scale-up method in 2013 in Iran. *Int J Drug Policy* 2016; 31:147-52.

In summary, the results of the present study showed the adverse impact of opium on testis structure indicated with a significant decrease in the number of spermatocytes, spermatogonia and spermatogenesis indexes including TDI, SI, RI and MSTD in adult male rats.

Since the use of opium and its derivatives is common during adolescent period and opium abuse could be associated with significant public health problems, prevention strategies for teenagers and young adults should integrate education on adverse effects of substance abuse, including opium and its derivatives, marijuana, opioids and alcohol. Moreover, patients receiving opioid drug for a long period should be monitored prospectively for the occurrence of opioid-induced adverse effects.

Conflict of interests:

The authors declare that there are no conflicts of interest.

Acknowledgments:

This work was supported by a grant from Kerman Physiology Research Center, Kerman University of Medical Sciences, Kerman, Iran

4. Sung HE, Richter L, Vaughan R, Johnson PB, Thom B. Nonmedical use of prescription opioids among teenagers in the United States: trends and correlates. *J Adolesc Health* 2005; 37(1):44-51.
5. United Nations Office on Drugs and Crime (UNODC). *World Drug Report. USA: UNODC; 2015.*
6. Fallahzadeh MA, Salehi A, Naghshvarian M, Fallahzadeh MH, Poustchi H, Sepanlou SG, et al. Epidemiologic study of opium use in pars cohort study: a study of 9000 adults in a rural southern area of Iran. *Arch Iran Med* 2017; 20(4):205-10.
7. Nakhaee N, Divsalar K, Meimandi MS, Dabiri S. Estimating the prevalence of opiates use by unlinked anonymous urine drug testing: a pilot study in Iran. *Subst Use Misuse* 2008; 43(3-4):513-20.
8. Hser YI, Evans E, Grella C, Ling W, Anglin D. Long-term course of opioid addiction. *Harv Rev Psychiatry* 2015; 23(2):76-89.
9. Asiabanha M, Asadikaram G, Rahnema A, Mahmoodi M, Hasanshahi G, Hashemi M, et al. Chronic opium treatment can differentially induce brain and liver cells apoptosis in diabetic and non-diabetic male and female rats. *Korean J Physiol Pharmacol* 2011; 15(6):327-32.
10. Najafipour H, Masoomi M, Shahesmaeili A, Haghdoost AA, Afshari M, Nasri HR, et al. Effects of opium consumption on coronary artery disease risk factors and oral health: results of Kerman coronary artery disease risk factors study a population-based survey on 5900 subjects aged 15-75 years. *Int J Prev Med* 2015; 6:42.
11. Najafipour H, Beik A. The impact of opium consumption on blood glucose, serum lipids and blood pressure, and related mechanisms. *Front Physiol* 2016; 7:436.
12. Fadaei A, Sohrabpour H, Taherkhanchi B, Seddighi Moghdaam HR, Bagheri B. Effects of opium inhalation on pulmonary volumes in smoking patients. *Journal of Paramedical Sciences* 2015; 6(1):72-4.
13. Kurita G, Lundström S, Sjøgren P, Ekholm O, Christrup L, Davies A, et al. Renal function and symptoms/adverse effects in opioid-treated patients with cancer. *Acta Anaesthesiol Scand* 2015; 59(8):1049-59.
14. Rogal S, Dew MA, DiMartini A. High-dose opioid use and liver transplantation: an underestimated problem? *Liver Transpl* 2017; 23(3):285-7.
15. Ahmed MA, Kurkar A. Effects of opioid (tramadol) treatment on testicular functions in adult male rats: the role of nitric oxide and oxidative stress. *Clin Exp Pharmacol Physiol* 2014; 41(4):317-23.
16. Ghowsi M, Yousofvand N. Impact of morphine dependency and detoxification by methadone on male's rat reproductive system. *Iran J Reprod Med* 2015; 13(5):275-82.
17. Jamshidian H, Amini E, Karvar M, Ayati E, Pishgar F, Zavarehei MJ, et al. Effects of opium dependency on testicular tissue in a rat model: an experimental study. *Urol J* 2019; 16(4):375-9.
18. Fronczak CM, Kim ED, Barqawi AB. The insults of illicit drug use on male fertility. *J Androl* 2012; 33(4):515-28.
19. Ghoneim FM, Khalaf HA, Elsamanoudy AZ, Helaly AN. Effect of chronic usage of tramadol on motor cerebral cortex and testicular tissues of adult male albino rats and the effect of its withdrawal: histological, immunohistochemical and biochemical study. *Int J Clin Exp Pathol* 2014; 7(11):7323-41.
20. Safarinejad MR, Asgari SA, Farshi A, Ghaedi G, Kolahi AA, Irvani S, et al. The effects of opiate

- consumption on serum reproductive hormone levels, sperm parameters, seminal plasma antioxidant capacity and sperm DNA integrity. *Reprod Toxicol* 2013; 36:18-23.
21. Subirán N, Casis L, Irazusta J. Regulation of male fertility by the opioid system. *Mol Med* 2011; 17(7-8):846-53.
 22. Mao J, Sung B, Ji RR, Lim G. Neuronal apoptosis associated with morphine tolerance: evidence for an opioid-induced neurotoxic mechanism. *J Neurosci* 2002; 22(17):7650-61.
 23. Ribeiro CT, De Souza DB, Costa WS, Pereira-Sampaio MA, Sampaio FJ. Effects of testicular transfixation on seminiferous tubule morphology and sperm parameters of prepubertal, pubertal, and adult rats. *Theriogenology* 2015; 84(7):1142-8.
 24. Meistrich ML, Wilson G, Porter KL, Huhtaniemi I, Shetty G, Shuttlesworth GA. Restoration of spermatogenesis in dibromochloropropane (DBCP)-treated rats by hormone suppression. *Toxicol Sci* 2003; 76(2):418-26.
 25. Nematollahi-Mahani SN, Labibi F, Shahidzadeh yazdi Z, Karamad E, Habibzadeh V, Naderi T, et al. The impact of opium dependence and cigarette smoking on human semen parameters. *Anatomical Sciences Journal* 2014; 11(4):189-96.
 26. Khar Razi D, Kianifard D, Khalilzadeh E. Investigation of opioid growth factor pathway inhibition on the histologic structure of testicular tissue and microscopic indices of spermatogenesis in adult diabetic mice. *Romanian Journal of Diabetes Nutrition and Metabolic Diseases* 2017; 24(1):13-20.
 27. Bhoir KK, Suryawanshi SA, Pandey AK. Alteration in serum luteinizing hormone (LH), testosterone (T) levels and testicular morphology of albino *Mus Norvegicus* induced by sublethal heroin administration. *Journal of Experimental Zoology, India* 2016; 19(1):9-15.
 28. Mohammadzadeh E, Amjadi F-S, Movahedin M, Zandieh Z, Nazmara Z, Eslahi N, et al. In vitro development of embryos from experimentally Kerack-addicted Mice. *Int J Reprod Biomed (Yazd)* 2017; 15(7):413-22.
 29. Vuong C, Van Uum SH, O'dell LE, Lutfy K, Friedman TC. The effects of opioids and opioid analogs on animal and human endocrine systems. *Endocr Rev* 2010; 31(1):98-132.
 30. Katz N, Mazer NA. The impact of opioids on the endocrine system. *Clin J Pain* 2009; 25(2):170-5.
 31. Eyvazzadeh AD, Pennington KP, Pop-Busui R, Sowers M, Zubieta JK, Smith YR. The role of the endogenous opioid system in polycystic ovary syndrome. *Fertil Steril* 2009; 92(1):1-12.
 32. Grachev P, Li XF, Kinsey-Jones JS, Di Domenico AL, Millar RP, Lightman SL, et al. Suppression of the GnRH pulse generator by neurokinin B involves a κ -opioid receptor-dependent mechanism. *Endocrinology* 2012; 153(10):4894-904.