

An Unusual Case of Familial Systemic Lupus Erythematosus with Distal Renal Tubular Acidosis and Hemolytic Anemia

Shipra Agrwal, Mukta Mantan, Aashima Dabas

Department of Pediatrics,
Maulana Azad Medical College,
New Delhi, India

Keywords. Systemic lupus erythematosus, renal tubular acidosis, hemolytic anemia

Systemic lupus erythematosus (SLE) in children is associated with renal involvement in majority of cases. While glomerular involvement is a common manifestation, tubular involvement is rare. Tubular dysfunctions previously described with SLE are renal tubular acidosis (Type 1 and less commonly type 4). Isolated renal tubular acidosis without glomerular involvement has not been reported in childhood SLE. We report an adolescent girl with SLE, autoimmune thyroiditis and distal RTA who subsequently developed autoimmune hemolytic anemia. During a follow-up of almost 7 years the girl never developed any proteinuria while the RTA persisted. Also during this period, her mother was diagnosed with SLE manifesting with thrombocytopenia.

IJKD 2019;13:337-9
www.ijkd.org

INTRODUCTION

Childhood systemic lupus erythematosus (SLE) commonly involves kidneys with a prevalence of 50%-75% but isolated renal tubular acidosis (RTA) is rare.¹ The proposed mechanisms for RTA in autoimmune disorders are development of autoantibodies against transporters and carbonic anhydrase enzyme and local tissue inflammation.² We report an adolescent girl with familial SLE who was initially diagnosed with distal RTA and later developed autoimmune hemolytic anemia (AIHA).

CASE REPORT

A 14 years old girl presented at our center with poor growth, polyuria, polydipsia and bony deformities of lower limbs. She did not have any history of recurrent infections, chronic diarrhea, blood transfusion, polyphagia, photosensitivity, or joint swelling. She had previously been diagnosed with autoimmune hypothyroidism at 12 years of age and was on thyroxine supplements at the time of presentation.

She had genu valgus, her weight, height, and BMI were 27 kg (-2.6 SDS), 134 cm (-3.1 SDS),

and 15 kg/m² (< -3 SDS); respectively. The sexual maturity rating was at Tanner stage 2. The rest of the general, physical, systemic examination, and blood pressures were normal.

The investigations at initial evaluation are given in Table. She had normal anion gap metabolic acidosis with a concomitant urinary PH of 7, a positive urinary anion gap with hypokalemia, and no proteinuria. The antinuclear antibody (ANA) was done due to presence of autoimmune thyroiditis and it was positive, an anti-double standard DNA (dsDNA) was negative. The complement levels were not done. The simple radiography of the knee showed features of rickets while that of the abdomen showed bilateral dense nephrocalcinosis, which was confirmed by sonography (Figure a and b).

Diagnosis of distal RTA with rickets was made. A possibility of distal RTA secondary to SLE was considered in view of concomitant hypothyroidism and positive ANA however there was no indication for use of immunosuppressants. Alkali therapy with potassium was started for her and she showed improvement in polyuria and generalized weakness.

Table. Investigations at Initial Presentation

Parameter	Value
Hemoglobin, g/dL	12.8
Total Leukocyte Counts, L	6.4×10^9
Platelet Counts, L	152×10^9
Serum Creatinine, mg/dL	0.7
Blood Urea, mg/dL	20
Serum Sodium, mEq/L	136
Serum Potassium, mEq/L	2.9
Serum Calcium, mg/dL	9.0
Serum Phosphate, mg/dL	4.3
Serum Vitamin D, ng/mL	40
Alkaline Phosphatase, IU/L	676
Serum Albumin, g/dL	3.6
Serum Cholesterol, mg/dL	143
Venous Blood Gas	pH = 7.2, HCO_3^- = 14.9 (mEq/L)
Serum Anion Gap, mEq/L	12
Urine Calcium/Creatinine Ratio, mg/mg	0.27

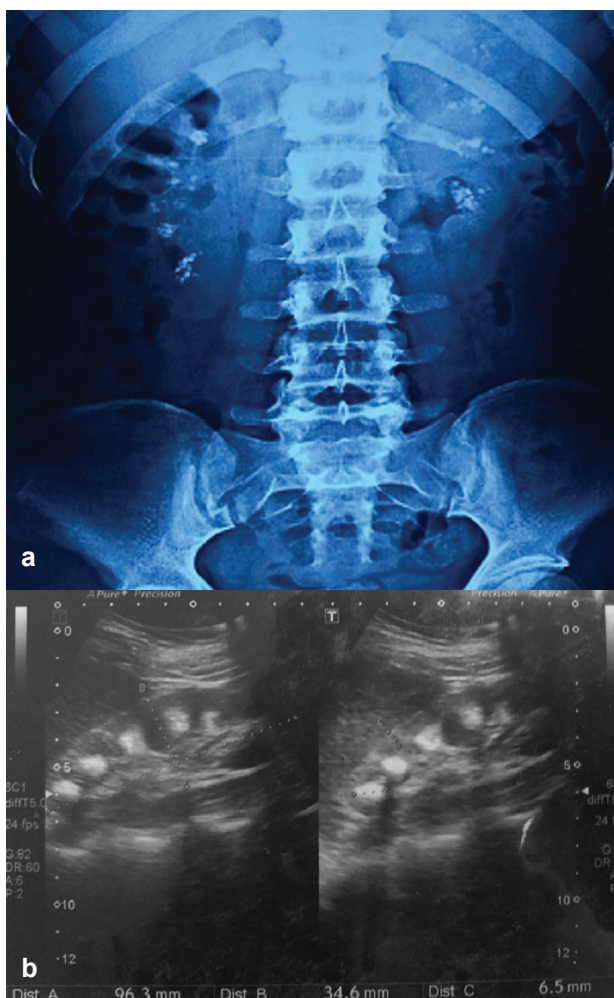


Figure. The simple radiography of the abdomen showed bilateral dense nephrocalcinosis (a), which was confirmed by sonography (b).

The rickets healed and serum potassium levels normalized. She attained menarche when she was 16.5 years old and her final height was 137 cm.

Meanwhile, her 50 years old mother was diagnosed with idiopathic thrombocytopenia with megakaryocytosis and ANA positivity. Her dsDNA was negative and complement C3 levels were normal. A diagnosis of lupus associated thrombocytopenia was made and she recovered on treatment with oral prednisolone. She did not have any skin, joint or renal manifestations of SLE.

At the age of 21 our patient presented with recurrent headaches, fever, and progressive pallor for 2 months. She had severe pallor and splenomegaly without icterus, petechial rash, ecchymosis, or hepatomegaly. The investigations showed the presence of macrocytic anemia (hemoglobin of 4.8 g/dL), the total leucocyte count 4.9×10^9 /L, and platelet count 120×10^9 /L. Direct coomb's test was positive (3+) and lactate dehydrogenase was elevated (660 U/L). The serum B12 and folate levels were normal while ferritin levels were elevated. Her ANA was positive, the complement C3 levels were low (68.6 mg/dL) and anti-dsDNA was negative. Workups for malaria and tuberculosis was negative and she was diagnosed as autoimmune hemolytic anemia (AIHA) related to SLE.

She received blood transfusion and prednisolone started at 2mg/kg/d. Her hemoglobin improved and remained stable, splenomegaly regressed and DCT became negative. Steroid was gradually tapered to a low dose at the end of 12 weeks. At last follow-up she was on low dose prednisolone (5 mg/d) and alkali therapy (5 mEq/kg/d). Her hemoglobin was 12.5 gm/dL, total leucocyte and platelet counts were normal, ESR was 56 mm, PH was 7.36 and serum bicarbonate was 20.4 mEq/L. She did not develop any proteinuria or hematuria till now. Her final diagnosis is familial SLE with distal RTA, autoimmune thyroiditis, and hemolytic anemia.

DISCUSSION

Tubular involvement is less common in pediatric SLE. Li *et al.* described 6 adults with SLE and RTA was diagnosed after the diagnosis of SLE with a mean gap of 3 years. Five (83.3%) of these patients had proteinuria implying glomerular involvement.³ Bagga *et al.* reported a 10 years

old girl initially diagnosed as RTA when she presented with hypokalemic paralysis. Four years later she presented with nephrotic syndrome and was diagnosed as lupus nephritis that improved with immunosuppression.⁴ Nandi *et al.* reported a 9 years old girl initially diagnosed as distal RTA with nephrocalcinosis during evaluation for short stature; 1 month later she presented with features of nephrotic syndrome and was diagnosed as SLE.⁵

Autoimmune thyroid disorders have been reported in 7%-17% of the patients with SLE with antithyroid autoantibody positivity in 6%-50% of the total patients.^{6,7} AIHA occurs in 5%-10% of the patients with SLE.⁸ Gormezano *et al.* showed a higher incidence of AIHA in childhood SLE compared to adult patients (14% vs. 3%).⁹

Familial lupus accounts for 10% of the cases of SLE.¹⁰ Phenotypic presentation may vary significantly and is also affected by environmental factors.¹¹ In this report, the mother and the daughter had lupus with different age of onset and manifestations. However, we could not perform any genetic studies due to financial constraints.

Most unusual feature in our patient was absence of any glomerular involvement despite having significant tubular involvement. In all the previous reports where RTA preceded the diagnosis of SLE, glomerular involvement also occurred during follow-up. A renal biopsy was not done due to the presence of dense nephrocalcinosis.

To conclude, the question still remains whether the RTA is a part of SLE or it is a case of primary RTA with other manifestations of SLE in this young girl. Lupus should be considered in patients with RTA even in the absence of glomerular involvement if features of autoimmunity are present.

REFERENCES

1. Levy DM, Kamphuis S. Systemic Lupus Erythematosus in Children and Adolescents. *Pediatr Clin N Am.* 2012;59:345–64.

2. Both T, Zietse R, Hoorn EJ, et al. Everything you need to know about distal renal tubular acidosis in autoimmune disease. *Rheumatol Int.* 2014; 34:1037–45.
3. Li SL, Liou LB, Fang JT, Tsai WP. Symptomatic renal tubular acidosis (RTA) in patients with systemic lupus erythematosus: an analysis of six cases with new association of type 4 RTA. *Rheumatology.* 2005; 44:1176–80.
4. Bagga A, Jain Y, Srivastava RN, Bhuyan UN. Renal tubular acidosis preceding systemic lupus erythematosus. *Pediatr Nephrol.* 1993; 7:735-6.
5. Nandi M, Das MK, Nandi S. Failure to Thrive and Nephrocalcinosis due to Distal Renal Tubular Acidosis: A Rare Presentation of Pediatric Lupus Nephritis. *Saudi J Kidney Dis Transpl.* 2016;27:1239-41.
6. Kakehasi AM, Dias VN, Duarte JE, Lanna CC, Carvalho MA. Thyroid Abnormalities in Systemic Lupus Erythematosus: a Study in 100 Brazilian Patients. *Rev Bras Reumatol.* 2006; 46:375-9.
7. Pyne D, Isenberg DA. Autoimmune thyroid disease in systemic lupus erythematosus. *Ann Rheum Dis.* 2002; 61:70–2.
8. Domiciano DS, Shinjo SK. Autoimmune hemolytic anemia in systemic lupus erythematosus: association with thrombocytopenia. *Clin Rheumatol.* 2010; 29:1427–31.
9. Gormezano NWS, Kern D, Pereira OL, et al. Autoimmune hemolytic anemia in systemic lupus erythematosus at diagnosis: differences between pediatric and adult patients. *Lupus.* 2016;0:1–5.
10. Chen LY, Shi ZR, Tan GZ, Han YF, Tang ZQ, Wang L. Systemic lupus erythematosus with and without a family history: a meta-analysis. *Lupus.* 2017;0:1–6.
11. Kuo CF, Grainage MJ, Valdes AM, et al. Familial Aggregation of Systemic Lupus Erythematosus and Coaggregation of Autoimmune Diseases in Affected Families. *JAMA Intern Med.* 2015; 175:1518-26.

Correspondence to:

Shipra Agrwal, MD

Department of Pediatrics, Maulana Azad Medical College, New Delhi, India

Tel: +96 54244982

E-mail: shiprapaeds@gmail.com

Received December 2018

Revised March 2019

Accepted July 2019