

Bardet-Biedl 9 Syndrome, A Rare Mutation

Farshid Oliaei,¹ Hossein Narimani²

¹Cellular and Molecular Biology Research Center, Cancer Research Center, Health Research Institute, Clinical Research Development Center, Shahid Beheshti Hospital, Department of Internal Medicine, School of Medicine, Babol University of Medical Sciences, Babol, Iran
²Student Research Committee, Babol University of Medical Science, Babol, Iran

Bardet-biedl syndrome (BBS) is a rare heterogenous autosomal recessive disease due to defects in primary cilia which until now, up to 21 types have been detected. A few reports of BBS in Iran have been published but this is the first type 9 genotyped and clinically discussed case. This type can cause severe and delayed onset renal failure.

IJKD 2020;14:153-6
www.ijkd.org

Keywords. bardet-biedl syndrome, renal disease, genotyping

INTRODUCTION

Bardet-Biedl syndrome (BBS) was first described in 1920, as a rare heterogeneous autosomal recessive disease which occurs within families with variable expression.¹ These are ciliopathies caused by defects in primary or immotile cilia. These cilia function mainly as a sensory organelle and by regulating signal transduction pathways, cause alterations of both transport and paracrine signals such as planar cell polarity pathways.²⁻⁴ Until now, up to 21 types have been detected.⁵ BBS manifests as primary and/or secondary features. Over 6 primary features and more than 10 secondary features have been described in this syndrome. The primary ones are rod-cone dystrophy, polydactyly, obesity, learning problems, hypogonadism and renal malfunction. Some of secondary features are cataract, diabetes mellitus, brachydactyly, syndactyly, speech difficulties, heart problems, strabismus and ataxia.⁶ It is defined that 4 primary or 3 primary plus 2 secondary features establish diagnosis of BBS.⁷ In this article, a rare BBS variant patient is reported in north of Iran that is documented by genotyping study.

CASE REPORT

A 50 years old man was brought to hospital

due to anorexia and vomiting. He was single and had no past medical history of kidney disease. On physical examination, he was obese (BMI = 33.2 kg/m²), blind and had polydactyly and syndactyly in both hands and brachydactyly in hands and feet (Figure 1). He didn't seem to be mentally retarded. Hypogonadism was also detected. His parents were relatives. According to his condition and laboratory tests results (Cr = 7.4 mg/dL, Hb = 9.5 g/dL), uremia was diagnosed and hemodialysis began. Ultra sonography showed bilateral small kidneys with small cysts. Severe hyperparathyroidism (iPTH = 988 pg/mL) was also detected. He was obese since birth but his blindness had been begun from the age of 14 with blindness over night at first and then gradually progressed. According to above symptoms, Bardet-Biedl syndrome was diagnosed. To clarify the type, patient's DNA was sent to a genetic laboratory.

Genotyping

By NGS method, one homozygous mutation C.1789 + 1G > A on BBS 9 gene was detected. The mutation was a splice type that affects the mRNA's splicing. Mutation location was in Intron 17. The involved chromosome was 7 (Location: 33407475) (Figure 2).

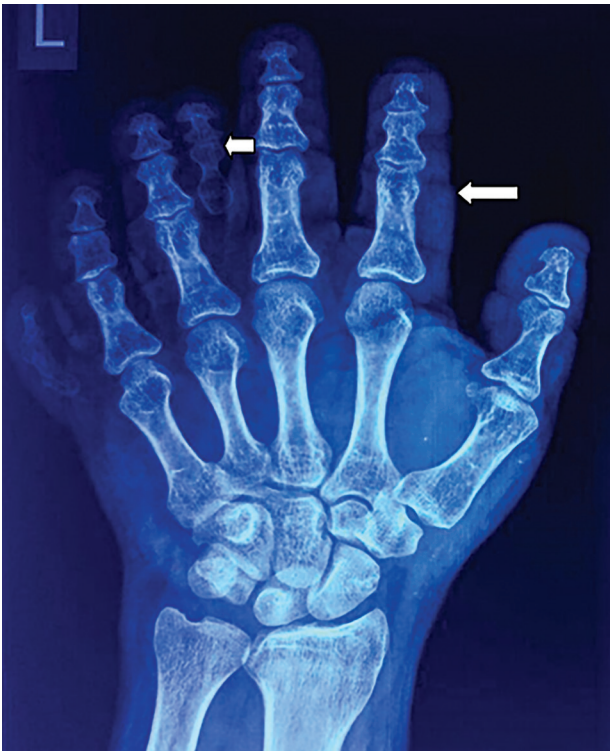

Figure 1. It shows polydactyly, brachydactyly, and syndactyly in the left of the patient (arrows).

DISCUSSION

To our knowledge, this is the first genotypically

defined and clinically discussed case of BBS 9 in Iran. Ghadimi *et al* (2000) described an Iranian family with 7 affected BBS 3 members,⁸ but we do not know where they lived because the study had been done in Japan. In addition, Fattahi *et al* (2014) characterized the mutation profile of BBS genes in several Iranian families, but it is exclusively a genetic study with no clinical justification.⁹

We found a few Iranian case reports, which were about introducing the disease, symptoms or outcomes. None of them defined the type of the disease.^{10,11}

Overall, BBS is rare; from 1: 120000 live births reaching to (1: 17000) in some areas like Canada and Kuwait. BBS 1 and 10 are the most common types (50% of all cases).⁴ BBS is inherited mostly in an autosomal recessive pattern although dygenic (trialelic) inheritance has also been reported.¹ Although it seems that there is no genotype / phenotype correlation in different BBS types, few reports tried to show a pattern; for example extra digits found to be more common in BBS 4, ocular phenotypes more seen in BBS 2,3, and 4.¹² In BBS1, there is less severe ophthalmologic involvement¹³ whereas insulin resistance and visceral adiposity are more prevalent in BBS 10 than type 1.¹⁴ These correlations have not

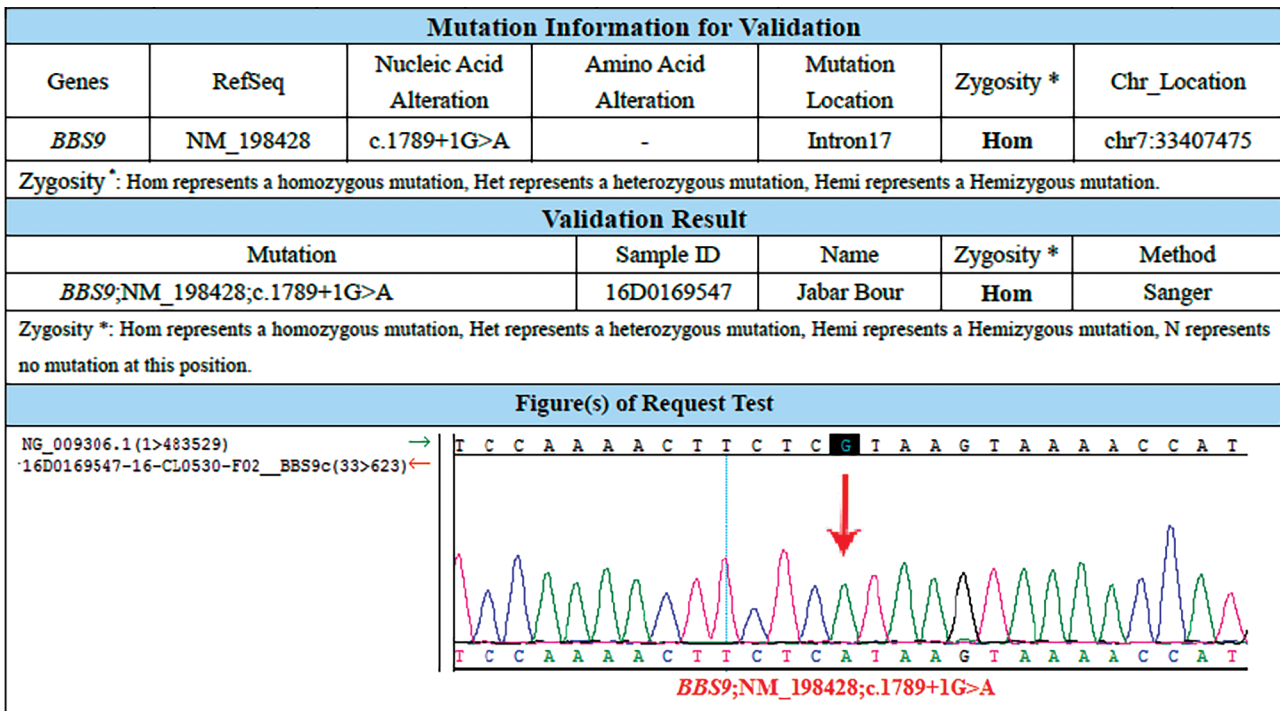


Figure 2. It determines gene analysis demonstrating pathologic mutation.

been confirmed in large studies. BBS 1, 2, 4, 5, 7, 8, and 9 constitute the BBsome; implicated in vesicular transport toward the cilium and promote maintenance and ciliogenesis. BBS9 is defined as usually severe pigmentary retinopathy, early onset obesity, polydactyly, hypogonadism, renal disease, and mental retardation. Minor symptoms include diabetes mellitus and congenital heart disease. In our case, he was mentally perfect and except heart disease, all other manifestations existed. Renal disease is a major cause of morbidity and mortality. This patient genotypically was BBS 9. The defective gene is on chromosome 7 P 14 as PTH B1 gene (parathyroid responsive gene B1). The expression of the BBS 9 protein is down regulated by PTH in osteoclastic cells and therefore is thought to be involved in PTH action in bones.¹⁵

Renal abnormalities (calyceal clubbing, diverticula, or cysts) can be detected in 96% of cases. The most common and earliest functional abnormality is a reduced ability to concentrate the urine, resulting in polyuria, and polydipsia. CKD is reported in 25–50% of cases.⁴ The spectrum of renal involvement in BBS is very wide, in BBS 1 it is mild¹⁶ whereas seems to be more severe but delayed onset in BBS 9 as presented in our case. According to Fattahi *et al*, there are some different mutations in Iranian families; for example finding two cases of rare BBS 9, no cases of prevalent BBS 1, and BBS 10; indicates some differences between Iran and west countries. Hence this would not be surprising to find a new case of BBS 9 as in our report.

CONCLUSION

BBS 9 as a rare genotype among other BBS variants leads to severe renal involvement that mandates urgent management. Fortunately kidney transplantation can be done safely as for other types of BBS.

ACKNOWLEDGEMENT

We thank Mrs. Mehdinia for typing and editing this manuscript and Mrs. Sakineh Kamali Ahangar, staff of the clinical research and development of Shahid Beheshti Hospital (Babol) for her cooperation.

REFERENCES

1. Abu- Safieh L, Al – Anazi S, Al – Abdi L et al . In search of triallelism in Bardet – Biedl syndrome . *Europ J Hum*

Genet 2012; 20: 420-427 .

2. Agha Z, Iqbal Z, Azam M, Hoefsloot LH, Van Bokhoven H, Qamar R . A novel homozygous 10 nucleotide deletion in BBS10 causes Bardet – Biedl syndrome in a Pakistani family . *Gene* 2013; 519: 177-181 .
3. Foggensteiner L, Beales P . Bardet – Biedl syndrome in: Turner N, Lameire N, Gold smith DJ et al . *Oxford textbook of clinical nephrology* Forth ed . Oxford University Press . 2016: PP: 2665-2666 .
4. Torres VE, Grantham JJ . Cystic diseases of the kidney in: Taal MW, Chertow GM, Marsden PA et al . *Brenner & Rector's the kidney* . 9th ed . Saunders . 2012: PP: 1652-1653 .
5. Hoen E, Kim G, Qin S et al . Mutations in C8ORF37 cause Bardet – Biedl syndrome (BBS 21). *Hum Mol Genet* 2016 1; 11: 2283-2294 .
6. Ajmal M, Khan MI, Neveling K, Tayyab A, Jaffar S, Sadeque A et al . Exome sequencing identifies a novel and a recurrent BBS 1 mutation in Pakistani families with Bardet – Biedl syndrome . *Molecular Vision* 2013; 19: 644-653 .
7. Beales P, Elcioglu N, Woolf AS, Parker D, Finter FA. New criteria for improved diagnosis of Bardet- Biedl syndrome: results of a population survey. *J Med Genet* 1999; 36:437-46
8. Ghadimi M, Tomita HA, Najafi MT, Damavandi E, Farahvash MS, Yamada K, et al. Bardet-Biedl syndrome type 3 in an Iranian family: clinical study and confirmation of disease localization. *Am J Med Genet.* 2000 Oct 23;94(5):433-7
9. Fattahi Z, Rostami P, Najmabadi A, Mohseni M, Kahrizi K, Akbari MR, et al. Mutation profile of BBS genes in Iranian patients with Bardet-Biedl syndrome: genetic characterization and report of nine novel mutations in five BBS genes. *J Hum Genet* 2014;59,368-375
10. Sharifian M, Dadkhah M, Einollahi B, Nafar M, Simforoosh N, Basiri A, et al. The outcome of renal transplantation in Bardet-Biedl syndrome. *Iran J Pediatr.* Vol 16, No 1, March 2006
11. Fallah Karkan M, Monfared A, Farahmand Porkar N. Bardet-Biedl syndrome; a case report of a woman suffering from renal failure. *J Gilan Univers Med Sci*, No 91, 68-72
12. Riise R, Tornqvist K, Wright AF, Mykytyn K, Sheffield VC. The phenotype in Norwegian patients with Bardet-Biedl syndrome with mutations in the BBS4 gene. *Acta Ophthalmol.* 2002;120:1364-1367
13. Daniels AB, Sandberg MA, Chen J, Wiegel-Di Franco C, Hejtmanck JF, Berson EL. Genotype-phenotype correlations in Bardet-Biedl syndrome. *Arch Ophthalmol.* 2002, 130(7):901-907
14. Feuillan PP, Ng D, Han JC, Sapp JC, Wetsch K, Spaulding E. Patients with Bardet- Biedl syndrome have hyperleptinemia suggestive of leptin resistance. *J Clin Endocrinol Metab.* 2011, Vol 96,3, 528-535
15. Nishimura DY, Swiderski RE, Searby CC, Berg EM, Ferguson AL, Hennekam R et al . Comparative genomics and gene expression analysis identifies BBS 9, a new Bardet – Biedl syndrome gene. *Am J Hum Genet* 2005; 77: 1021-1033 .

16. Forsythe E, Sparks K, Best S, Borrows S, Hoskins B, Sabir A et al . Risk factors for severe renal disease in Bardet – Biedl syndrome . J Am Soc Nephrol 2016; 22: (abstract only)

Correspondence to:

Farshid Oliaei, MD

Cellular and Molecular Biology Research Center, Cancer Research Center, Health Research Institute, Clinical Research Development Center, Shahid Beheshti Hospital, Department of Internal Medicine, School of Medicine, Babol University of Medical Sciences, Babol, Iran

E-mail: bcrdc90@yahoo.com

Received September 2019

Revised November 2019

Accepted January 2020