

A Giant Ovarian Serous Cystadenoma in Pregnancy: A Case Report

Jila Agah (MD)^{1*}, Seyed Javad Davari Sani (MSc)², Kowsar Salmani (MSc)²

¹ Assistant professor, Department of Obstetrics and Gynecology oncology, Faculty of Medicine, Sabzevar University of Medical Sciences, Sabzevar, Iran

² Medical Student, Student Research Committee, School of Medicine, Sabzevar University of Medical Sciences, Sabzevar, Iran

ARTICLE INFO	ABSTRACT
<p><i>Article type:</i> Case report</p> <hr/> <p><i>Article History:</i> Received: 24-Nov-2017 Accepted: 29-Aug-2018</p> <hr/> <p><i>Key words:</i> Ovary Cystadenoma Pregnancy</p>	<p>Background: Diagnosis of ovarian mass during pregnancy may be postponed because they may mimic physiological signs of pregnancy. Ovarian masses can lead to complications such as overgrowth, torsion or cyst rupture. Therefore, to inform health providers concerning symptoms, safe diagnostic methods and proper management seem appropriate.</p> <p>Case report: A 19-year-old primigravida was presented to our clinic in the 16th week of gestation with an ultrasound document revealing a giant solid-cystic mass extending from pelvis to diaphragm, which was probably an ovarian cyst. During the ultrasound assessment of pregnancy, the mass was discovered incidentally. The only complaint of patient was insignificant abdominal bloating attributed to dyspepsia. Vital signs and laboratory tests, including tumor markers, were within normal limits. During laparotomy, an ovarian multilocular cyst extending beneath the diaphragm and measuring about 50 cm and 10 kg using was removed using a different technique. The volume of the cyst was decreased before the removal by inserting an angio catheter and withdrawing some fluid. Through this procedure, we prevented spillage of cystic fluid into the abdomen and pressed pregnant uterus during mass extraction. Ovarian serous cystadenoma was confirmed by pathology evaluation. Pregnancy passed normally until the delivery of a 3100-gm baby in the 38th week of gestation.</p> <p>Conclusion: Proper diagnosis of masses during pregnancy can save maternal and fetal health through preventing adverse outcomes, such as abortion or preterm labor. Therefore, pregnant women's complaints and precise physical examination should be taken into account in prenatal care centers. Also, surgical intervention with the least uterine manipulation is recommended in these cases.</p>

► Please cite this paper as:

Agah J, Davari Sani SJ, Salmani K. A Giant Ovarian Serous Cystadenoma in Pregnancy: A Case Report. Journal of Midwifery and Reproductive Health. 2018; 6(4):1486-1490. DOI: 10.22038/jmrh.2018.27878.1302.

Introduction

About 0.2-2% of pregnancies are accompanied by adnexal masses, which are usually found incidentally during caesarian section (C-section; 1/200-400 C-sections) (1). Of these, 33% are non-neoplastic (luteal cysts), 63% benign (i.e., dermoid cyst 36%, serous cystadenoma 17%, and mucinous cystadenoma 8%), and 3% malignant (i.e., low malignant potential or adenocarcinoma) (2).

Adnexal masses are usually asymptomatic and incidentally detected. Before extensive use of ultrasound, they are usually discovered during C-section or when they become symptomatic(3). The majority of adnexal masses

originate from the ovaries. Most ovarian masses that are recognized in the first trimester can be resolved spontaneously because they are commonly simple functional cysts by nature. Nonetheless, neoplastic types do not disappear and may gradually become enlarged and symptomatic (4). Ovarian neoplasms are classified into three main groups including germ cell, sex cord-stromal, and epithelial neoplasms (the most prevalent). Adnexal masses measuring more than 5 cm, especially with a solid component in imaging, are most likely to be non-functional (5).

Generally, the symptoms are non-specific

¹ * Corresponding author: Jila Agah, Assistant professor, Department of Obstetrics and Gynecology oncology, Faculty of Medicine, Sabzevar University of Medical Sciences, Sabzevar, Iran. Tel: 0915512654; Email: jilaagah@yahoo.com

and attributed to physiological changes in pregnancy; thus, the diagnosis may be postponed with the consequence of mass overgrowth, adnexal torsion, or cystic rupture, infection, malignancy, impaction of cyst in pelvis, which sometimes requires prompt laparotomy (6). Torsion is the most regular complication among these patients. The risk of ovarian torsion rises by 5-fold during pregnancy which is more common during the first trimester (7, 8). Since the pregnancy may be compromised by such complications as urinary retention, obstructed labor, fetal malpresentation, abortion or preterm labor, a multidisciplinary approach is required to save the mother and neonate in these conditions. Here, we presented the case of a giant ovarian multi-cystic mass in a pregnant woman, which was asymptomatic and recognized incidentally in spite of its large size.

Case report

In 2014 a 19-year-old primigravida was presented to the clinic of Mobini Hospital Sabzevar, Iran, in the 16th week of gestation with an ultrasound document revealing a giant solid-cystic mass spreading from pelvis to diaphragm, which was probably an ovarian cyst. During the sonographic assessment of pregnancy, the mass was discovered incidentally. In general, the woman was slim with abdominal distention without any pain or tenderness, while her vital signs were normal. Besides, her past medical and surgical history was normal. The patient was admitted to the

hospital and surgical intervention was indicated.

Laboratory tests including complete blood count, creatinine, and tumor markers consisting of carcinoembryonic antigen (CEA), cancer antigen -125 (CA-125), and α -fetoprotein (α FP) were within normal limits. The surgery was performed under general anesthesia and a midline incision was made in the lower abdomen up to the umbilicus. Laparotomy revealed a giant multi-cystic mass extending up to the undersurface of the diaphragm. It originated from the right ovary, which completely destroyed the natural ovarian tissue. Ascites and peritoneal seeding were not observed. The 16-week-pregnant uterus was under the pressure of the mass. In order to be able to excise the cyst without intra-abdominal spillage, an angiocatheter was used and fluid extraction was performed to shrink the cyst. This operation caused less manipulation of the pregnant uterus during the mass excision which potentially could be a risk factor for abortion. Since there was no healthy tissue within the ovary at all, we performed a right salpingo-oophorectomy (Figure 1). There was no adhesion to the surrounding tissues (Figure 2).

The mass measured 50 cm and weighed 10 kg. The pathology report confirmed serous cystadenoma. The patient was discharged in three days in a good condition. A few months later, she gave birth to a healthy newborn weighing 3100 g in the 38th week of gestation. The 2-year follow-up showed her health status without any disease recurrence.

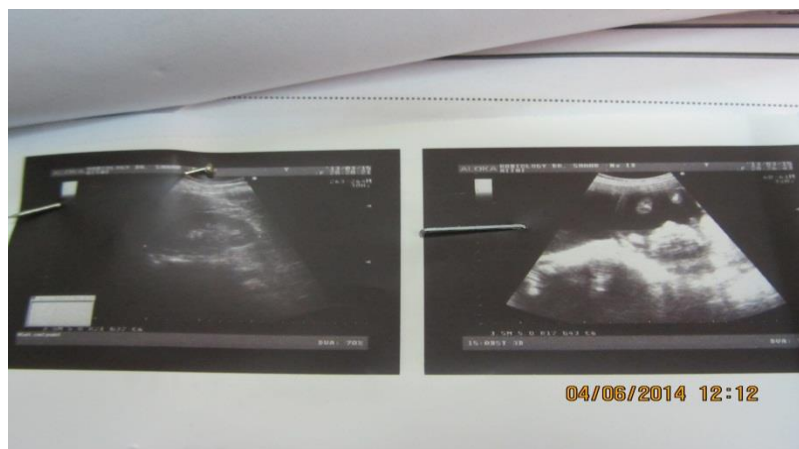

Figure 1. The giant ovarian cyst and pregnancy

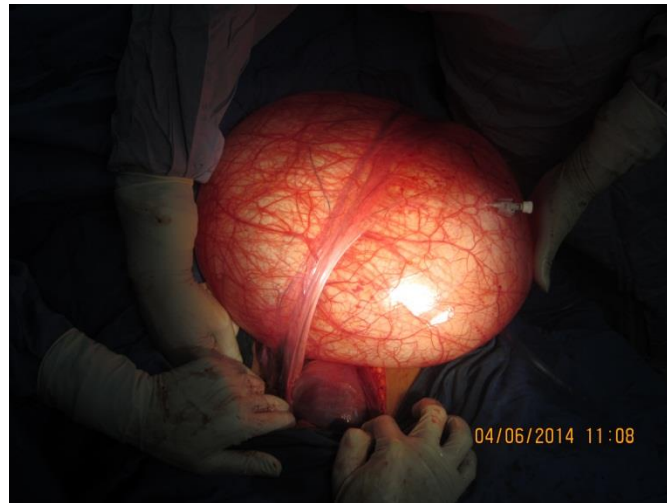

Figure 2. Ovarian multi-cystic mass (10 kg & 45 cm), with an angiocatheter which inserted to evacuate the fluid and decrease the size of cyst

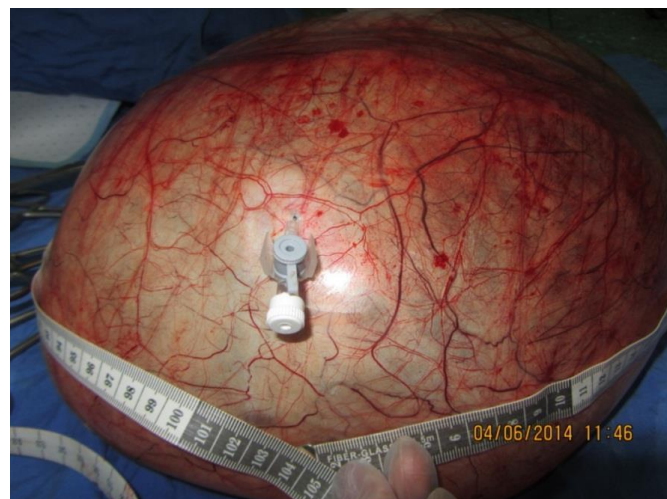


Figure 3. Ovarian multi-cystic mass (10 kg & 45 cm), with an angiocatheter which inserted to evacuate the fluid and decrease the size of cyst

Discussion

The incidence rate of ovarian serous cystadenoma in pregnancy is 5-28% (9). Giant cysts are found in less than 1% of ovarian cyst cases in pregnancy (10). It is very rare to find such an enormous abdominopelvic mass in a pregnant woman, free of significant symptoms. Adnexal mass has various manifestations during pregnancy. One of them is non-specific symptoms, such as back or abdominal pain, constipation, abdominal distension, and urinary complaints. Since these issues are generally attributed to regular problems of pregnancy, it may be neglected by either the patient or

physician. Another manifestation is palpable mass in the abdomen, pelvis, or recto-uterine pouch discovered at the time of prenatal visit. The other one is acute abdominal pain due to adnexal torsion or cystic rupture. About 5% of pregnancies involve adnexal torsion. It occurs more frequently in masses measuring 6-8 cm and nearly 60% of instances happen during 10-17 weeks of gestation (5, 11).

Considering our case, who was in the 16th week of pregnancy, the mass was too large to take the risk of torsion, but the pressure of the uterus was growing up outside the pelvis

alongside the cystic massive enlargement creating discomfort of abdominal swelling. As with similar patients, she thought it was related to normal signs of pregnancy and tolerated it until a huge mass was accidentally revealed by routine ultrasound. The advantages of ultrasonography in the diagnosis of adnexal mass during pregnancy include availability, inexpensiveness, non-teratogenicity for the neonate, and tolerability for the mother. The nature of the mass (benign or malignant) can be determined by this device.

Although simple cysts are generally physiologic and functional, hydrosalpinx and unilocular ovarian serous or mucinous cystadenoma should be considered as well. Benign complex masses with solid components can be hemorrhagic luteal cysts, mature teratomas, theca-lutein cysts, ectopic pregnancies, septate hydrosalpinx, endometriomas, pedunculated myomas and multilocular cystadenomas (like our case). However, the existence of papillary projections, solid components, superficial excrescences, peripheral tissue adherences, and ascites are in favor of malignancy. Computed tomography (CT) scan is not suggested in pregnancy due to its carcinogenic effect on the newborn. Administration of iodine contrast is contraindicated as it suppresses the thyroid function of the fetus. Magnetic resonance imaging (MRI) is recommended in special conditions. As tumor markers such as CA-125, CEA, α FP, and HCG are normally elevated in pregnancy, they would not be helpful in dealing with these patients (3, 5, 6). Tumor markers such as CA 125 show little clinical significance in pregnancy as they are increased in the first trimester and decrease with advancing gestational age (12). The other benign ovarian masses found are cystic teratomas, serous cyst adenomas, mucinous cystadenomas, paraovarian cysts and endometriomas (3) and malignant masses are rare. The serous cystadenomas are thin-walled and translucent cysts, which are usually unilocular, contain few septations, and are often unilateral (they can be bilateral as well) (13).

There is a consensus that the best time for surgery is the second trimester (like in our case). Since most cysts in the first trimester

are functional and resolve spontaneously, considering the theoretical risk of abortion, surgical intervention is not recommended in this period, except for emergency conditions. Surgeries in the third trimester increase the risk of preterm labor. Moreover, in our previous study we reported the case of a 3-Kg serous cystadenoma in the third trimester(14). Another study reported the case of a 7.5-Kg cystadenoma, a large ovarian tumor during pregnancy(15). It is said that ovarian cysts larger than 10 cm or masses containing solid components, septum or papillary projections must be removed by laparoscopy or laparotomy. The surgeon should be very precarious to apply a technique causing a little manipulation on pregnant uterus and avoiding cystic spillage in the abdominal cavity (6, 16). In this case, we used an angiocatheter to decrease the size of the cyst, excising it without rupture and avoiding stress on pregnant uterus, which absolutely had acceptable effects on obstetrical outcomes.

Conclusion

The symptoms of adnexal masses are non-specific and generally are physiologically associated with gastrointestinal or other disorders observed during pregnancy. Therefore, health providers must notice pregnant women's complaints and perform a proper physical examination to prevent neglected cases. Ultrasonography should be considered a safe method to detect suspected cases. Surgery should be based on the symptoms, the nature of the mass, and the stage of pregnancy, and it must be carried out carefully in order to prevent adverse obstetrical outcomes.

Acknowledgments

The authors would like to thank the authorities and the staff of Mobini Hospital for their contribution and cooperation in performing the patient follow-up.

Conflicts of Interest

The authors declare no conflicts of interest.

References

1. Schwartz N, Timor-tritsch IE, Wang E. Adnexal masses in pregnancy. *Clinical obstetrics and gynecology*. 2009;52(4):570-85.
2. Owens GL, Kitchener HC. Premalignant disease in

- the genital tract in pregnancy. *Best Practice & Research Clinical Obstetrics & Gynaecology*. 2016;33:33-43.
3. Leiserowitz GS, Xing G, Cress R, Brahmbhatt B, Dalrymple JL, Smith LH. Adnexal masses in pregnancy: how often are they malignant? *Gynecologic oncology*. 2006;101(2):315-21.
 4. Agah J, Karimzadeh S, Moharrer Ahmadi F. Misdiagnosis of a Giant Uterine Leiomyosarcoma: Clinic and Image Challenges. *Case reports in oncological medicine*. 2017;2017.
 5. Agah J, Jafarzadeh Esfehiani R, Kamalimanesh B, Fattahi Abdizadeh M, Jalilian AR. Mismanagement of a huge ovarian serous cystadenoma in a young girl; a case report. *Journal of midwifery and reproductive health*. 2015;3(1):315-7.
 6. Kamalimanesh B, Esfehiani RJ, Agah J. Papillary serous cystadenoma of ovary: A huge ovarian cyst complicating the pregnancy. *Cases Obstet Gynecol*. 2016;3(4):121-4.
 7. Ventolini G, Hunter L, Drollinger D, Hurd W. Ovarian torsion during pregnancy. *Resident and Staff Physician*. 2005;51(9):26.
 8. Hibbard LT. Adnexal torsion. *American Journal of Obstetrics & Gynecology*. 1985;152(4):456-61.
 9. Patel AS, Desai DA. Ovarian mass with pregnancy. *International Journal of Scientific Research*. 2018; 6(3):26-29.
 10. Aujang ER. Giant ovarian cyst and pregnancy. Case report and literature review. *Ginecologia y obstetricia de Mexico*. 2011;79(04):235-8.
 11. Webb KE, Sakhel K, Chauhan SP, Abuhamad AZ. Adnexal mass during pregnancy: a review. *American journal of perinatology*. 2015;32(11): 1010-6.
 12. Condous G, Kirk E, Syed A, Van Calster B, Van Huffel S, Timmerman D, et al. Do levels of serum cancer antigen 125 and creatine kinase predict the outcome in pregnancies of unknown location? *Human Reproduction*. 2005;20(12):3348-54.
 13. Kuraishy A, Noor N, Mohsin Z. Twisted ovarian cyst in pregnancy: a case report. *International Journal of Reproduction, Contraception, Obstetrics and Gynecology*. 2018;7(8):3389-91.
 14. Katke R. A Giant Ovarian Tumour (7.5 kg) During Pregnancy with its Successful Perinatal and Surgical Outcome. *SAJ Case Reports 4: 104 Abstract* Keywords: Benign Mucinous Cystadenoma. 2017.
 15. Yakasai IA, Bappa LA. Diagnosis and management of adnexal masses in pregnancy. *Journal of surgical technique and case report*. 2012;4(2):79.