

Primary Malignant Lymphoma of Cervix: A Case Report

Laila Mousavi Seresht (MD)¹, Zohreh Yousefi (MD)^{2*}, Behrouz Davachi (MD)³, Amir Hosein Jafarian (MD)⁴, Mansoureh Mottaghi (MD)¹, Helena Azimi (MD)¹, Mojgan Soltani (MD)⁵, Yasaman Nikooiyan (BS)⁶, Tahereh Zavary (BS)⁶

¹ Fellow of Gynecologic Oncology, Department of Obstetrics and Gynecology, Faculty of Medicine, Mashhad University of Medical Sciences, Mashhad, Iran

² Professor, Department of Obstetrics and Gynecology, Faculty of Medicine, Mashhad University of Medical Sciences, Mashhad, Iran

³ Associate Professor, Department of Radiology, Faculty of Medicine, Mashhad University of Medical Sciences, Mashhad, Iran

⁴ Associate Professor, Department of Pathology, Faculty of Medicine, Mashhad University of Medical Sciences, Mashhad, Iran

⁵ Resident, Department of Obstetrics and Gynecology, Faculty of Medicine, Mashhad University of Medical Sciences, Mashhad, Iran

⁶ Medical Medical Student, Faculty of Medicine, Mashhad University of Medical Sciences, Mashhad, Iran

ARTICLE INFO	ABSTRACT
<p>Article type: Case report</p> <hr/> <p>Article History: Received: 07-Jun-2018 Accepted: 11-Sep-2018</p> <hr/> <p>Key words: Cervical cancer Cervix Lymphoma</p>	<p>Background: Primary malignant lymphoma of the uterine cervix is extremely rare and can be misdiagnosed due to its different clinical presentations. The aim of this report was to introduce a case of primary malignant lymphoma of the uterine cervix which was misdiagnosed as an ovarian cyst on ultrasonography.</p> <p>Case report: A 31-year-old female referred with a chief complaint of abnormal uterine bleeding. The ultrasound findings showed a suspicious malignant ovarian mass and the examinations demonstrated a large cervical mass which was considered as stage IB2 in the clinical staging of cervical cancer. However, a biopsy confirmed the presence of non-Hodgkin's B cell lymphoma of the cervix. Systemic chemotherapy followed by CHOP regimen (cyclophosphamide, adriamycin, vincristine, added to rituximab and prednisolone) was started based on the diagnosis. On the 14th month of serial follow-up, the patient was disease-free with no signs of a recurrence.</p> <p>Conclusion: A pelvic examination in patients with vaginal bleeding, vaginal discharge, and pelvic discomfort should be considered as the first step after taking the patient's medical history.</p>

► Please cite this paper as:

Mousavi Seresht L, Yousefi Z, Davachi B, Jafarian AH, Mottaghi M, Azimi H, Soltani M, Nikooiyan Y, Zavary T. Primary Malignant Lymphoma of Cervix: A Case Report. Journal of Midwifery and Reproductive Health. 2019; 7(4): 1981-1985. 10.22038/jmrh.2019.32538.1354

Introduction

Lymphoma of the female genital tract is a rare condition that accounts for 0.5 to 1% of all extranodal lymphomas. The prevalence of lymphoma of the cervix is less than 1% among all cervical cancers (1). In total, 185 cases with primary cervical lymphoma were reported according to the literature review of the MEDLINE database (2).

The primary malignant lymphoma of the uterine cervix is localized cervical cancer with no evidence of other sites of involvement or systemic leukemia (3). The most common clinical features of this condition are abnormal vaginal bleeding, perineal discomfort, persistent vaginal discharge, less frequently abdominal masses, dyspareunia, and urinary retention (4);

however, routine cervical screening tests are not diagnostic in most cases. It seems that the best treatment option for primary malignant lymphoma of the uterine cervix should be directed to the individual person and the case reports showed no widely accepted consensus on its management (4).

However, the chemotherapy treatment with a regimen of four drugs known as cyclophosphamide, doxorubicin, vincristine, and prednisone (CHOP) with or without rituximab has been shown to be effective (5).

Cubo et al. reported a 51-year-old female with a primary lymphoma who was successfully treated with combined rituximab chemotherapy (6). Kosari et al. treated a primary lymphoma of

* Corresponding author: Zohreh Yousefi, Professor, Department of Obstetrics and Gynecology, Faculty of Medicine, Mashhad University of Medical Sciences, Mashhad, Iran. Tel: 00985138012477 Email: info@zohrehyousefi.com

the uterine cervix with a combination of CHOP chemotherapy regimen and radiotherapy. However, central nervous system involvement led to the patient's death 20 months after diagnosis (3). Moreover, multimodality therapy may be utilized which is either chemotherapy or the combination of more than one method of cancer treatment.

Stroh et al. used chemotherapy and radiation for the treatment of 16 cases with lymphoma of the cervix. According to the results, 12 cases had received radiation and 90% of patients with low-risk factors were disease-free at 5 years follow-up (7).

Due to the scarce number of reported cases, there is no established therapeutic protocol; however, different cancer treatments, including radiotherapy, chemotherapy, and surgery are described in the literature. With this background in mind, the aim of this report was to introduce a case of primary malignant lymphoma of the uterine cervix which was misdiagnosed as an ovarian cyst on ultrasonography.

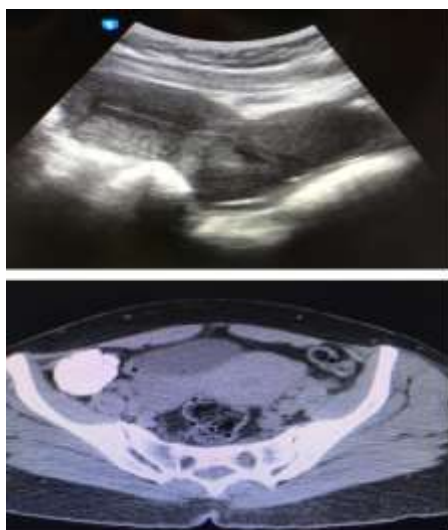Case report

A 31-year-old female referred to the Oncology Department of a teaching hospital affiliated to Mashhad University of Medical Sciences, Mashhad, Iran in 2017. Her chief complaint was abnormal uterine bleeding for

the past 6 months. The ultrasound findings showed a suspicious malignant ovarian mass. On gynecological examination, an obvious fragile exophytic mass was observed in the cervix which resulted in diffuse enlargement of the cervix without parametrial involvement. The gynecologist requested ultrasonography imaging without a pelvic examination. According to the obtained results, an 8 cm solid multicystic adnexal mass was detected as a suspected ovarian malignancy. In addition, based on the results of the patient's examination, the presence of a large cervical mass was detected and the patient underwent cervical biopsy. The findings of clinically suspicious looking cervix resulted in the possible diagnosis of stage IB2 of cervical cancer.

On the other hand, the computed tomography scans demonstrated a bulky mass in the uterine cervix with no other sites of metastases (Figure 1). According to the radiological and clinical findings, the initial diagnosis was cervical cancer (FIGO stage IB2).

Surprisingly, the pathological report of the patient's cervical biopsy revealed non-Hodgkin's diffuse B cell lymphoma. Immunohistochemical studies demonstrated that CD-20 and LCA were intensely positive. However, there was negative staining for CK, CD 3, CD 10, Tdt, human



Imaging revealed :
mass infiltrating uterine cervix

Imaging findings: Mass infiltration of uterine cervix

Figure 1. Diagnostic ultrasonography and computed tomography scan demonstrated a bulky mass in the uterine cervix with no other site of metastasis

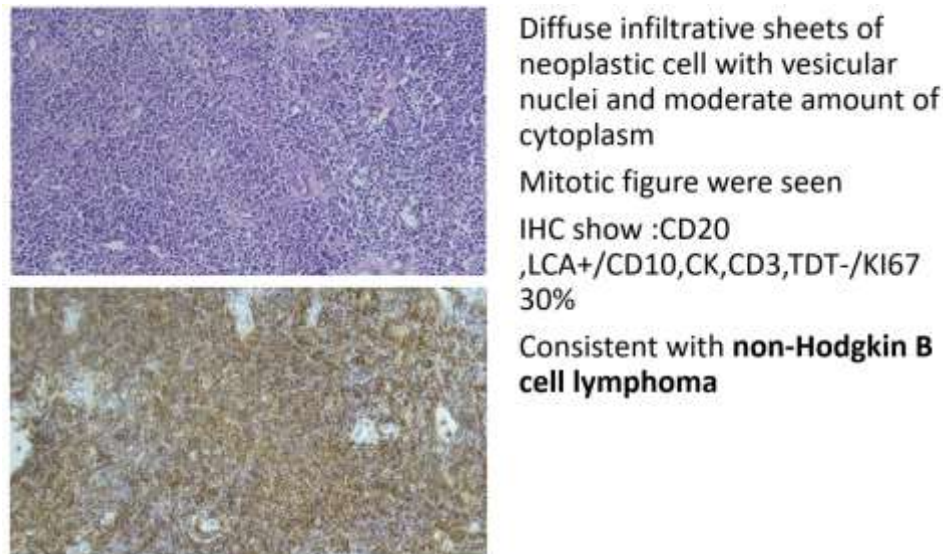


Figure 2. Pathological report and immunohistochemistry findings

papillomavirus (HPV), and Epstein-Barr virus (EBV). Moreover, the positive rate of the Ki67 index was obtained at 30% (Figure 2). As a result, the definitive diagnosis was non-Hodgkin's B cell lymphoma of the cervix and the tumor was classified as stage IE.

Therefore, the therapeutic protocol was CHOP chemotherapy plus rituximab every 3 weeks for 6 cycles. After 18 months of close surveillance, the patient was in good condition without any relapse. The written informed consent was obtained from the patient for the publication of this case report and accompanying images.

Discussion

Lymphoma of the female genital tract is a rare condition. Before any lymph node detection, tumor involvement of other sites was found in the majority of patients at the time of diagnosis, which is known as extralymphatic invasion (stage IE) that was similar to our case.

Although the age at presentation ranges from 20 to 80 years, the median age was closer to 40-60 years (8). The most common clinical presentations are abnormal vaginal bleeding, vaginal discharge, perineal discomfort, and dyspareunia. Moreover, the patients may also be presented with an asymptomatic pelvic mass (9).

Cervical erosion, nodules in the Pouch of

Douglas (cul de sac), and contact bleeding can be detected on pelvic examination. However, friable exophytic lesions can be obviously palpable (10). In addition, the infiltration of the tumor within the cervical stroma is not common. As a result, specific cytological diagnosis of primary malignant lymphoma of the uterine cervix with Pap smear is considered less useful and is commonly negative (59%) (11). Moreover, this type of cancer is rarely diagnosed by cervical screening, because it originates in the cervical stroma, and the overlying squamous epithelium is usually remained unaffected (12). The differential diagnosis of this malignancy includes precancerous lesions, HPV, EBV, and associated lymphoma, such as lesions of the cervix, small cell carcinoma of the cervix, endometrial stromal sarcoma, and granulocytic sarcoma (13). Immunohistochemistry (IHC) is a routinely used methodology that is useful for correct diagnosis. Accordingly, due to the wide range of IHC staining methods that are currently available on paraffin sections, the definitive diagnosis of these tumors is broadly accessible.

The most common definition of the immunohistochemical profile is positivity of LCA, vimentin, CD20, CD30, Bcl6, Bcl2, IgMk, and Ki-67 index as well as the negativity of CD10, MUM1, and BCL2. All of the above-mentioned markers are pivotal in the subcategorization of

PCL (14, 15). In the present case, IHC studies of CD-20 and LCA were intensely positive. However, the staining for CK, CD 3, CD 10, Tdt, HPV, and EBV were negative. In contrast, the Ki-67 index was positive. The best standard treatment option for primary malignant lymphoma of the uterine cervix should be directed to the individual person; however, surgery, chemotherapy, or radiotherapy are the therapeutic choices. The CHOP chemotherapy regimen with or without rituximab has been shown to be effective in the improvement of the survival rate (16). A combined chemotherapy regimen, such as CHOP has proven to be an effective treatment for this disease due to its advantages regarding the prevention of micrometastasis and fertility preservation (17).

The present patient also received CHOP chemotherapy. The primary treatment of patients with cervical lymphoma who undergo chemotherapy has led to favorable prognosis which results from early detection of the disease. In addition, a 5-year survival rate of 81% was estimated in case of detection of early-stage disease (18). However, in a study conducted by Stroh et al. on 16 cases of primary malignant lymphoma of the uterine cervix, 5-year disease-free survival rate was obtained at 90% (7).

Some other reports achieved similar results (19). Heredia et al. reported two cases of cervical lymphoma treated with CHOP and radiotherapy. In the mentioned study, one case had 61 months of disease-free survival after the initial diagnosis and the other one benefited from 15-months relapse-free survival (19). The clinical appearance of primary cervical lymphoma of the cervix often mimics squamous cell carcinoma. Therefore, cytology may be non-contributory to achieve a correct diagnosis. Consequently, careful history taking and pelvic examination are important.

Conclusion

A pelvic examination in patients with vaginal bleeding, vaginal discharge, and pelvic discomfort should be considered as the first step after taking the patient's medical history.

Acknowledgments

We would like to acknowledge the staff of the

Gynecology Oncology department of Gahem Hospital of Mashhad University of Medical Sciences.

Conflicts of Interest

The authors declare no conflicts of interest.

References

1. Calli AO, Rezanko T, Yigit S, Payzin B. Lymphoma of the cervix: a diagnostic pitfall on cervicovaginal smear. *Journal of Cytology/Indian Academy of Cytologists*. 2012; 29(3):213.
2. Hilal Z, Hartmann F, Dogan A, Cetin C, Krentel H, Schiermeier S, et al. Lymphoma of the cervix: case report and review of the literature. *Anticancer Research*. 2016; 36(9):4931-4940.
3. Kosari F, Daneshbod Y, Parwaresch R, Krams M, Wacker HH. Lymphomas of the female genital tract: a study of 186 cases and review of the literature. *The American Journal of Surgical Pathology*. 2005; 29(11):1512-1520.
4. Park SB, Lee YH, Song MJ, Cho HC, Lee MS, Hong SR, et al. Sonographic findings of uterine cervical lymphoma manifesting as multinodular lesions. *Clinical Imaging*. 2012; 36(5):636-638.
5. Armitage JO. Staging non-Hodgkin lymphoma. *CA: A Cancer Journal for Clinicians*. 2005; 55(6): 368-376.
6. Cubo AM, Soto ZM, Cruz MÁ, Doyague MJ, Sancho V, Fraino A, et al. Primary diffuse large B cell lymphoma of the uterine cervix successfully treated by combined chemotherapy alone: a case report. *Medicine*. 2017; 96(19):e6846.
7. Stroh EL, Besa PC, Cox JD, Fuller LM, Cabanillas FF. Treatment of patients with lymphomas of the uterus or cervix with combination chemotherapy and radiation therapy. *Cancer*. 1995; 75(9): 2392-2399.
8. Yalta T, Taştekin E, Puyan FÖ, Usta U, Azatçam M, Altaner Ş. Non-Hodgkin's lymphoma: a rare diagnosis on cervicovaginal cytology. *Journal of Cytology/Indian Academy of Cytologists*. 2012; 29(2):142.
9. Mouhajir N, Diakit  A, Toulba A, Hemmich M, Saadi I, Elkacemi H, et al. Primary non-Hodgkin's lymphoma of the uterine cervix: case report of long-term survival patient. *The Journal of Obstetrics and Gynecology of India*. 2014; 64(1):145-147.
10. Frey NV, Svoboda J, Andreadis C, Tsai DE, Schuster SJ, Elstrom R, et al. Primary lymphomas of the cervix and uterus: the University of Pennsylvania's experience and a review of the literature. *Leukemia & Lymphoma*. 2006; 47(9): 1894-1901.
11. Chandy L, Kumar L, Dawar R. Non-Hodgkin's

- lymphoma presenting as a primary lesion in uterine cervix: case report. *Journal of Obstetrics and Gynecology Research*. 1998; 24(3):183-187.
12. Dursun P, Gultekin M, Bozdogan G, Usbutun A, Uner A, Celik NY, et al. Primary cervical lymphoma: report of two cases and review of the literature. *Gynecologic Oncology*. 2005; 98(3):484-9.
 13. Anagnostopoulos A, Mouzakiti N, Ruthven S, Herod J, Kotsyfakis M. Primary cervical and uterine corpus lymphoma; a case report and literature review. *International Journal of Clinical and Experimental Medicine*. 2013; 6(4):298.
 14. dos Santos LV, Lima J, Lima CS, Sasse EC, Sasse AD. Is there a role for consolidative radiotherapy in the treatment of aggressive and localized non-Hodgkin lymphoma? A systematic review with meta-analysis. *BMC Cancer*. 2012; 12(1):288.
 15. Ahmad AK, Hui P, Litkouhi B, Azodi M, Rutherford T, McCarthy S, et al. Institutional review of primary non-Hodgkin lymphoma of the female genital tract: a 33-year experience. *International Journal of Gynecological Cancer*. 2014; 24(7):1250-1255.
 16. Regalo A, Caseiro L, Pereira E, Cortes J. Primary lymphoma of the uterine cervix: a rare constellation of symptoms. *Case Reports*. 2016; 2016:bcr2016216597.
 17. Hariprasad R, Kumar L, Bhatla DN, Kukreja M, Papaiah S. Primary uterine lymphoma: report of 2 cases and review of literature. *American Journal of Obstetrics and Gynecology*. 2006; 195(1):308-313.
 18. Kojs ZJ, Niemiec M, Papuga-Fujak B, Kojs-Pasińska E, Sawicki W. Primary diffuse large B-cell lymphoma of the uterine cervix-case report. *Ginekologia Polska*. 2016; 87(4):318-320.
 19. Heredia F, Bravo M, Pierotic M, Majlis A, Carmona L. Neoadjuvant combined chemotherapy followed by external whole pelvic irradiation in two cases of primary extranodal non-Hodgkin's lymphoma of the uterine cervix. *Gynecologic Oncology*. 2005; 97(1):285-287.