



Comparison of 2 Methods of Acromioclavicular Joint Dislocation Fixation With Both Row Screw and Hook Plate

Kamyar Aefinar¹, Ali Sadighi¹, Hossein Aslani¹

Abstract

Objectives: Acromioclavicular joint (ACJ) dislocation is one of the most common shoulder injuries, especially in young and athletes, which has a significant effect on a patient's function. Therapeutic strategies include non-surgical and a variety of surgical methods. Each of the 2 therapies has some advantages and disadvantages and careful decision making regarding the appropriate therapeutic approach in these patients has not been achieved due to controversial results. Standard surgical treatment is not specified as well. In this regard, the present study was conducted to compare both row screw and hook plate.

Materials and Methods: In this retrospective cohort study, 68 patients were enrolled after referring to the Shohada Medical Education Center of Tabriz during 2014-2017 with the dislocation of the 4th, 5th, and 6th grade ACJ dislocation. In this study, 44 and 24 patients underwent open reduction and internal fixation with a screw and a hook plate, respectively. The retest workers, and the shoulder range of motion (ROM), as well as pain and device failure were compared between the 2 groups.

Results: According to the results, there were no significant differences between 68 patients with acute dislocation of ACJ type 4, 5, and 6 in terms of work time and pain intensity in the 2 groups ($P=0.78$ and $P=0.29$), but in the examination of ROM, abduction, forward flexion, and external rotation had significantly higher limitations in hook plate compared to the screw ($P=0.03$, $P=0.001$, and $P=0.02$). The maximum motion limitation was observed in shoulder abduction, but the internal rotation between the 2 groups was not significantly different. Eventually, the device failure rate for the screw was significantly higher and approximately 18.4% whereas there was no device failure in hook plate fixation.

Conclusions: Based on the present results regarding acromioclavicular dislocation, surgical treatment using a screw showed better functional improvement in comparison to the hook plate although the probability of device failure was higher.

Keywords: Acromioclavicular dislocation, Hook plate, Screw, Device failure, Range of motion

Introduction

Damage to acromioclavicular joint (ACJ) is common, especially in people under the age of 30 years, but its real incidence is unknown because some affected patients do not refer to the hospital for treatment. The risk of these types of damage can be increased in sportsmen who participate in contact exercises such as soccer, horse-riding, hockey, rugby, and martial arts (1,2).

The ACJ is known as a diarthrodial link that is stabilized by several ligaments. The capsular ligaments of the ACJ provide most of the stability of the joint in the anterior-posterior direction. Contrarily, the "coracoclavicular (CC) ligaments" provide vertical stability (1,3). The usual mechanism of AC and CC ligament trauma is a straight force that is applied on the superior surface of the acromion. In addition, it is generally the result of a decline with the arm in an adducted position (4). Finally, epiphyseal separation with an AC ligament sprain in children and young adults, also the fractures of the clavicle in distal, can result in CC dislocation on radiographs. These are called "AC joint pseudo-dislocations" (1).

The treatment goal of the dislocation of the ACJ is to return the patient to the level of pre-injury activity with a strong, painless, and mobile shoulder. Therefore, the ACJ treatment is one of the most controversial areas. Further,

the classification of this damage is based on the amount and pattern of displacement that, according to Rockwood, is divided into six types (5,6).

Non-surgical and surgical treatments are used in type I and II, as well as type IV to VI injuries, respectively. However, there is a wide discrepancy regarding the appropriate treatment for type III injuries, which has recently increased the tendency to surgical treatment (7).

More than 100 different surgical techniques have been proposed for treating ACJ dislocation (8). Despite all the studies done to treat ACJ dislocation, the ideal treatment is still in dispute. There are several options for optimal surgical treatment for ACJ dislocation, which has progressed remarkably in recent years. These methods include pin joint fixation, open reduction and fixation with a screw, muscle transfer, the posterior clavicle reconstruction and fixation of coracoclavicular with a large screw, the reconstruction of the coracoclavicular ligaments, open fixation with the hook plate, and ultimately, arthroscopic repair. However, none of the above methods is a golden standard for treatment and each has some disadvantages and benefits (9-11).

Considering the importance of the issue, the present study compared the results of 2 methods of fixation with a hook plate and screw in Shohada Hospital, the Northwest

Orthopedic Reference Center in order to take a step toward choosing a better method for treating the patients.

Materials and Methods

The target population in this retrospective cohort study included those who were referred to the emergency department of Shohada hospital in Tabriz during 2013-2017 due to trauma and ACJ dislocation. In this study, 68 patients were referred to Shohada medical education center of Tabriz from 2013 to 2017 with the dislocation of the 4th, 5th, and 6th types. The patients were enrolled in the study and 44 of them underwent open reduction and fixation with a screw, and 24 patients underwent open reduction and fixation with a hook plate.

Including Criteria

- All ACJ dislocation of type 4, 5, and 6.

Excluding Criteria

- Presence of clavicle bone fracture
- Presence of scapular bone fracture
- ACJ dislocation of type 1 and 2
- Presence of sternoclavicular dislocation
- History of surgery and previous shoulder problems

All patients with ACJ dislocation were hospitalized and received primary care including icepack, sling, and oral pain killers. In all cases, surgery was performed in 1-2 day(s). In the surgical procedure, patients, after general anesthesia, were placed in a semi-sitting position and ACJ was openly reduced with the sober approach under fluoroscopy, followed by performing fixation with a screw or hook plate.

It should be noted that coracoclavicular ligaments were reconstructed for none of the patients. In addition, patients were discharged the day after surgery and returned in 2 weeks to remove sutures and a preliminary examination. After the initial surgery, patients were referred to the clinic under the examination in terms of the range of motion (ROM) and the pain score, and then a special questionnaire was completed after the removal of the device.

The studied variables included age, gender, pain, time to return to work, the amount of device failure, the type of the applied device, and the range of shoulder joint motion. All data were analyzed by SPSS software, version 24 and descriptive statistical methods (i.e., frequency, percentage, and mean ± standard deviation) were used for statistical analysis. The chi-square test was used to compare qualitative findings between the 2 groups and an independent *t* test was applied to compare the findings. In this study, a *P* value of less than 0.05 was considered statistically significant.

Results

The present study evaluated a total of 68 patients with ACJ dislocation, including 44 and 24 patients who were

fixed with a screw (group A) and a hook plate (group B), respectively. Table 1 presents demographic characteristics of the 2 groups. As shown, there is no woman in group B and there was no statistically significant difference between the 2 groups in terms of patient’s age.

The mean device removal time was 8.54 ± 5.17 months and 4.50 ± 1.14 months in groups A and B, respectively, which was significantly faster in group B (*P* <0.001). It should be noted that in 7 cases of group A, the device failure occurred, including 4 cutouts and 3 screw breakage and all incidents, in the first month with 4 and 3 cases were replaced with the hook plate and a new screw, respectively. There was also a screw failure occurrence during the third month, which led to the mere removal of the broken part of the screw.

Noteworthy, there were 2 superficial infections in each of the groups, all of which were treated with oral antibiotics and required no surgical intervention for treatment.

All patients were examined after the removal of the device and wound healing, and the relevant questionnaires were completed as well. The mean time of return to work was 3.63 ± 1.03 months and 3.75 ± 0.88 months in groups A and B, respectively, indicating no statistically significant difference between the 2 groups (*P* = 0.62) in this regard (Figure 1). Regarding the severity of pain in patients after treatment, 59.5% and 50% of patients in groups A and B did not have any pain, respectively. Despite a 9% improvement in painlessness in group A, there was no significant difference (*P* = 0.65) between the 2 groups (Figure 2). However, a significant difference was observed between the 2 groups in terms of the ROM limitation so that the number of unrestricted cases in forward flexion

Table 1. Demographic Features of the Groups

		Group A	Group B	<i>P</i> value
Age (y)		29.2 ±5.2	33.1±6.4	0.12
Gender	Male	32 (72.7%)	24 (100%)	0.006*
	Female	12 (27.3%)	0 (0%)	

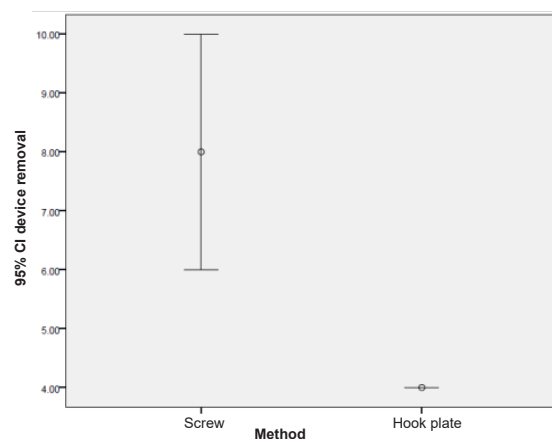


Figure 1. Distribution of Vehicle Departure Time in 2 Groups

was significantly higher in group A ($P = 0.03$) compared to group B (Figure 3).

In this case, abduction without motion limitation and, in fact, with the normal ROM was significantly higher in group A compared to group B ($P < 0.001$). The limits of motion in external rotation were also significantly lower in group A compared to group B ($P = 0.002$). Based on the results, normal ROM in internal rotation in groups A and B were 34 (77.3%) and 21 (87.5%) cases, respectively, and the limitations of 10 degrees in internal rotation were equal to 10 (22.7%) and 3 (12.5%) cases, respectively. Nonetheless, there was no significant difference between the 2 groups regarding internal rotation ($P = 0.35$). The device failure occurred only in 8 cases (18.2%) of group A, which included 4 cutouts and 4 fractures while no ineffectiveness occurred in group B, with a significant difference between the 2 groups ($P = 0.04$), related data are shown in Figures 4 and 5.

Discussion

Dislocation in the ACJ is a very common damage following falling on the shoulder or an overstretched hand. Capsule, conoid, and trapezoid ligaments are injured when the

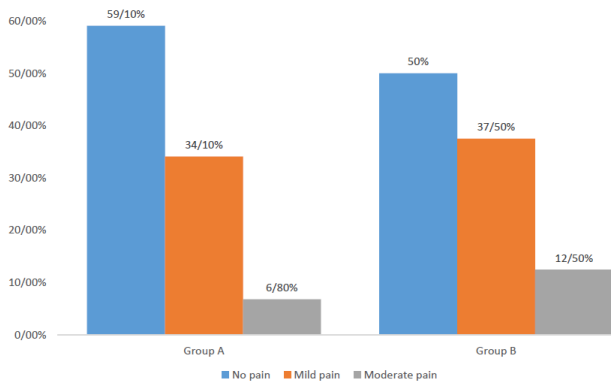


Figure 2. Pain Intensity in 2 Groups.

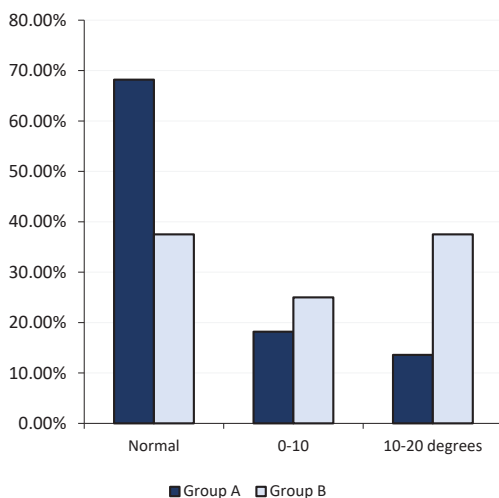


Figure 3. The Extent of Movement Restriction in Forward Flexion in the 2 Groups.

dislocation occurs in the ACJ (12). Fukuda et al showed that conoid and trapezoid ligaments prevent the superior clavicular displacement. Ligament healing is required to guarantee the absence of pain and joint stability, as well as to prevent osteoarthritis (13). Many classifications are available in the literature. The best therapy for complete ACJ is a matter of debate. Various standpat and surgical procedures are available, though most of them require a period of immobilization to allow the healing of the injured tissue before rehabilitation initiation (13). In this study, it was observed that most patients with the dislocation of this joint were males and had a mean age of 30 years (14). The main goals of the treatment of this damage are the complete relief of pain and the complete reversal of

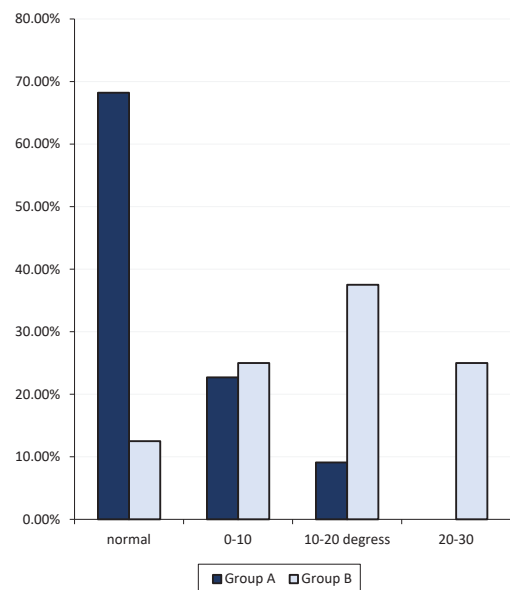


Figure 4. Motor Limitation in Abduction Between the 2 Groups.

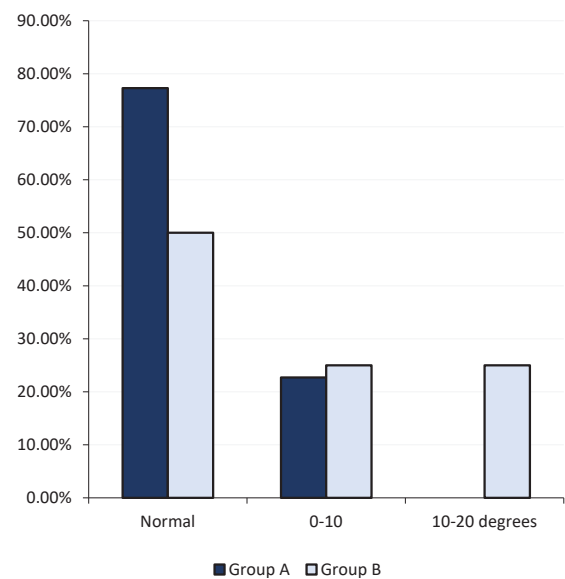


Figure 5. The Evaluation of the Extent of Movement Limitation in External Rotation Between the 2 Groups.

shoulder movements. In this regard, therapeutic strategies include non-surgical and a variety of surgical methods (11). Each of these therapies has some advantages and disadvantages, and thus a careful decision must be made on the appropriate therapeutic approach. Due to controversial results, no study could develop a standard surgical treatment for these patients (15). Therefore, this study sought to compare the results of the 2 surgical methods of fixation with a hook plate and the row screw.

The main therapy of acute ACJ displacement is the restoration of physiological joint biomechanics and the preservation of a ROM and mechanical stability.

According to the results of 68 patients with ACJ dislocation of type 4, 5, and 6, there was no significant difference between the 2 groups with regard to work time and pain intensity, and their *P*-value was 0.78 (group A) and 0.29 (group B). However, in the examinations performed for the limb movement of the patients, abduction limitation, forward flexion, and external rotation were significantly higher in the hook plate compared to the screw, with a *P* value of 0.03, 0.001, and 0.02, respectively. The maximum motion limitation was found in shoulder abduction, but the internal rotation between the 2 groups was not significantly different. Similarly, the device failure rate for the screw was significantly higher and it was 18.4% in the screw group whereas no device failure occurred in the plate fixed group.

Conclusions

Regarding the results of the present study, ACJ dislocations fixed with screw has a significant improvement in functional status and shoulder motion, but the probability of the occurrence of device failure in this method is higher compared to hook plate fixation. Based on the results of this study, surgery is recommended in types 4, 5, and 6 of the ACJ dislocation. In this study, the results of short-term surgical procedures were evaluated in the hook plate and screw. Therefore, further studies with longer follow-up and arthritis examination can provide more accurate results and recommend superior surgical methods.

Conflict of Interests

Authors have no conflict of interests.

Ethical Issues

The present study has been approved by the ethics committee of tabriz university of medical science with registration number [ir.tbzmed.rec 1397.243]. Written informed consent was obtained from all the participants.

Financial Support

The present study has been supported by tabriz university of medical science as residency thesis of orthopedics.

References

1. Boffano M, Mortera S, Wafa H, Piana R. The surgical treatment of acromioclavicular joint injuries. *EFORT Open Rev.* 2017;2(10):432-437. doi:10.1302/2058-5241.2.160085
2. Tomak Y, Desteli EE. Upper limb deformities. In: Çakmak M, Şen C, Eralp L, Balci HI, Melih Civan M, eds. *Basic Techniques for Extremity Reconstruction*. Cham: Springer; 2018:461-492.
3. Lawrence DW, Hutchison MG, Comper P. Descriptive epidemiology of musculoskeletal injuries and concussions in the National Football League, 2012-2014. *Orthop J Sports Med.* 2015;3(5):2325967115583653. doi:10.1177/2325967115583653
4. Geaney LE, Miller MD, Ticker JB, et al. Management of the failed AC joint reconstruction: causation and treatment. *Sports Med Arthrosc Rev.* 2010;18(3):167-172. doi:10.1097/JSA.0b013e3181eaf6f7
5. Mazzocca AD, Arciero RA, Bicos J. Evaluation and treatment of acromioclavicular joint injuries. *Am J Sports Med.* 2007;35(2):316-329. doi:10.1177/0363546506298022
6. Cox JS. Current method of treatment of acromioclavicular joint dislocations. *Orthopedics.* 1992;15(9):1041-1044.
7. Scadden JE, Richards R. Intramedullary fixation of Neer type 2 fractures of the distal clavicle with an AO/ASIF screw. *Injury.* 2005;36(10):1172-1175. doi:10.1016/j.injury.2005.05.022
8. Hoe-Hansen CE, Norlin R. Intramedullary cancellous screw fixation for nonunion of midshaft clavicular fractures. *Acta Orthop Scand.* 2003;74(3):361-364. doi:10.1080/00016470310014319
9. Ngarmukos C, Parkpian V, Patradul A. Fixation of fractures of the midshaft of the clavicle with Kirschner wires. Results in 108 patients. *J Bone Joint Surg Br.* 1998;80(1):106-108. doi:10.1302/0301-620x.80b1.7880
10. Chuang TY, Ho WP, Hsieh PH, Lee PC, Chen CH, Chen YJ. Closed reduction and internal fixation for acute midshaft clavicular fractures using cannulated screws. *J Trauma.* 2006;60(6):1315-1320. doi:10.1097/01.ta.0000195991.80809.a6
11. Hatch RL, Rosenbaum CI. Fracture care by family physicians. A review of 295 cases. *J Fam Pract.* 1994;38(3):238-244.
12. De Baets T, Truijien J, Driesen R, Pittevels T. The treatment of acromioclavicular joint dislocation Tossy grade III with a clavicle hook plate. *Acta Orthop Belg.* 2004;70(6):515-519.
13. Fukuda K, Craig EV, An KN, Cofield RH, Chao EY. Biomechanical study of the ligamentous system of the acromioclavicular joint. *J Bone Joint Surg Am.* 1986;68(3):434-440.
14. Stein BE, Wiater JM, Pfaff HC, Bigliani LU, Levine WN. Detection of acromioclavicular joint pathology in asymptomatic shoulders with magnetic resonance imaging. *J Shoulder Elbow Surg.* 2001;10(3):204-208. doi:10.1067/mse.2001.113498
15. Cook JB, Shaha JS, Rowles DJ, Bottoni CR, Shaha SH, Tokish JM. Early failures with single clavicular transosseous coracoclavicular ligament reconstruction. *J Shoulder Elbow Surg.* 2012;21(12):1746-1752. doi:10.1016/j.jse.2012.01.018