



# Neurological Manifestation of COVID-19: A Literature Review

Arash Azhideh<sup>1</sup>, Iman Menbari-Oskouie<sup>2\*</sup>, Maryam Yousefi-Asl<sup>3</sup>

<sup>1</sup>The Functional Neurosurgery Research Center, Shahid Beheshti University of Medical Sciences, Tehran, Iran.

<sup>2</sup>Faculty of Medicine, Tehran University of Medical Sciences, Tehran, Iran.

<sup>3</sup>Faculty of Medicine, Shahid Beheshti University of Medical Sciences, Tehran, Iran.

## Abstract

In December 2019, the coronavirus ((COVID-19) outbreak related to severe acute respiratory syndrome (SARS-CoV2) originated in China and expanded exponentially as a public health pandemic to over 200 countries. Over 8 million validated cases and approximately 800 000 deaths. The main type is cardiac and respiratory but neurological symptoms are further mentioned as case series and case records in the research. The most frequent manifestations have been reported to include dizziness and headache followed by delirium and encephalopathy. Gillian barre syndrome, acute transversal myelitis, cerebrovascular accident, and encephalitis are among the complications noted. The most prominent occurrence at the periphery was hyposmia. This is also known that neurological demonstrations will also lead to regular features such as cough and fever, which evolve in these cases later on normal manifestations. For the timely diagnosis and separation of cases, therefore, a great suspicion guide is needed to arrest spread in neurology departments. This research provides a narrative study of COVID-19's neurological symptoms and complexities. Our goal is to inform the neurologists and clinicians who work amidst potential COVID-19 patients regarding potential neurological symptoms, and likely neurological problems arising from the aforementioned new virus.

**Keywords:** COVID-19; Neurology; Nervous system; SARS-CoV-2, Stroke.

## \*Correspondence to

Iman Menbari-Oskouie,  
Faculty of medicine, Tehran  
University of Medical Sciences,  
Tehran, Iran.  
Tel: +989388747851,  
Email: Imanmenbary@gmail.  
com

Published online 28 September,  
2020



**Citation:** Azhideh A, Menbari-Oskouie I, Yousefi-Asl M. Neurological Manifestation of COVID-19: A Literature Review. Clin Neurosci J. 2020;7(4):164-170. doi:10.34172/icnj.2020.20.

## Introduction

In December 2019, the new noronavirus (COVID-19) burst occurred in China.<sup>1,2</sup> Chinese governments announced new undetermined etiology subjects of pneumonia.<sup>3</sup> At first, all patients were concentrated into the wholesale market of Wuhan seafood. It was reported a pandemic by the World Health Organization (WHO), on 11 March 2020. There are far beyond 8 million validated COVID-19 cases beside 700,000 deaths worldwide as of August 16, 2020.<sup>4,5</sup>

COVID-19 created a vast deal of importance amid researchers, scientists, and physicians around the world.<sup>6</sup> The volume of work being performed and the quantity of papers written on COVID-19 is unparalleled. Hundreds of manuscripts were estimated to be published upon this subject from the beginning of the year.<sup>7</sup> Data have begun to emerge on various features of prevention, transmission, pathology, disease manifestations, and management strategies.<sup>8-10</sup> Although COVID-19 has a beneficial effect on the respiratory and cardiovascular system, many COVID-19 patients are additionally prone to neurological manifestations (such as neuralgia, hypogeusia, dizziness, and headache) and complexities

including acute cerebrovascular diseases, encephalopathy, skeletal muscle injury, and impaired consciousness.<sup>11,12</sup>

We are offering a systematic study of COVID-19's clinical manifestations and complications. They aim to educate the neurologists, and doctors dealing with presumed COVID-19 patients on potential neurological symptoms and the likely neurological problems arising from this novel infection with the virus.

## Literature Search Strategy

We searched PubMed Central, Medline, and Google scholar using the keywords "pandemic", "COVID-19", "neurology", "complications", "SARS-CoV-2", "Coronavirus", and "manifestations". Single English language scripts without time-end were looking. The latest scan of the literature was conducted on August 1st, 2020. It is essential to remember that fresh data are frequently exchanged and so considerably it consists generally of preprints, small case collection, case reports, and part of an article discussing COVID-19 clinical characteristics. Most of the COVID-19 evidence is released from Wuhan city, China.<sup>13</sup> At the time of writing this paper, we were capable to find in-depth hardly 34

full-text papers in English language biomedical paper identifying precisely the complications and neurological features of COVID-19. Figure 1 demonstrate the diagram of how we end up in reviewing of only 34 full-text articles.

**Mechanism of Central Nervous System Aggression**

COVID-19 does not have ample trial evidence accessible, however, it is thought a mutated version of the Middle East respiratory syndrome (MERS) virus and, the severe acute respiratory syndrome (SARS) virus.<sup>14</sup> Consequently it is supposed to perform similarly.<sup>15</sup> Coronaviruses are not mainly neurotropic, so their main aim is the respiratory epithelium. The enzyme-2 receptor (ACE 2) that converts angiotensin is believed to be the purpose receptor for cell adjunction and following internalization. Following the entry within the cell, the SARS-CoV-2 RNA is subsequently translated and replicated in the cytoplasm, the virus is delivered in blood circulation after the development of envelope protein and the inclusion of RNA within it.<sup>16</sup> Therefore it will bind, multiply, and destroy the tissue of the neurons. Animal studies in rats show that severe acute respiratory syndrome (SARS-CoV-2) penetrates the central nervous system (CNS) within a retrograde transference by the cribriform bone or via the olfactory epithelium enters the brain within seven days. Second, disruption of the blood-brain barrier provokes the virus to access the brain right during the viremia phase of the disease. The extra assumed mechanism is the aggression by SARS-CoV-2 of peripheral nerve termini which next reaches the CNS within the linked track to the synapse. Therefore, because COVID-19 has parallels with SARS-CoV-2, this can be concluded that it more fits the corresponding CNS invasion pathways as explained earlier.

**Neuropathological Mechanism of Central Nervous System Impairment**

COVID-19 is likely to result in two mechanisms of neurological damage; hypoxic brain damage and immune-mediated CNS injury.

**Hypoxic Brain Associated Damage**

Uncompromising pneumonia can lead to systemic hypoxia which damages the CNS. The risk factors include hypercarbia, peripheral vasodilatation, anaerobic metabolism with toxic compound accumulation, hypoxia. This can lead to neuronal swelling and brain edema that eventually leads to neurological injury.<sup>9</sup>

**Injury From Immune-Mediated Response**

Principally because of cytokine storms including enhanced levels of inflammatory cytokines and activation of macrophages, T lymphocytes, and endothelial cells, immune-mediated injury. Additional release of interleukins 6 generates activation of the complement and coagulation cascade, vascular leakage, dissemination of intravascular coagulation, and end-organ injury.<sup>17,18</sup>

**Neurological Manifestations of COVID-19**

**General Neurological Manifestations**

Considering the global existence of SARS-CoV-2, it is surprising that no large-scale observational investigations are exploring the presence of the new coronavirus on the CNS. Many different case reports are indicating that some cases show neuropsychiatric virus symptoms such as impaired awareness and encephalopathy; however, these cases are limited by their strength.<sup>19</sup> Since the initiation of the SARS-CoV-2 pandemic, most centers in China have been available from the limited published studies.

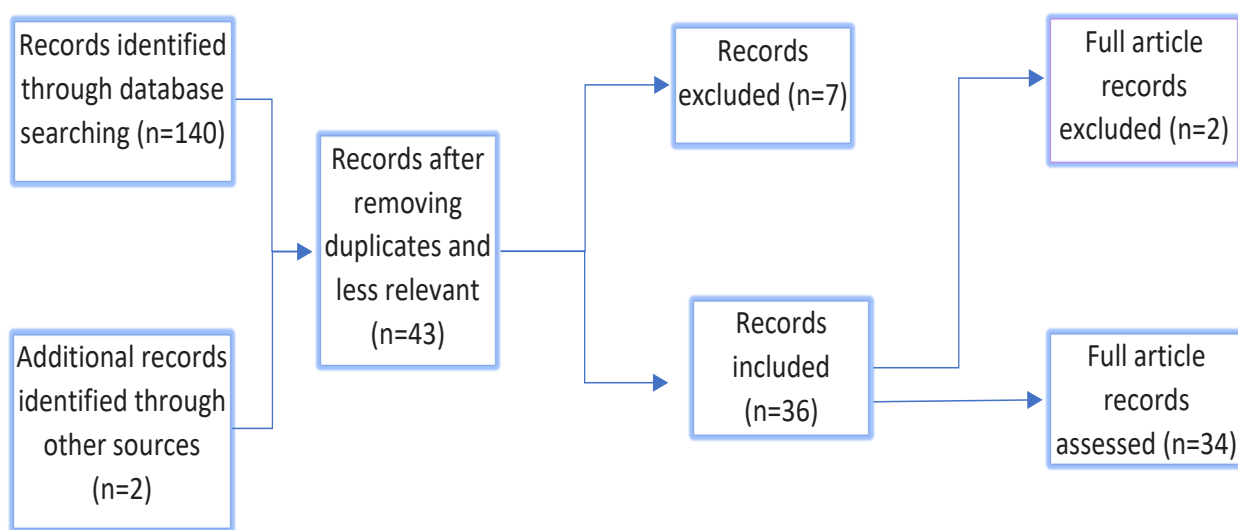


Figure 1. Flow Chart of Article Assessment Through Literature Review.

An early study of 214 hospitalized patients with SARS-CoV-2 from the city of Wuhan, China, indicated that above a third (36.4%) of cases had a range of neurological impairment indicating that the aforementioned could be an understated aspect of the course of the disease.<sup>20</sup> At 3% and 0.5% sequentially, the occurrence of more serious neurological sequelae such as cerebrovascular injuries and seizures was small. This was found that people with “serious” SARS-CoV-2 infections are further expected to experience the neurological problems; nevertheless, the authors did not explain the criteria for discriminating between a severe from non-severe SARS-CoV-2 infection.<sup>14</sup> Figure 2 illustrate the common neurological manifestation of COVID-19.

Ironically, they observed that the greatest neurological symptoms happened beginning in the disease and may serve as a major early indicator of potential clinical worsening. Another related retrospective study by Chen et al from China identified that the symptoms of headache (8%) and confusion (9%) were mentioned by these patients; though, notably, neurological problems were substantially less common than the usual respiratory symptoms of dyspnoea (31%) and cough (82%).<sup>20,21</sup> In a survey of 221 patients, Li et al demonstrated more serious and possibly long-lasting neurological effects of SARS-CoV-2, and 6 percent experienced extreme neurological disorder: cerebral vein thrombosis hemorrhage, ischemic stroke, which resulted in a large proportion of deaths.<sup>11</sup> The neurological complications, signs, and symptoms of COVID-19 can be classified into peripheral and central as discussed in Table 1.

### Central Nervous System Manifestations Encephalopathy

In 40% of cases in their study, Mao et al stated encephalopathy and headache but the specifics and diagnostic tests used were not reported.<sup>11</sup> Filatov et al<sup>19</sup> documented a male patient of a 74-year-old with a past medical history of stroke, atrial fibrillation, Parkinson disease, recent cellulitis, and chronic obstructive pulmonary disease who showed fever to the emergency ward. The initial diagnostic workup did not recommend any dangerous problem and he was released back, home. He came back with more severe symptoms, including fever, headache, and cough. Chest X-ray was pneumonia indicative, while the brain CT scan has not anything special except for symptoms of a past stroke. Polymerase chain reaction (PCR) of the cerebrovascular fluid test revealed the absence of infection. Since suffering respiratory failure, his test was confirmed for COVID-19 and intubated. He began on lopinavir/ritonavir, hydroxychloroquine, and proceeded on antibiotics of a broad range.

Chen et al has reported hypoxic encephalopathy in 20 patients in a retrospective review of the clinical features of 113 COVID-19 cases from China.<sup>20</sup> Among the recovered

**Table 1.** Neurological Manifestation of COVID-19 Categorized by the Site of Involvement

Site	Complications and Manifestations
Central nervous system	Ataxia
	Encephalitis
	Transvers myelitis
	Encephalopathy
	Impaired consciousness
	Epilepsy
	Acute hemorrhagic necrotizing encephalopathy
	Acute cerebrovascular hemorrhage
	Dizziness
	Headache
Peripheral nervous system	Hypogeusia
	Hyposmia
	Neuralgia
	Skeletal muscle injury
	Gillian Barre Syndrome

patients the rate was slightly lower.

### Acute Hemorrhagic Necrotizing Encephalopathy

The initial patient of COVID-19 – induced acute hemorrhagic necrotizing encephalopathy (ANE) from the US was identified by Poyiadji and colleagues.<sup>21</sup> During her late fifties, a female patient had a 3-day history of fever, cough, and altered mental state. The PCR assay was convincing for COVID-19 and negative for West Nile, herpes simplex virus 1 and 2, and *varicella-zoster virus*. For a typical CT venogram, and CT angiogram, the non-contrast brain CT images showed symmetrical hypoattenuation inside the bilateral medial thalami. Magnetic resonance imaging (MRI) brain revealed hemorrhagic surface enhancing lesions in the bilateral thalami, medial temporal lobes, and sub-insular areas. She was initiated on intravenous immunoglobulin (IVIG), but no mention was made of the result. ANE is an unusual complication of these influenza virus infections. The mechanism proposed is expected because of the cytokine storm which ends in blood-brain barrier disturbance and brain parenchyma injury.

### Acute Myelitis

Zhao et al confirmed acute myelitis in a city of Wuhan, a 66-year-old man, who had body aches and fever.<sup>22</sup> He experienced bilateral lower limbs acute flaccid paralysis, the sensory level at T-10 during admission with bowel and urinary incontinence. The PCR test which was taken from the nasopharyngeal tract by a swap was positive for COVID-19 infection and a chest CT scan revealed patchy pneumonia. His serology had been negative for all other organisms.




Figure 2. General Neurological Symptom of COVID-19.

Empirically he has undergone treating with IVIG, hormones, antibiotics, and antivirals. The reaction to the treatment was stable, and he was released for further recovery to an isolation unit. The authors contributed elevated levels of C-reactive protein, serum ferritin, serum amyloid-A, and interleukin-6 which leads to the cytokine storm and over activation of inflammatory reaction. The shortage of cerebrospinal fluid (CSF) PCR for coronavirus and spine MRI due to an outbreak in China is a significant shortcoming of this case study.

#### Cerebrovascular Accident

Sharifi-Razavi et al from Iran described intracranial bleed cases ending in CVA in a 79-year-old positive male COVID-19.<sup>23</sup> In the hospital, he was admitted to a semi-conscious status (Glasgow Coma Scale 7/15) with fever and cough previous history. Two-sided extensor plantar response with harsh crepitation in lower left zones was assessed. PCR nasopharyngeal secretion assay for COVID-19 was successful. A chest CT scan revealed a possible persistence of viral pneumonia in ground glass. A brain CT scan has shown a huge intraventricular and subarachnoid extension bleeds within the right hemisphere. This man was not a known hypertensive, nor was he on any anticoagulants that could have triggered this incident. On admission the platelets and the prothrombin time (PT)/international normalized ratio (INR) were regular. The authors hypothesized that possibly dysregulation in the reception tors of ACE-2 may have resulted in the bleeding of cerebral autoregulation, sympathy-adrenal system, and cerebral blood flow. Another thing that's hard to understand is the nearly normal blood pressure at the time of admittance in this case. Mao et al in their cohort of 214 reported 6 CVA cases (5 ischemic cases and 1 hemorrhagic stroke).<sup>11</sup>

A French cohort study with three cases of ischemic strokes that were observed on neuroimaging when encephalopathy imaging was undertaken by patients.<sup>12</sup> The patients lacked focal neurological signals. The signs

have possibly been obscured due to the existence of encephalopathy, though it highlights the significance of neuroimaging in determining these cases. But there is a need for more evidence to determine a causal association within COVID-19 and stroke.

#### Encephalitis

Moriguchi et al primarily documented the validated case of Japanese COVID-19 associated viral encephalitis.<sup>24</sup> A present 24 years old gentleman with fever accompanied by coma and unconsciousness. He had stiffness of the neck and had a normal CT scan brain. Patchy pneumonia was present on the CT chest. The nasopharyngeal swab PCR assay was negative but COVID-19 was positive with the CSF sample. The diffusion-weighted images (DWI) showed hyperintensity along the right lateral ventricle lower horn wall. Hyperintense sign alterations in the right mesial temporal lobe and hippocampus with mild hippocampal atrophy were seen primarily on the hippocampus and right mesial lobe. There was no enhancement from post-contrast. The authors assumed that the conclusions of the imaging indicated encephalitis and right lateral ventriculitis. This patient and presentation will warn clinicians about COVID-19's neuroinvasive potential and similar presentation of encephalitis.

#### Dizziness and Headaches

Dizziness and headaches are a symptom of many diseases which is not clear and mild. They have been identified as mild symptoms correlated with COVID-19 being described in several studies. The incidence increases<sup>25-27</sup> from 3% to 12.1%. In none of these studies, the exact mechanism and pathophysiology are presented.

#### Peripheral Nervous System Manifestations and Complications

##### Chemosensory Dysfunction and Anosmia

Applying an internet-based cross-sectional questionnaire,<sup>28</sup> Yan et al from the United States reported



chemosensory dysfunction in 59 COVID-19 positives and 203 COVID-19 negative patients from one center. They showed that in COVID-19 positive cases, the odor and taste dysfunction were higher compared to negative cases (Loss of smell: 68% vs. 16%, and loss of taste: 71% vs. 17%). Many of the cases in this investigation were outpatient, they did not need hospitalization and mechanical ventilation was not needed. They theorized that the virus potentially spreads through the nasal route in ambulatory COVID-19 patients relative to critically ill patients where the spread is most convincing pulmonary. Bagheri et al published results of a broad Iranian cohort study of 10 069 patients using a survey focused on on-line questionnaires.<sup>29</sup> Lately (in the last 40 weeks of the COVID-19 outbreak in Iran) participants have been cases with issues with a reduced sense of smell. 48.23 percent of respondents reported anosmia and hyposmia while 83.38% also had a reduced sense of taste. Anosmia unexpectedly started at 76.24%. Certain clinical characteristics identified by the cooperators were pre-anosmia cold or flu symptoms (75.5%), fever (37.3%), nasal stiffness (43.7%), and headaches (48.6%). In comparison, Mao and colleagues' study of 214 Chinese patients in their cohort recorded taste impairment in 12 (5.6%) and smell impairment in 11 (5.1%) patients. The French cohort study of COVID-19 cases did not confirm anosmia and taste dysfunction.<sup>11</sup>

### *Guillain-Barre Syndrome*

Eight patients of Guillain-Barre syndrome (GBS) associated with COVID-19 have so far been published from Wuhan, China, Italy, and Iran. In a 61-year-old woman who had traveled to Wuhan city, China, Zhao et al published the first case of GBS.<sup>30</sup> She had acute fatigue in both legs and extreme tiredness, improving within 1 day. Electromyography (EMG) and nerve conduction studies (NCS) are indicative of polyneuropathy demyelination. She underwent treatment with IVIG, and the respiratory problems emerged later. Her nasopharyngeal PCR test was positive for COVID-19. She transmitted the virus to two of her relatives and eight others including two neurologists and six isolated nurses who were found positive for COVID-19. The investigator assumed that a para-infectious model of GBS due to COVID-19 is consistent with the thrombocytopenia, travel history, and lymphopenia at the time of entry. Upon isolating and administering the antivirals, she made a successful motor recovery.

Sedaghat and Karimi published Iranian diabetes patients of a 61-year-old male.<sup>31</sup> Two weeks before presenting with ascending paralysis presented with bilateral facial paralysis and quadriplegia, he had a fever, cough, and occasionally dyspnea. EMG/NCS was indicative of sensory-axonal acute motor neuropathy. He had been operated by IVIG. The authors proposed that GBS should

be thought a COVID-19 neurological complexity as the normal respiratory function in COVID-19 and may be a risk factor for GBS growth. Virani and colleagues published GBS in an American male of 54-years.<sup>32</sup> He presented with quickly advancing distally to proximal paralysis starting the difficulty of breathing. There were no dysfunctions in the bladder or intestine. No reflexes and the spine were natural for MRI.

He had a past medical history of diarrhea that followed an intense weakness attack. He screened COVID-19 for positive. He was treated with anti-malarial and IVIG. He replied well, and the ventilator was detached. He was moved to a physical therapy rehabilitation center.

Five GBS patients from northern Italy were documented in Toscano et al.<sup>33</sup> The major presenting characteristics in four patients were lower-limb paresthesia and weakness, accompanied by ataxia, paresthesia, and facial weakness in one patient. Four had positive PCR at the initial visit from the nasopharyngeal swab and fifth was initially negative but later turned positive. Patients with demyelinating polyneuropathy had features on NCS/EMG 02 while three had axonal polyneuropathy. All the patients have had IVIG therapy. This was replicated in 2 patients, and plasma was traded for one patient. Just one subject was able to ambulate spontaneously after one week and was released from the hospital. To confirm this classic relationship amid COVID-19 and GBS further large-scale studies are needed.

### *Skeletal Muscle Damage*

In 17 (19.3%) cases in the seriously ill and 6 (4.8%) cases in the non-severe category,<sup>11</sup> Mao et al reported skeletal muscle lesion. Skeletal muscle damage was identified as a subject with raised serum creatine kinase level beyond 200 U/L and myalgia. Researchers settled that it was not obvious whether this was due to the direct muscle tissue effect of the virus or other subsequent reasons. Another potential mechanism suggested was the infection-mediated immune response that induced raised serum pro-inflammatory cytokines resulting in damage to the skeletal muscles.<sup>34,35</sup> It should be remembered, however, that in addition to increased muscle enzymes, patients in the seriously ill the community also had raised liver enzymes and disordered renal functions that may have driven to this clinical feature.<sup>36,37</sup> Besides, no clear confirmatory diagnostic study such as NCS/EMG or muscle cell histopathology has been done.<sup>38</sup> Therefore it is difficult to exclude that in addition to skeletal muscle injury, these patients may have essential disease myopathy and neuropathy.

### **Conclusion**

COVID-19 fundamentally alters the function of cardiovascular and respiratory systems. Neurological impairments, however, is not rare and can lead to severe

complexities if not identified and handled quickly. Such complications are often seen in cases with a serious disease and can also precede the respiratory symptoms in some cases or even maybe the solitary symptoms in COVID-19 subjects. Consequently, when dealing with these cases, a great index of mistrust is needed for immediate treatment and prevention. It is further necessary to regularly collect data from various parts of the world on long and short-term neurological complications and to track the practical outcomes of these complexities.

#### Conflict of Interest

The authors declare that they have no conflict of interests.

#### Ethical Statement

Not applicable.

#### References

- Zhu N, Zhang D, Wang W, Li X, Yang B, Song J, et al. A novel coronavirus from patients with pneumonia in China, 2019. *N Engl J Med*. 2020;382(8):727-33. doi: 10.1056/NEJMoa2001017.
- Green A. Li wenliang. *Lancet*. 2020;395(10225):P682. doi: 10.1016/S0140-6736(20)30382-2.
- World Health Organization (WHO). Pneumonia of Unknown Cause – China. WHO; 2020. 5 January 2020; Available at: <https://www.who.int/csr/don/05-january-2020-pneumonia-of-unknown-cause-china/en/>. Accessed April 22, 2020.
- World Health Organization (WHO). WHO Director-General's Opening Remarks at the Media Briefing on COVID-19. WHO; 2020. Available at: <https://www.who.int/dg/speeches/detail/who-director-general-s-opening-remarks-at-the-media-briefing-on-covid-19---18-september-2020>. Accessed April 22, 2020.
- World Health Organization (WHO). Coronavirus Disease 2019 (COVID-19) Situation Report – 92. WHO; 2020. [https://www.who.int/docs/default-source/coronaviruse/situation-reports/20200421-sitrep-92-covid-19.pdf?sfvrsn=38e6b06d\\_8](https://www.who.int/docs/default-source/coronaviruse/situation-reports/20200421-sitrep-92-covid-19.pdf?sfvrsn=38e6b06d_8). Accessed April 22, 2020.
- World Health Organization (WHO). Global research on Coronavirus Disease (COVID- 19). WHO; 2020. Available at: <https://www.who.int/emergencies/diseases/novel-coronavirus-2019/global-research-on-novel-coronavirus-2019-ncov>. Accessed April 22, 2020.
- Memon AR, Rathore FA. Publishing research during pandemics: are you vulnerable to the COVID-19 or predatory publishers? *J Pak Med Assoc*. 2020;70(Suppl 3)(5):S166-S8. doi: 10.5455/jpma.39.
- Di Gennaro F, Pizzol D, Marotta C, Antunes M, Racalbutto V, Veronese N, et al. Coronavirus diseases (COVID-19) current status and future perspectives: a narrative review. *Int J Environ Res Public Health*. 2020;17(8). doi: 10.3390/ijerph17082690.
- Tu H, Tu S, Gao S, Shao A, Sheng J. Current epidemiological and clinical features of COVID-19; a global perspective from China. *J Infect*. 2020;81(1):1-9. doi: 10.1016/j.jinf.2020.04.011.
- Li X, Geng M, Peng Y, Meng L, Lu S. Molecular immune pathogenesis and diagnosis of COVID-19. *J Pharm Anal*. 2020;10(2):102-8. doi: 10.1016/j.jpha.2020.03.001.
- Mao L, Jin H, Wang M, Hu Y, Chen S, He Q, et al. Neurologic manifestations of hospitalized patients with coronavirus disease 2019 in Wuhan, China. *JAMA Neurol*. 2020;77(6):683-90. doi: 10.1001/jamaneurol.2020.1127.
- Helms J, Kremer S, Merdji H, Clere-Jehl R, Schenck M, Kummerlen C, et al. Neurologic features in severe SARS-CoV-2 infection. *N Engl J Med*. 2020;382(23):2268-70. doi: 10.1056/NEJMc2008597.
- Lou J, Tian SJ, Niu SM, Kang XQ, Lian HX, Zhang LX, et al. Coronavirus disease 2019: a bibliometric analysis and review. *Eur Rev Med Pharmacol Sci*. 2020;24(6):3411-21. doi: 10.26355/eurrev\_202003\_20712.
- Wu Y, Xu X, Chen Z, Duan J, Hashimoto K, Yang L, et al. Nervous system involvement after infection with COVID-19 and other coronaviruses. *Brain Behav Immun*. 2020;87:18-22. doi: 10.1016/j.bbi.2020.03.031.
- Li YC, Bai WZ, Hashikawa T. The neuroinvasive potential of SARS-CoV2 may play a role in the respiratory failure of COVID-19 patients. *J Med Virol*. 2020;92(6):552-5. doi: 10.1002/jmv.25728.
- Baig AM, Khaleeq A, Ali U, Syeda H. Evidence of the COVID-19 virus targeting the CNS: tissue distribution, host-virus interaction, and proposed neurotropic mechanisms. *ACS Chem Neurosci*. 2020;11(7):995-8. doi: 10.1021/acschemneuro.0c00122.
- Mehta P, McAuley DF, Brown M, Sanchez E, Tattersall RS, Manson JJ. COVID-19: consider cytokine storm syndromes and immunosuppression. *Lancet*. 2020;395(10229):1033-4. doi: 10.1016/s0140-6736(20)30628-0.
- Tveito K. Cytokine storms in COVID-19 cases? *Tidsskr Nor Laegeforen*. 2020;140. doi: 10.4045/tidsskr.20.0239.
- Filatov A, Sharma P, Hindi F, Espinosa PS. Neurological complications of coronavirus disease (COVID-19): encephalopathy. *Cureus*. 2020;12(3):e7352. doi: 10.7759/cureus.7352.
- Chen T, Wu D, Chen H, Yan W, Yang D, Chen G, et al. Clinical characteristics of 113 deceased patients with coronavirus disease 2019: retrospective study. *BMJ*. 2020;368:m1091. doi: 10.1136/bmj.m1091.
- Poyiadji N, Shahin G, Noujaim D, Stone M, Patel S, Griffith B. COVID-19-associated acute hemorrhagic necrotizing encephalopathy: imaging features. *Radiology*. 2020;296(2):E119-e20. doi: 10.1148/radiol.2020201187.
- Zhao K, Huang J, Dai D, Feng Y, Liu L, Nie S. Acute myelitis after SARS-CoV-2 infection: a case report. *medRxiv*. 2020. doi: 10.1101/2020.03.16.20035105.
- Sharifi-Razavi A, Karimi N, Rouhani N. COVID-19 and intracerebral haemorrhage: causative or coincidental? *New Microbes New Infect*. 2020;35:100669. doi: 10.1016/j.nmni.2020.100669.
- Moriguchi T, Harii N, Goto J, Harada D, Sugawara H, Takamino J, et al. A first case of meningitis/encephalitis associated with SARS-coronavirus-2. *Int J Infect Dis*. 2020;94:55-8. doi: 10.1016/j.ijid.2020.03.062.
- Huang C, Wang Y, Li X, Ren L, Zhao J, Hu Y, et al. Clinical features of patients infected with 2019 novel coronavirus in Wuhan, China. *Lancet*. 2020;395(10223):497-506. doi: 10.1016/s0140-6736(20)30183-5.
- Deng Y, Liu W, Liu K, Fang YY, Shang J, Zhou L, et al. Clinical characteristics of fatal and recovered cases of coronavirus disease 2019 in Wuhan, China: a retrospective study. *Chin Med J (Engl)*. 2020;133(11):1261-7. doi: 10.1097/cm9.0000000000000824.
- Li LQ, Huang T, Wang YQ, Wang ZP, Liang Y, Huang TB, et

- al. COVID-19 patients' clinical characteristics, discharge rate, and fatality rate of meta-analysis. *J Med Virol.* 2020;92(6):577-83. doi: 10.1002/jmv.25757.
28. Yan CH, Faraji F, Prajapati DP, Boone CE, DeConde AS. Association of chemosensory dysfunction and COVID-19 in patients presenting with influenza-like symptoms. *Int Forum Allergy Rhinol.* 2020;10(7):806-13. doi: 10.1002/alr.22579.
  29. Bagheri SHR, Asghari AM, Farhadi M, Shamshiri AR, Kabir A, Kamrava SK, et al. Coincidence of COVID-19 epidemic and olfactory dysfunction outbreak. *medRxiv.* 2020. doi: 10.1101/2020.03.23.20041889.
  30. Zhao H, Shen D, Zhou H, Liu J, Chen S. Guillain-Barré syndrome associated with SARS-CoV-2 infection: causality or coincidence? *Lancet Neurol.* 2020;19(5):383-4. doi: 10.1016/s1474-4422(20)30109-5.
  31. Sedaghat Z, Karimi N. Guillain Barre syndrome associated with COVID-19 infection: A case report. *J Clin Neurosci.* 2020;76:233-5. doi: 10.1016/j.jocn.2020.04.062.
  32. Virani A, Rabold E, Hanson T, Haag A, Elrufay R, Cheema T, et al. Guillain-Barré syndrome associated with SARS-CoV-2 infection. *IDCases.* 2020;20:e00771. doi: 10.1016/j.idcr.2020.e00771.
  33. Toscano G, Palmerini F, Ravaglia S, Ruiz L, Invernizzi P, Cuzzoni MG, et al. Guillain-Barré syndrome associated with SARS-CoV-2. *N Engl J Med.* 2020;382(26):2574-6. doi: 10.1056/NEJMc2009191.
  34. Radpour A, Bahrami-Motlagh H, Taaghi MT, Sedaghat A, Karimi MA, Hekmatnia A, et al. COVID-19 evaluation by low-dose high resolution CT scans protocol. *Acad Radiol.* 2020;27(6):901. doi: 10.1016/j.acra.2020.04.016.
  35. Sedaghat A, Gity M, Radpour A, Karimi MA, Haghghatkhah HR, Keshavarz E, et al. COVID-19 protection guidelines in outpatient medical imaging centers. *Acad Radiol.* 2020;27(6):904. doi: 10.1016/j.acra.2020.04.019.
  36. Azhideh A. COVID-19 neurological manifestations. *Int Clin Neurosci J.* 2020;7(2):54. doi: 10.34172/icnj.2020.01.
  37. Dehghani Firouzabadi M, Dehghani Firouzabadi F, Goudarzi S, Jahandideh H, Roomiani M. Has the chief complaint of patients with COVID-19 disease changed over time? *Med Hypotheses.* 2020;144:109974. doi: 10.1016/j.mehy.2020.109974.
  38. Dehghani Firouzabadi F, Dehghani Firouzabadi M, Ghalehbaghi B, Jahandideh H, Roomiani M, Goudarzi S. Have the symptoms of patients with COVID-19 changed over time during hospitalization? *Med Hypotheses.* 2020;143:110067. doi: 10.1016/j.mehy.2020.110067.