

RESEARCH ARTICLE

Acute toxicity investigation regarding clinical and pathological aspects following repeated oral administration of iron oxide nanoparticles in rats

Saba Talesh¹, Mohammad Kazem Koohi¹, Ehsan Zayerzadeh^{2,*}, Jalal Hasan¹, Meisam Shabanian³

¹ Department of Basic Sciences, Faculty of Veterinary Medicine, University of Tehran, Tehran, Iran

² Department of Food Toxicology, Food Technology and Agricultural Products Research Center, Standard Research Institute, Karaj, Iran

³ Chemistry and Petrochemistry Research Center, Standard Research Institute, Karaj, Iran

ARTICLE INFO

Article History:

Received 16 August 2019

Accepted 25 October 2019

Published 15 November 2019

Keywords:

Iron oxide nanoparticles

Rat

Pathology

Clinical signs

Toxicity

ABSTRACT

Iron oxide nanoparticles (IONPS) have different practical purposes in nanomedicine. These new applications of IONPS have raised risk of exposure of this nanomaterials to humans. Up to the present, all features of IONPS toxicity are not fully characterized after exposure to animals. The aim of the present study is to investigate the acute toxicity effects of IONPS in laboratory animals regarding pathotoxicological analysis and clinical aspects. Twenty four male Wistar rats were selected, and separated into four groups. The first, second, and the third groups received 50, 500, and 5000 mg/kg of IONPS solution orally for five days through gavage, respectively. Animal mortality, clinical signs and body weight were evaluated during the study. Fourteen days after the last administration, rats were euthanized for further investigation for histopathological evaluation. There were no death observed in all groups. High and middle dose of the IONPS caused symptoms like lethargy, ataxia, anorexia, isolation, and respiratory arrhythmia over the period of the study. The subjects of the low dose group showed no signs of toxicity. Specific histopathological complications, like hyaline cast in the kidneys, hyperemia and interstitial thickening in the lungs, hemorrhage in the heart and hepatic degeneration in the liver were observed in high dose group. Thus, it can be concluded that, toxicity of IONPS in rats is dose-dependent. This particular size of IONPS can induce serious pathological abnormalities and clinical symptoms in high dose.

How to cite this article

Talesh S, Kazem Koohi M, Zayerzadeh E, Hasan J, Shabanian M. Acute toxicity investigation regarding clinical and pathological aspects following repeated oral administration of iron oxide nanoparticles in rats. *Nanomed Res J*, 2019; 4(4): 228-233. DOI: 10.22034/nmrj.2019.04.004

INTRODUCTION

Iron oxide nanoparticles (IONPS), have extensive merits for biomedical applications including targeted delivery of drugs or genes, magnetic transfections, contrast enhancement, chelation therapy and tissue engineering. In addition, they are booster of anticancer drugs and reverse multidrug resistance efficiency. Therefore, they can be used as targeted drug carriers [1-4]. Due to extensive applications of IONPS, exposure of humans and animals to IONPS will be certainly raised significantly in the near future. Nanoparticles

which are engineered may have unknown hazards on human health and the environment. Exposure routes of nanoparticles to humans such as inhalation, ingestion, dermal, and injection have been boosted due to fast development of nanotechnology [5-7]. However, clinical investigation for biosafety evaluation of IONPs is in early stage and it is urgent to determine whether IONPs are safe or not for human health before commercializing these precious nanoparticles. There are a few reports concerning adverse effects and toxicity of the IONPS especially under in vivo

* Corresponding Author Email: zayerzadeh@standard.ac.ir

conditions [8 and 9]. These few studies have some contradicting results as well. For instance, there are reports of the IONPS being non-toxic, mildly toxic, or causing inflammatory responses and even cellular death in some in vivo cases. Some studies have demonstrated administration of IONPS, significantly induced inflammatory reactions in laboratory animals [8, 10, 11, 12, 13]. Furthermore, there is inadequate reliable information regarding pathological abnormalities that may be caused by various sizes of IONPS in animals. Up to our knowledge, there is no investigation about pathological impacts of this size (30 nm) of IONPS in the Wistar rat model with oral route. Therefore, evaluation of the biosafety of this size of IONPS is necessary. In this study, animals were treated with a five days repeated dose oral administration of various doses of IONPS. Animal mortality, histopathological parameters and body weight were analyzed two weeks after treatment.

MATERIALS AND METHOD

Animals and housing conditions

Randomly chosen, and divided into 4 groups of 6 individuals were 24 male Wistar rats, which were acquired from Razi Vaccine and Serum Research

Institute, with a mean weight of 220 ± 22 gr. The rats were then transferred to the animal department of the Research Standard Institute. Animals were taken care with regard to the advice of the animal care committee of the Tehran University based on the 'Guide for Care and Use of Laboratory Animals' (NIH US publication 86-23, revised 1985). The animals were kept in special sanitary cages under suitable new laboratory circumstances for adaptability with 12 hours of light and of darkness at 22 ± 2 degree Celsius, and ad libitum access to water and food.

Iron-oxide nanoparticle preparation

30 nanometers Fe₃O₄ nanoparticles with specific characteristics were bought from the Nanocyl Company (Belgium) and used in our investigation without further purification or sieving (Fig. 1). Then, Fe₃O₄ nanoparticles were added to the normal saline solution, and underwent disperse procedure, using the ultrasonic bath at 4 degree Celsius for 30 minutes.

Animal treatment procedures

Different doses (50, 500, and 5000 mg/kg) of the iron-oxide nanoparticle solution were administered

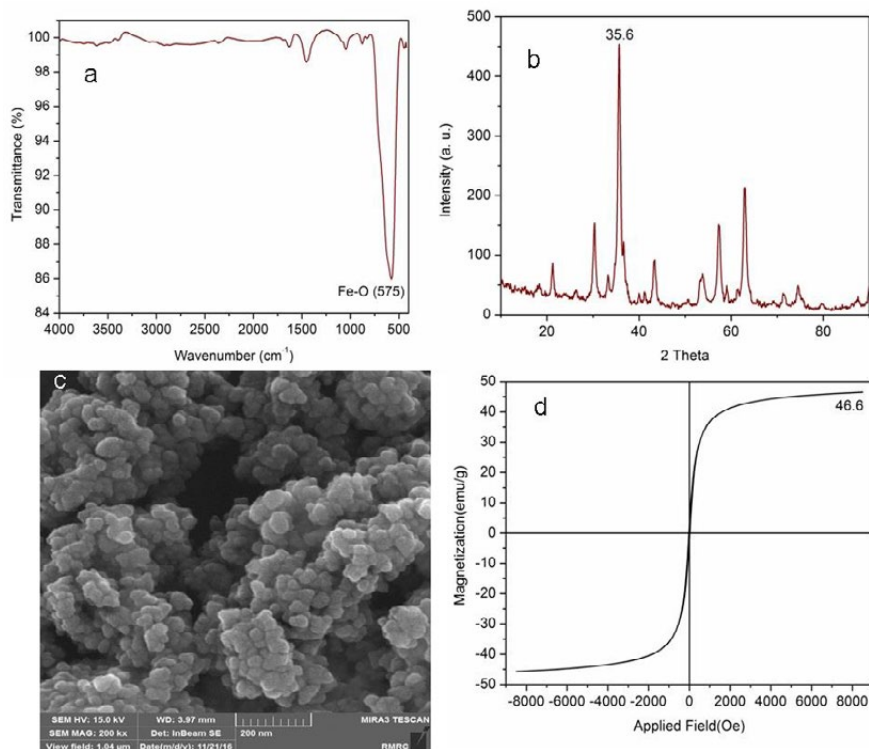


Fig. 1: FT-IR spectrum (a), XRD pattern (b), SEM image (c), and Magnetic properties (d)

orally through gavage to the subjects of the first, second, and the third groups, respectively for five days. The fourth group was considered as control group and took 3ml of normal saline solution. Clinical signs including the appearance, activities, depression, possible trauma, ataxia, death and so forth were evaluated four times in day during dose treatment and for two weeks following the last administration in animals of each group. Then, 14 days after the last administration, rats were euthanized. Animal handling and research procedures were carried out regarding laboratory animal welfare.

Tissue section preparation

To assess the tissues, the animals were euthanized painlessly following the ethical principles of the work. Organs such as heart, lungs, liver, kidneys, spleen and stomach extracted from treated rats were immersed in 10% buffered formalin by 48 hours. After immersion stage, tissues transversely sectioned in 3–4 μm slices. Samples were dehydrated in a graded series of alcohol and xylene. Then, sections were embedded in the paraffin. Multiple slices were produced and stained by hematoxylin and eosin stains. Sections were examined and photographed by a light microscope.

Statistical Analyses

All data are expressed as mean \pm SD. The comparison of parameters mean between groups was performed by the Student's t-test. Analyses of data was done by the SPSS software (version 20) and a $p < 0.05$ is considered statistically significant.

RESULTS AND DISCUSSION

Due to the development of nanotechnology in the recent years and the widespread application of the nanoparticles such as iron-oxide in various industries, including health and food, and the

introduction of such components into living organisms, acute toxicity analysis seems vital to prevent further complications [1-4]. Several pieces of research have been carried out to determine the toxicity of IONPS. In the present study, it was not observed death as a result of the IONPS administration in any group. The high dose administration of IONPS in rats (5000 mg/kg) resulted in toxicity and its subsequent symptoms like lethargy, ataxia, anorexia, depression, and respiratory arrhythmia over the period of the study. The subjects who underwent the middle dose treatment (500 mg/kg) showed minor toxicity with symptoms of lethargy, anorexia, and isolation; however, slighter than the high dose group. The administration of IONPS at a lower dose (50 mg/kg) had no consequent toxicity compared to the control group. However, oral administration of IONPS solution (5000 mg/kg) induced specific pathological complications such as hepatic degeneration in the liver (Fig. 4). Mild hyaline casts were observed in the kidneys (Fig. 5). In addition, moderate hyperemia, interstitial thickening, hemorrhage and severe inflammation occurred in the lungs (Fig. 2). Moderate hemorrhage was also seen in the heart (Fig. 3). There was no pathological injuries witnessed in the spleen and the stomach (Figs. 6 and 7). Classification of pathological perturbations in terms of their severity was emphasized in the Table 1. The middle and low dose administration of the IONPS solution did not induce any pathologic perturbations. At the end of the study, the mean weight of the high dose and middle dose groups was significantly reduced compared to the control group. The severity of weight loss in the high dose group was greater than the middle dose group. There was no significant difference between the mean weight of the low dose group and the control group (Table 2). Iron oxide nanoparticles cause to leak out lactate dehydrogenase of the cell

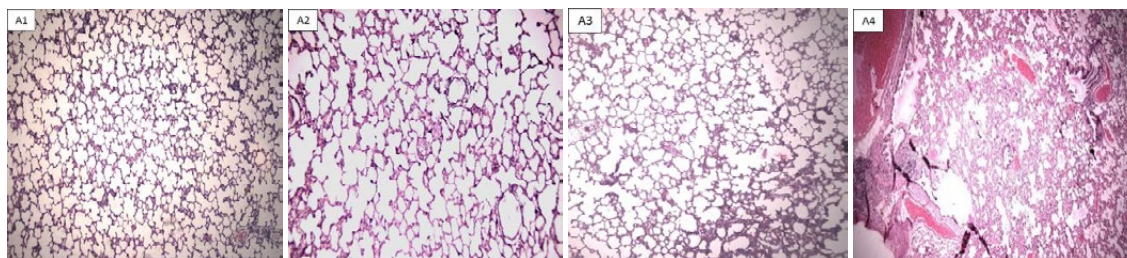


Fig. 2. Photomicrographs of lung sections obtained from rats exposed to different concentrations of IONs. (A2, A3, A4) control rats received 50, 500, 5000 mg/kg of IONs, respectively (A1, A2, A3): normal lung, A4: Hyperemia, interstitial thickening, hemorrhage and inflammation in lungs, (Staining with hematoxylin and eosin). Magnification: 40 x for panels.

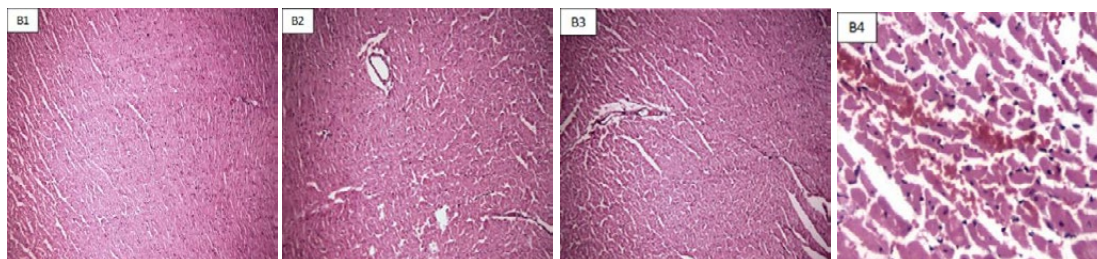


Fig. 3. Photomicrographs of heart sections obtained from rats exposed to different concentrations of IONs. (B2, B3, B4) control rats received 50, 500, 5000 mg/kg of IONs, respectively (B1, B2, B3): normal heart, B4: Hemorrhage in heart, (Staining with hematoxylin and eosin). Magnification: 40 x for panels.

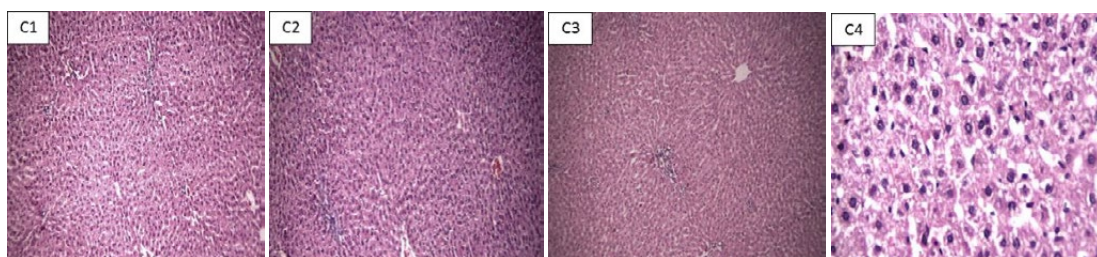


Fig. 4. Photomicrographs of liver sections obtained from rats exposed to different concentrations of IONs. (C2, C3, C4) control rats received 50, 500, 5000 mg/kg of IONs, respectively (C1, C2, C3): normal liver, C4: hepatic degeneration in liver (Staining with hematoxylin and eosin). Magnification: 40 x for panels.

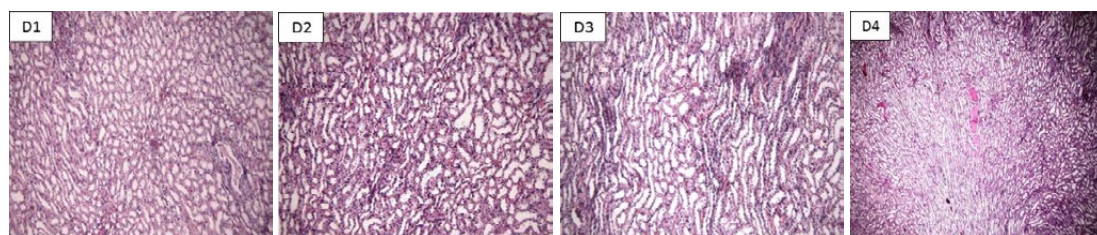


Fig. 5. Photomicrographs of kidney sections obtained from rats exposed to different concentrations of IONs. (D2, D3, D4) control rats received 50, 500, 5000 mg/kg of IONs, respectively (D1, D2, D3): normal kidney, D4: Hyaline casts in kidney (Staining with hematoxylin and eosin). Magnification: 40 x for panels.

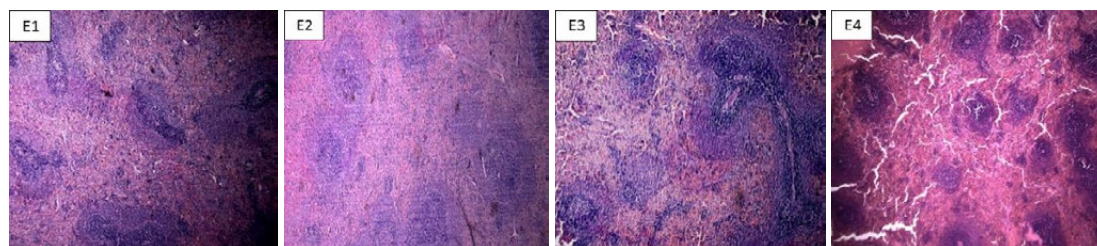


Fig. 6. Photomicrographs of spleen sections obtained from rats exposed to different concentrations of IONs. (E2, E3, E4) control rats received 50, 500, 5000 mg/kg of IONs, respectively (E1, E2, E3, E4): normal spleen, (Staining with hematoxylin and eosin). Magnification: 40 x for panels.

membrane, disturbance of mitochondrial activity, agglomeration of chromosomes, and generation of the ROS. Radical oxygen species imbalance the oxidative stress and disrupt the antioxidant system, resulting in membrane lipid peroxidation,

oxidation of the enzymes and structural proteins, DNA damage, and cell death [14-16]. Najafi et al carried out studies on male Wistar rats through the oral administration of iron oxide and distilled water (20, 50, 150 $\mu\text{g}/\text{kg}$) for 15 days. Degeneration of the

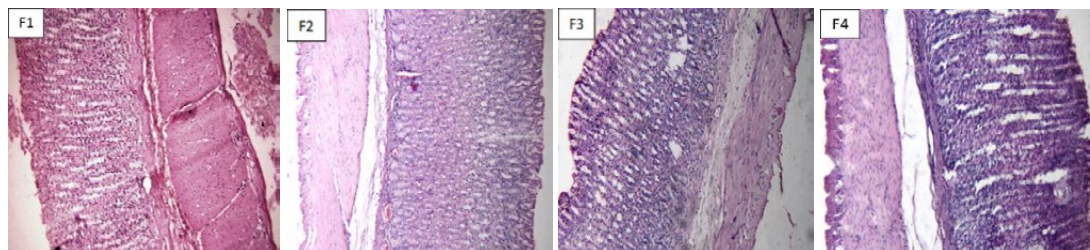


Fig. 7. Photomicrographs of stomach sections obtained from rats exposed to different concentrations of IONs. (F2, F3, F4) control rats received 50, 500, 5000 mg/kg of IONs, respectively (F1, F2, F3, F4): normal stomach, (Staining with hematoxylin and eosin). Magnification: 40 x for panels.

Table 1. Classification of pathological complications following oral administration of IONs (5000 mg/kg) in rats.

organs	pathological complications		
	Mild	Moderate	Severe
Lung	Not seen	Hyperemia, interstitial thickening and hemorrhage	inflammation
Heart	Not seen	Hemorrhage	Not seen
Liver	Not seen	Not seen	hepatic degeneration
Kidney	Hyaline casts	Not seen	Not seen
Spleen	Not seen	Not seen	Not seen
Stomach	Not seen	Not seen	Not seen

Table 2. Body weight following oral administration of IONs (50, 500, 5000 mg/kg) in rats.

Group	Initial weight (gr)	Final weight (gr)	Weight difference (gr)
Control	202±20	251±23	49
High dose	208±22	190±17*	18
Middle dose	204±19	232±20*	28
Low dose	210±20	260±28	50

Mean values ± standard deviation are demonstrated for the six animals in each group.
*significant difference ($p < 0.05$) in comparison with control (first) group.

hepatocytes was reported at 150 µg/kg [17]. Iversen et al reported the effects of intravenous injection of Fe₃O₄ nanoparticles on the liver. The nanoparticles did not affect the liver at a dose of 10 mg/kg [18]. Jain et al research show that the consumption of iron oxide nanoparticles does not induce any abnormal changes in different tissues [8]. Noori et al investigated the short term effect of intraperitoneal injection of dimercaptosuccinic acid-coated iron oxide nanoparticles (50, 100, 200, 300 mg/kg) for 4 days on the liver tissues in female BALB/c mice and no abnormalities were reported [19]. Perodan et al study on the intraperitoneal injection of iron oxide (0.7, 1.7, 3.7 mg/kg) showed no signs of behavioral or histopathological changes in the vital organs after 48 hours [20]. Feng et al showed that 10 nm PEGylated IONPs had no clear toxicity in BALB/c mice, whereas PEI-coated IONPs displayed dose-dependent lethal toxicity. They emphasized that

the size and coating properties of IONPs is quite intrinsic for their performance and toxicity [22].

CONCLUSIONS

Currently, IONPS are applied for various sorts of fields like medicine, electronics and so on. Hence, toxicity determination of IONPS is quite fundamental for safe usage of them in different scientific areas. In the present study here, our findings demonstrated that various doses of IONPS can induce different pathological complications and clinical signs in rats. With regards to our results, it can be concluded that, toxicity of IONPS in rats is dose-dependent. Clearly, there is a high demand to evaluate the toxicity of different doses of various sizes of IONPS which are utilized for medical goals. Hence, under no circumstances should we use IONPS in high doses for medical purposes without attention to toxicological aspects.

ACKNOWLEDGEMENTS

This work was financed by Standard Research Institute.

CONFLICT OF INTEREST

The authors declare that there are no conflicts of interest regarding the publication of this manuscript.

REFERENCES

1. Fadeel B, Garcia-Bennett AE. Better safe than sorry: Understanding the toxicological properties of inorganic nanoparticles manufactured for biomedical applications. *Advanced Drug Delivery Reviews*. 2010;62(3):362-74.
2. Chomoucka J, Drbohlavova J, Huska D, Adam V, Kizek R, Hubalek J. Magnetic nanoparticles and targeted drug delivering. *Pharmacological Research*. 2010;62(2):144-9.
3. Mahmoudi M, Simchi A, Imani M, Milani AS, Stroeve P. Anin vitro study of bare and poly(ethylene glycol)-co-fumarate-coated superparamagnetic iron oxide nanoparticles: a new toxicity identification procedure. *Nanotechnology*. 2009;20(22):225104.
4. Polyak B, Fishbein I, Chorny M, Alferiev I, Williams D, Yellen B, et al. High field gradient targeting of magnetic nanoparticle-loaded endothelial cells to the surfaces of steel stents. *Proceedings of the National Academy of Sciences*. 2008;105(2):698-703.
5. Sun C, Lee J, Zhang M. Magnetic nanoparticles in MR imaging and drug delivery. *Advanced Drug Delivery Reviews*. 2008;60(11):1252-65.
6. Turaga KK, Kvols LK. Recent progress in the understanding, diagnosis, and treatment of gastroenteropancreatic neuroendocrine tumors. *CA: A Cancer Journal for Clinicians*. 2011;61(2):113-32.
7. Zhao Y, Qiu Z, Huang J. Preparation and Analysis of Fe₃O₄ Magnetic Nanoparticles Used as Targeted-drug Carriers. *Chinese Journal of Chemical Engineering*. 2008;16(3):451-5.
8. Jain TK, Reddy MK, Morales MA, Leslie-Pelecky DL, Labhsetwar V. Biodistribution, Clearance, and Biocompatibility of Iron Oxide Magnetic Nanoparticles in Rats. *Molecular Pharmaceutics*. 2008;5(2):316-27.
9. Pisanic TR, Blackwell JD, Shubayev VI, Fiñones RR, Jin S. Nanotoxicity of iron oxide nanoparticle internalization in growing neurons. *Biomaterials*. 2007;28(16):2572-81.
10. Bourrinet P, Bengel HH, Bonnemain B, Dencausse A, Idee J-M, Jacobs PM, et al. Preclinical Safety and Pharmacokinetic Profile of Ferumoxtran-10, an Ultrasmall Superparamagnetic Iron Oxide Magnetic Resonance Contrast Agent. *Investigative Radiology*. 2006;41(3):313-24.
11. Chaves SB, Lacava LM, Lacava ZGM, Silva O, Pelegrini F, Buske N, et al. Light microscopy and magnetic resonance characterization of a DMSA-coated magnetic fluid in mice. *IEEE Transactions on Magnetics*. 2002;38(5):3231-3.
12. Chaves SB, Silva LP, Lacava ZGM, Morais PC, Azevedo RB. Interleukin-1 and interleukin-6 production in mice's lungs induced by 2, 3 meso-dimercaptosuccinic-coated magnetic nanoparticles. *Journal of Applied Physics*. 2005;97(10):10Q915.
13. Garcia MP, Miranda Parca R, Braun Chaves S, Paulino Silva L, Djalma Santos A, Guerrero Marques Lacava Z, et al. Morphological analysis of mouse lungs after treatment with magnetite-based magnetic fluid stabilized with DMSA. *Journal of Magnetism and Magnetic Materials*. 2005;293(1):277-82.
14. Karlsson HL, Gustafsson J, Cronholm P, Möller L. Size-dependent toxicity of metal oxide particles—A comparison between nano- and micrometer size. *Toxicology Letters*. 2009;188(2):112-8.
15. Müller K, Skepper JN, Posfai M, Trivedi R, Howarth S, Corot C, et al. Effect of ultrasmall superparamagnetic iron oxide nanoparticles (Ferumoxtran-10) on human monocyte-macrophages in vitro. *Biomaterials*. 2007;28(9):1629-42.
16. Singh N, Jenkins GJS, Asadi R, Doak SH. Potential toxicity of superparamagnetic iron oxide nanoparticles (SPION). *Nano Reviews*. 2010;1(1):5358.
17. Babadi, V. Y., Najafi, L., Najafi, A., Gholami, H., Zarji, M. E. B., Golzadeh, J., Shirband, A. Evaluation of iron oxide nanoparticles effects on tissue and enzymes of liver in rats. *J Pharm Biomed Sci*, 2012, 23(23), 1-4.
18. Iversen, N. K., Frische, S., Thomsen, K., Laustsen, C., Pedersen, M., Hansen, P. B. Baatrup, E. Superparamagnetic iron oxide polyacrylic acid coated γ -Fe₂O₃ nanoparticles do not affect kidney function but cause acute effect on the cardiovascular function in healthy mice. *Toxicology and applied pharmacology*, 2013, 266(2), 276-288.
19. Noori, A., Amiri, G. R., Taj, B., Nasr, I. M., Taj, S., & Valiani, A. The effect of magnetic iron oxide nanoparticles on mice liver and kidney 2012, *Journal of Kerman University of Medical Sciences*. 2012, 19(3), 243-252.
20. Prodan AM, Iconaru SL, Ciobanu CS, Chifiriuc MC, Stoicea M, Predoi D. Iron Oxide Magnetic Nanoparticles: Characterization and Toxicity Evaluation by In Vitro and In Vivo Assays. *Journal of Nanomaterials*. 2013;2013:1-10.
21. Monireh, M., & Mohammad, E. The effects of pulmonary administration of Fe₂O₃ nanoparticles on the lung tissue in wistar rat. *International Research Journal of Biological Sciences*, 2014, 3(7), 6-9.
22. Feng Q, Liu Y, Huang J, Chen K, Huang J, Xiao K. Uptake, distribution, clearance, and toxicity of iron oxide nanoparticles with different sizes and coatings. *Scientific Reports*. 2018;8(1).