



Subcutaneous emphysema of the face in Sina hospital: A case report

Farnoosh Mohammadi¹, Bahman Seraj², Sajjad Baber^{3*}

1. Craniofacial Research Center, Shariati Hospital; Department of Oral and Maxillofacial Surgery, School of Dentistry, Tehran University of Medical Sciences, Tehran, Iran.

2. Department of Pediatric Dentistry, School of Dentistry, Tehran University of Medical Sciences, Tehran, Iran.

3. Department of Oral and Maxillofacial Surgery, School of Dentistry, Resident, Sina Hospital, Tehran University of Medical Sciences, Tehran, Iran.

ARTICLE INFO

Article Type: Case Report

Received: 12 Oct. 2018

Revised: 8 Dec. 2018

Accepted: 10 Feb. 2019

*Corresponding author:

Sajjad Baber

Department of Oral and Maxillofacial Surgery,
School of Dentistry, Resident, Sina Hospital, Tehran
University of Medical Sciences, Tehran, Iran.

Tel: +98-21-84902473

Fax: +98-21-84902473

Email: drsajjad_khan@yahoo.com

ABSTRACT

Subcutaneous emphysema of the face is an uncommon complication caused by dental procedures such as curettage, root canal treatment, extraction, restorative treatment and dental instruments like air-water syringe and hand piece. Subcutaneous emphysema can be life threatening if involved the spaces of neck and superior mediastinum. In this rare case, subcutaneous emphysema of the face was developed after potential removal of an amalgam tattoo with the help of an excavator. The patient was completely recovered after three days of timely medical treatment.

Keywords: Celecoxib; Cyclooxygenase-2 inhibitors; Pain management.

Introduction

The presence of air in hypodermic tissues is known as subcutaneous emphysema. Hand-piece and air-water pressure syringes are used in dental procedures like root canal treatment, scaling and root planning, curettage which typically remain the main cause of subcutaneous emphysema of the face. Although rare but can be life threatening if involved the spaces of neck and superior mediastinum. Timely medical intervention was merely performed in this rare case.

Clinical Case

A patient of 13 year old was referred from Shariati hospital to Sina hospital with the complaint of moderate pain and severe swelling on face. The patient has not any known medical history, family history or allergies to drugs, foods e.t.c. The patients vital signs were immediately checked upon entrance to triage. No abnormality was detected. Upon history taking, the patient told precisely

Archive of SID

that she went to Pedodontist few hours ago for typically having her extensive Amalgam tattoo removed on lower left quadrant between the tooth no three and four located on free and attached gingiva. Block and infiltration anesthesia [lidocaine with epinephrine] was performed and a tattoo was removed with the help of an excavator. Air-water syringe was used after which swelling and edema along with severe blurred vision [OS] started on left side of the face. Upon performing physical examination in Sina hospital, crepitations on palpation was present on left side of face i.e. Infra-orbital, buccal, upper and lower lip. The patient reported improved signs of vision on [OS] around three hours after the incident. The patient did not report any airway obstruction or odynophagia. The patient complains of hypoesthesia along with pinprick sensation of the face. No local erythema was seen on the face. In intraoral examination, a dot of Amalgam tattoo was visible. No gross decay on teeth was reported. The colour of gingival appeared normal. On CT scan [computed tomography] examination, air in the subcutaneous tissue of face on left side was noted. On OPG examination, radioopacity was detected on lower left quadrant tooth no 3 which is evident on an amalgam tattoo. There was no air present in the neck on either sides. CBC and coagulation tests such as PT, PTT, INR were reported normal.

The patient was hospitalized for three nights and her vital signs were continuously monitored during her admission in the hospital. Serum Dextrosaline was given intravenously. Antibiotic therapy first generation Cephalosporin such as Cephazolin one gram IV QID and along with the antiprotozoal drug like Metronidazole 500mg IV TDS were properly administered. The patient was discharged after complete confirmation of no visible signs of swelling and crepitations of the face.



Fig 1. Subcutaneous emphysema on right side of face.

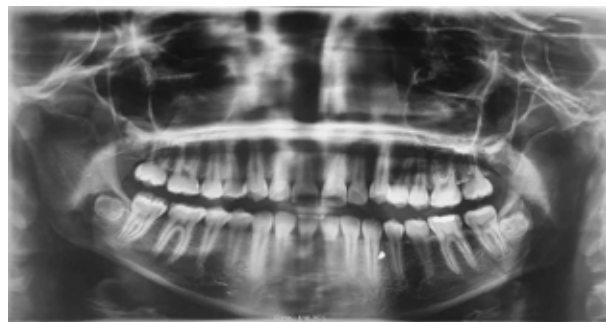


Fig 2. OPG showing part of Amalgam Tattoo attached with root of canine on left side of mandible.

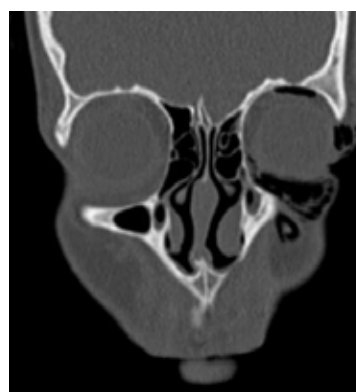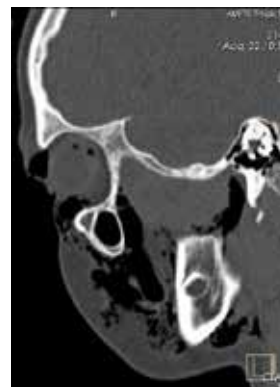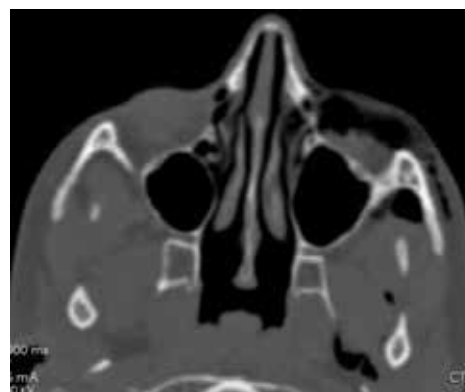


Fig 3. Showing axial and sagittal and coronal cuts showing presence of air in subcutaneous tissues.



Fig 4. Patient has been discharged after three days.

Discussion

Proper history and examination are performed for accurate diagnosis. In this rare case, subcutaneous emphysema on left side of face was developed due to potential use of Air-water syringe and excavator. No previous history of systemic diseases, smoking, alcohol intake and allergic reaction to local foods or potential drugs were reported. That was the first rare case of subcutaneous emphysema of unknown cause and was reported in Sina hospital. Continuous photographs were collected during her admission in Sina hospital. Subcutaneous emphysema could remain fatal if typically involved the spaces of neck and mediastinum.

Conflicts of Interest

There is no conflict of interest to declare.

References

- [1] Bizaki et al: Facial Subcutaneous emphysema after tonsillectomy 2014 10:11.
- [2] Sang W.E, Yoon H.H, Min S.C. Iatrogenic subcutaneous cervicofacial emphysema with pneumomediastinum after class five restoration. J Korean Assoc Oral Maxillofac Surg 2017; 43:49-52.
- [3] Cheol H.J, Seungkyu.Y, Seung W.C, Jae Y.K, Kwang H.P, Jong K.H Subcutaneous emphysema related to dental procedures. J Korean Assoc Oral Maxillofac Surg 2018; 44:212-219.

Please cite this paper as:

Mohammadi F, Seraj B, Baber S; Subcutaneous emphysema of the face in Sina hospital: A case report. J Craniomax Res 2019; 6(2): 85-87