



Survival rate and cervical bone loss of implants placed in non vascularized iliac graft after segmental mandibulectomy

Abbas Karimi ¹, Khatere Arian Rad ², Hassan Mir Mohammad Sadeghi ³, Mahboube Hasheminasab ^{1*}

1. Oral and Maxillofacial Surgeon, Craniofacial Research Center, Tehran University of Medical Sciences, Tehran, Iran; Department of Oral and Maxillofacial Surgery, School of Dentistry, Tehran University of Medical Sciences, Tehran, Iran.

2. Dentist Private Practice.

3. Oral and Maxillofacial Surgeon, Department of Oral and Maxillofacial Surgery, Shahid Beheshti University of Medical Sciences, Tehran, Iran.

ARTICLE INFO

Article Type: Original Article

Received: 5 Nov. 2018

Revised: 28 Dec. 2018

Accepted: 15 Feb. 2019

*Corresponding author:

Mahboube Hasheminasab

Tehran University of Medical Sciences, Department of Oral and Maxillofacial Surgery, North Kargar Street, Tehran, Iran.

Tel: +98-21-84902473

Fax: +98-21-84902473

Email: hasheminasab@gmail.com

ABSTRACT

Objective: The purpose of this study was to evaluate the survival rate and the amount of periimplant bone loss in implants placed in free iliac graft following segmental mandible resection.

Materials and Methods: Over a 5-year period between 2010 and 2015, nine patients with odontogenic tumors who were candidate for segmental mandible resection were enrolled in this study. Resection defect was immediately reconstructed with non-vascularized iliac graft and 4-6 months later 36 implants of 5 different brands were inserted in grafted mandibles. Information regarding implant survival, peri implant bone loss or inflammation for a mean follow up period of 33 months was obtained.

Results: One implant was failed out of 36 implants and the cumulative survival rate of implants was 97.2% in this follow up period. There was no sign of peri implant inflammation or gingival recession or BOP in any patients. The cervical bone loss level varied between 0.6 to 12mm (the length of failed implant) with the average of 0.96 mm. The bone loss level of survived implants varied between 0.6 to 1.72mm with average of 0.64mm.

Conclusion: This study demonstrated that reconstruction of segmental mandibular defect with non vascularized iliac graft followed by dental implant placement is an effective and predictable method to restore oral function.

Keywords: Implant; Non vascularized iliac graft; Segmental resection; Survival; Cervical bone loss.

Introduction

Functional and esthetic rehabilitation of patients with mandible discontinuity defect is still a challenging subject for clinicians. Such defects might be created by different etiologies such as trauma, pathologies, congenital or iatrogenic causes [1]. These integrity defects in mandible might lead to severe problems in mastication, deglutition, speech, protection of airway and esthetics and it can significantly diminish patient's quality of life.

It has been demonstrated that subsequent reconstruction of mandible with bone graft followed by implant insertion can significantly increase the quality of life of these patients [2]. Autogenous bone has been proved to be the "gold standard" and the most effective material for bone regeneration procedures [3].

Archive of SID

Although vascularized bone graft provides a more complete mean of reconstruction, they also have disadvantages including more severe donor site morbidity and longer operation time [4]. They also require a more experienced surgeon. In certain cases, non vascularized bone grafts may be the preferable option. The anterior crest of ilium is the most commonly used donor site since it grants easy access to large amount of bone with high concentration of osteocompetent cells [5,6]. The purpose of this study was to evaluate the survival and success of dental implants placed in nonvascularized iliac bone graft after segmental resection of mandible.

Materials and Methods

In this retrospective study, nine patients with benign odontogenic tumors who had undergone segmental mandible resection and immediate reconstruction with non vascularized anterior iliac crest graft were included. All patients were operated by a single surgeon (first author) between 2010 and 2015 in Shariati hospital, Tehran University of Medical Sciences, Tehran, Iran. The mean length of defect was 7.89cm. Exclusion criteria were comprised of history of any systemic disease or radiation and history of smoking or alcoholism. Informed consent was obtained from all patients and Ethics committee of Tehran University of Medical Sciences approved the study design (IR.TUMS.DENTISTRY.REC.1396.4191). In all patients mandible resection was performed by extraoral approach under general anesthesia. Mandible continuity was established by the use of reconstruction plate (Synthes, Westchester, PA, USA) with at least 3 bicortical screws on each side of native bone. Bicortical blocks were harvested from anterior iliac crest by the same surgeon and blocks were formed according to defect morphology and were fixed to reconstruction plate with screws. (Fig 1).

After 4 to 6 months of graft consolidation, 36 implants were placed in grafted bone of patients (Fig 2). Five different brands were inserted including 6 standard ITI implants (International Team for Implantology [ITI], Institute Straumann AG, Basel, Switzerland), 12 SIC implants (Basel, Switzerland), 7 Implantium implants (Dentium Co, Seoul, Korea), 7 Simple Line II implants (Dentium Co, Seoul, Korea) and 4 DIO implants (Busan, Korea). All implants were placed by a single surgeon exactly at the level of bone and were uncovered 4 months after insertion. Prosthodontic treatment was performed by a single prosthodontist. Implant-supported fixed prostheses with porcelain-fused to metal crowns were used in all patients.

Panoramic and periapical radiographs were obtained immediately after implant placement and after prosthetic restoration and every 12 months thereafter. In 2017 all nine patients were recalled for a comprehensive examination. During the initial clinical examination, four categories of data were recorded as follows:

1. Implant survival (with regards to the success criteria described by Albrektsson and colleagues) [7].
2. Cervical bone loss which was recorded by comparing the cervical bone level of implants in panoramic radiographs taken immediately at the time of definitive restoration and at the time of final recall. Both mesial and distal bone levels were measured. The measurements were performed with adobe Photoshop cc 2015 software (Adobe Systems Inc. San Jose, CA) after digitalization of panoramic radiographs. Dimensional distortion was corrected by comparing the dimension of implant in radiographs and the actual length of implant.
3. Periimplant soft tissue inflammation including pain, erythema, suppuration or bleeding on probing (BOP).
4. Any other complications including gingival recession and , gingival hyperplasia. For statistical analysis SPSS software 22.0 (SPSS Inc. Chicago, IL, USA) was used.

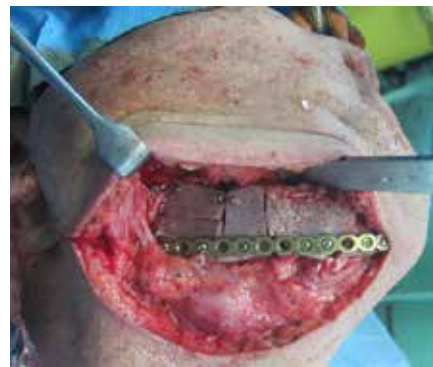

Fig 1. reconstruction of segmental mandibular defect with free iliac graft.

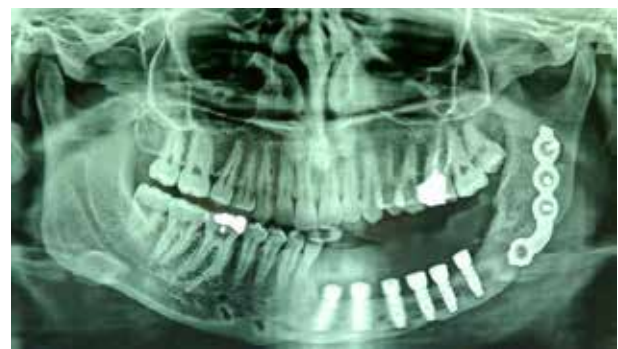

Fig 2. Implants inserted in free iliac graft.

Results

Nine patients with the mean age of 28.2 years (range of 18 to 41) were enrolled in the study. All patients had benign odontogenic tumors of mandible and had been treated with segmental mandible resection and immediate reconstruction with non vascularized iliac graft followed by implant insertion. 36 implants of 5 different brands were inserted. The number of implants per patient ranged from 2 to 7, with the average of 4. The follow up period ranged from 9 to 69 months with the average of 33 months. No tumor recurrence was observed in follow up period. One implant was failed and removed out of 36 implants. The implant failure became evident four months after insertion, at the time of impression taking. The cumulative survival rate was 97.2% in this follow up period. Clinical evaluation of patients showed normal condition. There was no sign of peri implant inflammation in any patients. No gingival recession or hyperplasia was observed in any patients. No BOP was observed around survived implants. 32 out of 35 survived implants were loaded and under function (91.4%) and 3 implants (8.6%)

were submerged and no restoration was arranged for them.

The cervical bone loss level varied between 0.6 to 12mm (the length of failed implant) with the average of 0.96 mm. the bone loss level of survived implants varied between 0.6 to 1.72mm with average of 0.64mm. The annual bone loss level during follow up period was 0.08 to 0.53mm with the mean of 0.23mm. 88.6% of the cervical bone loss of implants were less than 0.44mm. All survived implants had annual bone loss less than 0.53mm (maximum). The annual bone loss level of survived implants is showed in figure 3. No major complications occurred in any patients and postoperative pain and gait disturbance were minimal and temporary.

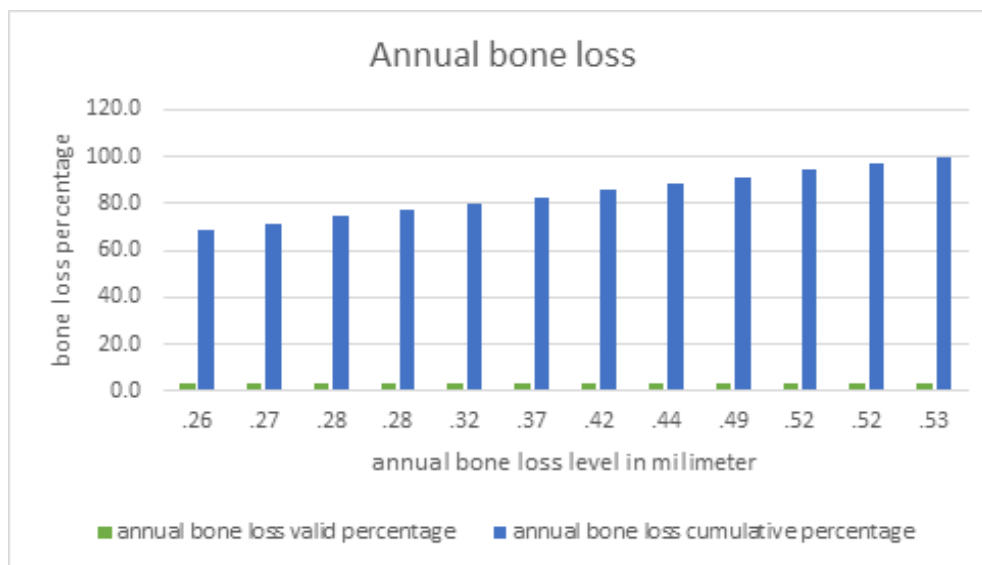


Fig 3. Annual bone loss in millimeter.

Restoring oral function with dental implants after segmental mandibulectomy provides esthetic recovery and maintains adequate nutrition which leads to significant improvement in quality of life of the affected patients. There are many options available to reconstruct segmental mandibular defects from distraction osteogenesis [8] to several autogenic sources [9,10]. Among the autogenous donor sites, iliac crest offers the advantage of supplying a large amount of bone with compact cortices and rich cancellous blood supply, which enhances the possibilities for dental rehabilitation with endosseous implants [11]. Survival of implants in areas that have been reconstructed with iliac graft has been studied by several researchers and various success rates have been achieved after following cases over years [12-14].

In this study it was found out the cumulative survival rate of implants inserted in free iliac graft was 97.2% over the average follow up course of 33 months. This rate is comparable to the anticipated 5-year survival rate of implants in native bone [15]. In a systematic review in 2002, [16] it was concluded that the survival rate of implants placed in augmented sites varied between 79% and 100% and the majority of studies indicated more than 90% success rate after at least one year of function. In that study it was also deduced that these survival rates were similar to those generally reported for implants placed conventionally in sites without the necessity for bone augmentation. In one study [13] on 32 patients, it was demonstrated that the cumulative 5-year survival of dental implants placed in vascularized iliac graft reached 91.8% and dental implants placed in autogenous iliac grafts are an effective method for reconstruction of mandible. In one of the few studies which evaluated the implant success rate in free iliac grafts [12], it was revealed that the cumulative implant success rate was 100% after 5 years and 60.3% after 10 years. It was also demonstrated that both non-vascularized and revascularized iliac crest grafts allow for satisfactory contour restoration in segmental reconstructions of the mandible and serve as a good host for dental Implants.

Apart from iliac crest grafts, other autogenic sources have also been used for mandible reconstruction and subsequent implant placement such as vascularized fibula [17-19] and scapula [9-20] grafts. In one study [17] 71 implants were placed in 16 patients with vascularized fibula graft with mean follow up period of 50.2 months. In that study the cumulative survival and

success rates of implants at the end of the follow-up period were 98.6% and 93.1%, respectively which is comparable to the cumulative survival rate of implants achieved in the present study (97.2%). Although no information was provided regarding the amount of bone loss in the follow up period. In another study [19] the 1-year and 5-year cumulative survival rates of the implants placed in free fibula flap were 96% and 91%, respectively. In that study, the main reasons for failure of the dental implants were infection, tumor recurrence and soft tissue proliferation but no data was provided regarding the bone loss level of implants in long term. In one study, Lanzer [20] and colleagues aimed to evaluate the possibility of implant placement in scapular free vascularized bone flaps and found out that among 10 patients who underwent reconstruction with scapular free flap, although the free flaps survived in all patients but implantation was performed in only 50% of patients. They also observed that loss of bone height and width was significant ($P < 0.001$) within one year of examination and bone height decreased at a faster rate than bone width. However, no data was provided regarding the periimplant bone loss.

In this study, panoramic radiograph was used instead of peri apical radiograph. Because panoramic was a part of annual follow-up of patients with history of odontogenic tumors of mandible. The high success rate achieved in this study could be attributed to factors such as experienced surgeon, short follow up period and otherwise healthy patients. Deducted by the result of this study, it could be concluded that immediate reconstruction of mandible with free iliac graft followed by implant insertion after 4-6 months is a predictable treatment option for patients with segmental mandible defect.

Conflict of Interest

There is no conflict of interest to declare.

References

- [1] Carneiro TAPN, Oliveira MTF, Lima LB, Simamoto-Junior PC, Zanetta-Barbosa D. Immediate loaded implant-supported prosthesis after mandibular reconstruction with free iliac crest bone graft. *Rev Port Estomatol Med Dent Cir Maxilofac.* 2015; 56:117-121.
- [2] Young CW, Pogrel MA, Schmidt BL. Quality of life in patients undergoing segmental mandibular re-

Archive of SID

- section and staged reconstruction with nonvascularized bone grafts. *J Oral Maxillofac Surg.* 2007 Apr; 65(4):706-12.
- [3] Sakkas A, Wilde F, Heufelder M, Winter K, Schramm A. Autogenous bone grafts in oral implantology-is it still a "gold standard"? A consecutive review of 279 patients with 456 clinical procedures. *Int J Implant Dent.* 2017 Dec; 3(1):23. doi: 10.1186/s40729-017-0084-4. Epub 2017 Jun 1.
- [4] Pogrel MA, Podlesh S, Anthony JP, Alexander J.: A comparison of vascularized and nonvascularized bone grafts for reconstruction of mandibular continuity defects. *J Oral Maxillofacial Surg.* 1997; 55:1200.
- [5] Kademani D, Keller E: Iliac crest grafting for mandibular reconstruction. *Atlas Oral Maxillofacial Surg N Am.* 2006, 14:161.
- [6] Van Gemert JT, van Es RJ, Van Cann EM, Koole R. Nonvascularized bone grafts for segmental reconstruction of the mandible--a reappraisal. *J Oral Maxillofac Surg.* 2009 Jul; 67(7):1446-52. doi: 10.1016/j.joms. 2008.12.052.
- [7] Albrektsson T, Zarb G, Worthington P, Eriksson AR. The long-term efficacy of currently used dental implants: a review and proposed criteria of success. *Int J Oral Maxillofac Implants* 1986; 1:11-25.
- [8] Kuriakose MA, Shnyder Y, DeLacure MD. Reconstruction of segmental mandibular defects by distraction osteogenesis for mandibular reconstruction. *Head Neck.* 2003 Oct; 25(10):816-24.
- [9] Yoo J, Dowthwaite SA, Fung K, Franklin J, Nichols A. A new angle to mandibular reconstruction: the scapular tip free flap. *Head Neck.* 2013 Jul; 35(7):980-6. doi: 10.1002/hed.23065. Epub 2012 Jul 30.
- [10] Cordeiro P G, Disa J J, Hidalgo D A, Hu Q Y. Reconstruction of the mandible with osseous free flaps: a 10-year experience with 150 consecutive patients. *Plast Reconstr Surg.* 1999; 104:1314-1320.
- [11] Disa JJ, Cordeiro PG. Mandible reconstruction with microvascular surgery. *Semin Surg Oncol.* 2000; 19:226-234.
- [12] Schliephake H, Schmelzeisen R, Husstedt H, Schmidt-Wondera LU. Comparison of the late results of mandibular reconstruction using nonvascularized or vascularized grafts and dental implants. *J Oral Maxillofac Surg.* 1999; 57:944-950.
- [13] Zou D, Huang W, Wang F, Wang S, Zhang Z, Zhang C, Kaigler D, Wu Y. Autologous Ilium Grafts: Long-term results on immediate or staged functional rehabilitation of mandibular segmental defects using dental implants after tumor resection. *Clin Implant Dent Relat Res.* 2015 Aug; 17(4):779-89. doi: 10.1111/cid.12169. Epub 2013 Oct 31.
- [14] Kim A, Kar K, Nowzari H, Cha HS, Ahn KM. Immediate free iliac bone graft after nonsegmental mandibular resection and delayed implant-placement: a case series. *Implant Dent.* 2013 Oct; 22(5):438-43. doi: 10.1097/ID.0b013e31829f1ed0.
- [15] Pjetursson BE, Thoma D, Jung R, Zwahlen M, Zembic A. A systematic review of the survival and complication rates of implant-supported fixed dental prostheses (FDPs) after a mean observation period of at least 5 years. *Clin Oral Implants Res.* 2012 Oct; 23 Suppl 6:22-38. doi: 10.1111/j.1600-0501.2012.02546.x
- [16] Hämmerle CH, Jung RE, Feloutzis A. A systematic review of the survival of implants in bone sites augmented with barrier membranes (guided bone regeneration) in partially edentulous patients. *J Clin Periodontol.* 2002; 29 Suppl 3:226-31; discussion 232-3.
- [17] Chiapasco M, Biglioli F, Autelitano L, Romeo E, Brusati R. Clinical outcome of dental implants placed in fibula-free flaps used for the reconstruction of maxillo-mandibular defects following ablation for tumors or osteoradionecrosis. *Clin Oral Implants Res.* 2006 Apr; 17(2):220-8.
- [18] Kumar VV, Ebenezer S, Kämmerer PW, Jacob PC, Kuriakose MA, Hedne N, Wagner W, Al-Nawas B. Implants in free fibula flap supporting dental rehabilitation-Implant and peri-implant related outcomes of a randomized clinical trial. *J Cranio-maxillofac Surg.* 2016, Nov; 44(11):1849-1858. doi: 10.1016/j.jcms.2016.08.023. Epub 2016 Sep 9.

Archive of SID

- [19] Wu YQ, Huang W, Zhang ZY, Zhang ZY, Zhang CP, Sun J. Clinical outcome of dental implants placed in fibula-free flaps for orofacial reconstruction. *Chin Med J (Engl)*. 2008, Oct 5; 121(19):1861-5.
- [20] Lanzer M, Gander T, Grätz K, Rostetter C, Zweifel D, Bredell M. Scapular Free Vascularised Bone Flaps for Mandibular Reconstruction: Are Dental Implants Possible? *J Oral Maxillofac Res*. 2015, Jun 30; 6(3):e4. doi: 0.5037/jomr.2015.6304. eCollection 2015 Jul-Sep.

Please cite this paper as:

Karimi A, Arian Rad Kh, Mir Mohammad Sadeghi H, Hasheminasab M; Survival rate and cervical bone loss of implants placed in non vascularized iliac graft after segmental mandibulectomy. *J Craniomax Res* 2019; 6(2): 60-65