



An unusual and rare complication of lefort i osteotomy: A case report

Shahabaldin Azizi ^{1*}, Mehdi Bemanali ², Zahra Mousavi ³, Mahdiah Karimizadeh ⁴

1. Department of Oral and Maxillofacial Surgery, School of Dentistry, Shahid Beheshti University of Medical Sciences, Tehran, Iran.

2. Shahid Beheshti University of Medical Sciences, Tehran, Iran.

3. Shiraz University of Medical Sciences, Shiraz, Iran.

4. Department of Pediatric, Bushehr University of Medical Sciences, Bushehr, Iran.

ARTICLE INFO

Article Type: Case Report

Received: 2 Jul. 2019

Revised: 8 Nov. 2019

Accepted: 1 Dec. 2019

*Corresponding author:

Shahabaldin Azizi

Department of Oral and Maxillofacial Surgery,
School of Dentistry, Shahid Beheshti University of
Medical Sciences, Tehran, Iran.

Tel: +98-912-0350641

Fax: +98-21-84902473

Email: azizi_shahab39@Yahoo.com

ABSTRACT

The LeFort I osteotomy is a versatile and simple procedure used by oral and maxillofacial surgeons for correction of congenital, developmental, or acquired dentofacial deformities. This technique is widely used due to its low complication rate such as rare, life-threatening events, reliable long-term results, and a high level of patient satisfaction. This report presents a case of LeFort I osteotomy resulting in an unusual complication of pulmonary thromboembolism.

Keywords: LeFort I osteotomy; Complication; Pulmonary thromboembolism.

Introduction

Pulmonary thromboembolism (PTE) is the obstruction of a pulmonary vessel or vessels by a thrombus. The term pulmonary thromboembolism encompasses both local thrombus formation (primary pulmonary thrombosis), and translocation of a thrombus formed elsewhere in the vascular system (pulmonary embolism) [1]. This phenomenon is commonly reported in orthopedic operations, but reports of thromboembolic complications

after elective orthognathic surgeries are limited [2,3]. Recently, in their retrospective study of 5025 cases, Ferri et al. showed that no case of pulmonary complication was encountered among patients having orthognathic surgery [4]. Generally, LeFort I osteotomy is considered to be safe, producing predictable and stable results, with a relatively small number of life-threatening complications [5,6]. The incidence rate of complications for healthy individuals is

Archive of SID

low, ranging from 4 to 9% [7]. There are only a few articles discussing the incidence of rare but severe complications [8,9]. The authors report a case of pulmonary thromboembolism as a peculiar complication in Le Fort I osteotomy.

Case Report

A 48-year-old man (weight: 90kg, height: 186cm, body mass index [BMI]: 26) was referred to the Oral and Maxillofacial Surgery ward of Imam Hossein hospital at Shahid Beheshti University of Medical Sciences (Tehran, Iran) in June 2018. His main complaint was a maxillary bone deficiency (Fig 1). He had a skeletal class III maxillary alveolar ridge deficiency. Routine preoperative work-up was performed. Physical examination and laboratory findings were normal. He had a negative family history of clotting disorders or thrombotic events. The patient reported taking Sertraline and Depakinin the previous two years that were prescribed by his psychiatrist. Also, the patient had no history of smoking or drinking. The patient had no history of hypertension or arrhythmia, there were no electrocardiographic abnormalities on preoperative examination, and chest radiographic findings were normal. His surgical history included a lumbar disc surgery (discectomy L4-L5) four years ago which was uneventful from both anesthetic and surgical standpoints. After a complete evaluation of his clinical and radiographic records, LeFort I osteotomy and reconstruction with iliac bone graft was considered as the best treatment option. Before anesthesia, he had a baseline blood pressure (BP) of 115/80 mmHg, heart rate of 65bpm, respiratory rate of 17 breaths/min, and oxygen saturation of 98%. General hypotensive anesthesia was recommended as a standard measure for orthognathic surgery that involves the maxilla to decrease mean arterial pressure (MAP) and the risk of intraoperative bleeding. Therefore, the intravenous drug regimen (propofol plus remifentanil) was administered. The patient was monitored by pulse oximetry, electrocardiography, thermal probe, and capnography, and his vital signs were stable during operation. The operation was uneventful, with an operative time of 4 hours and 30 minutes. He was taken to the recovery room in a stable condition. 30 minutes after being placed into the recovery room, the patient acutely desaturated to 70%, a few minutes later, lung auscultation confirmed crackling sounds, and elevated jugular venous was observed. His blood pressure (BP) was 100/80 mmHg, and his heart rate (HR) was approximately 88bpm. However, the transthoracic echocardiogram did not show any signs of heart fail-

ure or strain. After a discussion with a team of cardiologists, the diagnosis of pulmonary embolism was considered, and the decision of referring the patient to the intensive care unit (ICU) for further diagnostic workup and supportive treatment was made. Then, under a tentative diagnosis of pulmonary embolism (PE), computed tomographic (CT)-angiography was performed. The pulmonary angiographic scan of the chest revealed filling defects within the branches of the right lower lobar (RLL) (posterior segment) and right upper lobar (RUL) (medial basal segment), compatible with pulmonary thromboembolism (Fig II).

Promptly, 1 mg/kg Enoxaparin (Clexane, low-molecular-weight heparin) was administered subcutaneously, twice daily as recommended. The next day, the patient had stable vital signs without any complaints. The oxygen saturation and the auscultation returned to normal. The patient was admitted to the ICU for the next two days due to a decrease in hemoglobin levels (from 13.9 mg/dL before operation to 8.2 mg/dL after ICU admission). Thrombocytopenia (from 262,000 to 130,000/mm³) was also observed. On the 3rd postoperative day, a Doppler ultrasound scan of the lower limbs and iliac vein and upper extremities were normal and failed to demonstrate any evidence of deep venous thrombosis. Also, the electroencephalogram and brain CT scan findings were normal (Fig III).

The patient remained asymptomatic and was discharged on postoperative day 5. Detailed examination of thrombotic predispositions (such as antithrombin deficiency, prothrombin disturbance, protein C/S deficiency, factor V dysfunction, and anti-phospholipid antibody syndrome) was performed, and no abnormality was detected. Rivaroxaban 15mg twice daily for 3 weeks, followed by 20mg once daily for 3 months was administered, and during a 14-month postoperative follow-up, there has been no sign of recurrence.

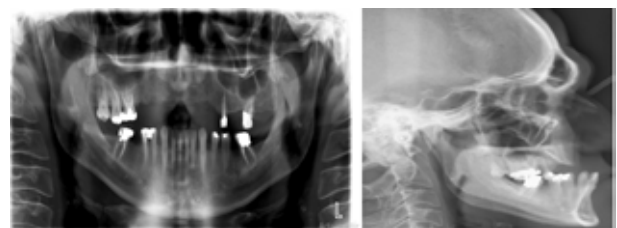


Fig 1. The preoperative radiographs.

Archive of SID

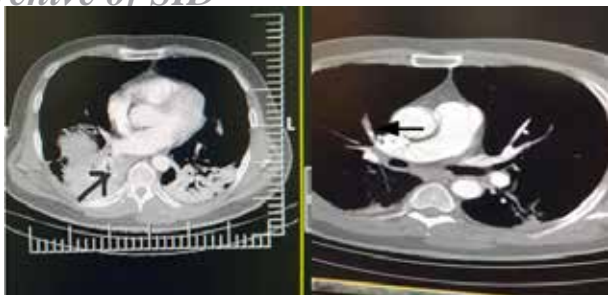


Fig II. CT scan demonstrating filling defects within the sub segmental branch of right lower lobe (right) and segmental branch of right upper lobe (left).

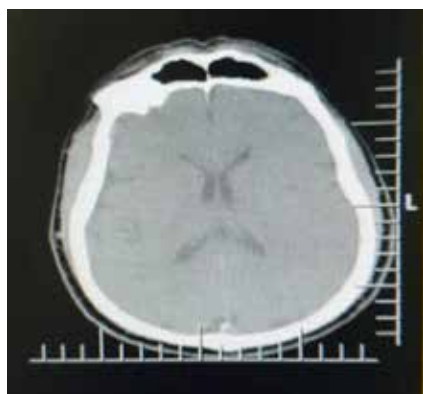


Fig III. Normal brain CT scan.

Discussion

For healthy individuals, the risk of complications with the LeFort I osteotomy is considered low; the common early complications include nerve injury and malocclusion. Also, ophthalmic complications (blindness, ocular palsy, and diplopia), haemorrhage, fractures, loss of teeth vitality, sinusitis, necrosis, and infection have been reported following LeFort I osteotomy [7,9]. Pulmonary complications, such as PTE in this clinical setting is very rare [4,5]. Therefore, the present case illustrates an infrequent but potentially life-threatening, complication. Similar to other surgical procedures, the LeFort I osteotomy may lead to a variety of complications at different stages of the surgery [10,11]. Although the complication of venous thromboembolism up to one month after surgery is well-recognized, reports of intraoperative and perioperative thromboembolic complications are limited [12]. The overall incidence of symptomatic thromboembolism in orthognathic surgeries is very low. Verlinden et al. estimated the incidence of less than 0.0005% based on the study of 4127 patients [13]. In another study, Van de Perre et al. investigated a group of 2046 patients and reported three cases of deep vein thrombosis (less than 0.01%), resulting in pulmonary embolism in one case, which

was non-fatal [14]. Therefore, the incidence of venous thromboembolism (including DVT and pulmonary embolism) resulting from orthognathic surgeries is low. PTE may cause undesired complications, which can lead to serious morbidity and mortality and should be diagnosed and managed instantly. Also, thromboembolic diseases are related to several risk factors, including diabetes and obesity, malignant disorders, thrombotic predispositions (antiphospholipid antibody syndrome, prothrombin disturbance, and factor V dysfunction), and prolonged preoperative immobilization [15,16]; however, our patient represents a rare case of thromboembolic complication in the absence of any known risk factors. Therefore, careful preoperative planning and appropriate preoperative consultation should be followed in these specific situations. Long surgical procedures may affect the clotting cascade or result in the release of thrombogenic factors. Blackburn et al. stated that orthognathic operations lasting longer than two hours, especially with simultaneous iliac bone grafting, can increase the risk of thromboembolic complications, although it was not significantly associated with iliac crest bone graft [17].

In the present case, a longer operation time could have increased the risk of PTE. Generally, the signs and symptoms of venous thromboembolism usually develop several days after surgery [18]. However, in contrast to the previous study, in our patient PTE developed within 30 minutes after surgery, highlighting the importance of early diagnosis and treatment of pulmonary thromboembolism or its prevention. Nowadays, well-defined and widely utilized algorithms have been established to manage pulmonary embolism for adults. However, there are controversies about the advantage of using thromboembolism prophylaxis in orthognathic surgery, mainly because of its low incidence rate and short surgical duration. Forouzanfar et al concluded that thromboembolism prophylaxis might be justified only in patients with obvious potential risk factors[19]. Thus, the present patient did not receive thrombo-prophylaxis because of his low-risk profile.

Conclusion

This case highlights the possibility of a potentially perioperative pulmonary thromboembolism occurring after orthognathic surgery. This report allows us to conclude that the risk of pulmonary embolism of LeFort I osteotomy might be underestimated. Therefore, the occurrence of PTE following orthognathic procedures should incite the search for a means to screen

Conflict of Interest

There is no conflict of interest to declare.

References

- [1] Goggs, R., Benigni, L., Fuentes, V. L., & Chan, D. L. (2009). Pulmonary thromboembolism. *Journal of Veterinary Emergency and Critical Care*, 19(1), 30-52.
- [2] Wang, Y., Liu, J., Yin, X., Hu, J., Kalfarentzos, E., Zhang, C., & Xu, L. (2017). Venous thromboembolism after oral and maxillofacial oncologic surgery: Report and analysis of 14 cases in Chinese population. *Medicina oral, patologia oral y cirugiabucal*, 22(1), e115.
- [3] Lidders, J. N., Parmar, S., Stienen, N. L. M., Martin, T. J., Karagozoglu, K. H., Heymans, M. W., & Forouzanfar, T. (2015). Incidence of symptomatic venous thromboembolism in oncological oral and maxillofacial operations: retrospective analysis. *British Journal of Oral and Maxillofacial Surgery*, 53(3), 244-250.
- [4] Ferri, J., Druelle, C., Schlund, M., Bricout, N., & Nicot, R. (2019). Complications in orthognathic surgery: A retrospective study of 5025 cases. *International orthodontics*, 17(4), 789-798.
- [5] Steel, B. J., & Cope, M. R. (2012). Unusual and rare complications of orthognathic surgery: a literature review. *Journal of oral and maxillofacial surgery*, 70(7), 1678-1691.
- [6] Justus, J., Tuinzing, D. B., Greebe, R. B., & van der Kwast, W. A. (1991). Intra-and early postoperative complications of the Le Fort I osteotomy: a retrospective study on 410 cases. *Journal of Cranio-Maxillofacial Surgery*, 19(5), 217-222.
- [7] Garg, S., & Kaur, S. (2014). Evaluation of post-operative complication rate of Le Fort I osteotomy: a retrospective and prospective study. *Journal of maxillofacial and oral surgery*, 13(2), 120-127.
- [8] Bendor-Samuel, R., Chen, Y. R., & Chen, P. K. (1995). Unusual complications of the Le Fort I osteotomy. *Plastic and reconstructive surgery*, 96(6), 1289-96.
- [9] Kramer, F. J., Baethge, C., Swennen, G., Teltzrow, T., Schulze, A., Bertens, J., & Brachvogel, P. (2004). Intra-and perioperative complications of the Le-Fort I osteotomy: a prospective evaluation of 1000 patients. *Journal of Craniofacial Surgery*, 15(6), 971-977.
- [10] Kim, S. G., & Park, S. S. (2007). Incidence of complications and problems related to orthognathic surgery. *Journal of oral and maxillofacial surgery*, 65(12), 2438-2444.
- [11] Ho, M. W., Boyle, M. A., Cooper, J. C., Dodd, M. D., & Richardson, D. (2011). Surgical complications of segmental Le Fort I osteotomy. *British Journal of Oral and Maxillofacial Surgery*, 49(7), 562-566.
- [12] Lowry, J. C. (1995). Thromboembolic disease and thromboprophylaxis in oral and maxillofacial surgery: experience and practice. *British Journal of Oral and Maxillofacial Surgery*, 33(2), 101-106.
- [13] Verlinden, C. R., Tuinzing, D. B., & Forouzanfar, T. (2014). Symptomatic venous thromboembolism in orthognathic surgery and distraction osteogenesis: A retrospective cohort study of 4127 patients. *British Journal of Oral and Maxillofacial Surgery*, 52(5), 401-404.
- [14] Van de Perre, J. P., Stoelinga, P. J., Blijdorp, P. A., Brouns, J. J., & Hoppenreijns, T. J. (1996). Perioperative morbidity in maxillofacial orthopaedic surgery: a retrospective study. *Journal of Cranio-Maxillofacial Surgery*, 24(5), 263-270.
- [15] Geerts, W. H., Heit, J. A., Clagett, G. P., Pineo, G. F., Colwell, C. W., Anderson, F. A., & Wheeler, H. B. (2001). Prevention of venous thromboembolism. *Chest*, 119(1), 132S-175S.
- [16] Anderson Jr, F. A., & Spencer, F. A. (2003). Risk factors for venous thromboembolism. *Circulation*, 107(23_suppl_1), I-9.
- [17] Blackburn, T. K., Pritchard, K., & Richardson, D. (2006). Symptomatic venous thromboembolism after orthognathic operations: An audit. *British Journal of Oral and Maxillofacial Surgery*, 44(5), 389-392.

Archive of SID

- [18] Skorpil, N., Van Den Bergh, B., Heymans, M. W., & Forouzanfar, T. (2012). Is thromboembolism prophylaxis necessary for low and moderate risk patients in maxillofacial trauma? A retrospective analysis. *International journal of oral and maxillofacial surgery*, 41(8), 902-905.
- [19] Forouzanfar, T., Heymans, M. W., Van Schuilenburg, A., Zweegman, S., & Schulten, E. A. J. M. (2010). Incidence of venous thromboembolism in oral and maxillofacial surgery: a retrospective analysis. *International journal of oral and maxillofacial surgery*, 39(3), 256-259.

Please cite this paper as:

Azizi Sh, Bemanali M, Mousavi Z, Karimizadeh M; An unusual and rare complication of lefort i osteotomy: A case report. *J Craniomax Res* 2020; 7(1): 40-44