



Arthroscopic Fixation of Traumatic Tibial Bone Avulsion of Posterior Cruciate Ligament Using Scorpion Suture Passer: A New Technique

Farzad Amouzadeh Omrani,¹ Mohammad Khak,¹ Mohammad Mahdi Sarzaeem,¹ and Gholamhossein Kazemian^{1*}

¹Department of Orthopedic and Trauma Surgery, Shahid Beheshti University of Medical Sciences, Tehran, IR Iran

*Corresponding author: Gholamhossein Kazemian, Department of Orthopedic and Trauma Surgery, Shahid Beheshti University of Medical Sciences, Tehran, IR Iran. Tel: +982177569993. E-mail: mohammadkhak@yahoo.com

Received 2017 April 09; Revised 2017 June 21; Accepted 2017 September 06.

Abstract

Several operative techniques have been described for operative treatment of posterior cruciate ligament (PCL) avulsion injuries. Here we introduce a new arthroscopic suture technique for the treatment of PCL avulsion fracture using Scorpion suture passer. Three standard portals of anteromedial, anterolateral, and posteromedial are established along with the central trans-patellar tendon portal, if necessary. A Scorpion suture passer and No. 2 FiberWire were used to put two sutures at the base of the PCL-bone interface. After reducing the fragment, a tibial target guide for PCL was used to make a tunnel at the center of the fracture site and the fragment, if possible. An Endotack is used to fix the sutures at the anterior border of the tibia. This is a practical technique with a short learning curve and biomechanically stable fixation.

Keywords: Posterior Cruciate Ligament, Avulsion Fracture, Suture Fixation, Arthroscopy

1. Background

Dashboard injury and hyperflexion of the knee is the most commonly reported mechanism of tibial avulsion fracture of PCL (1, 2). However, effective management and indications for operative treatment of PCL avulsion injuries are still controversial. Recent studies have proposed surgical reattachment as a better approach in comparison with conservative treatment (3-7). Hence, to obtain excellent functional results, a displaced or unstable bony avulsion of PCL should be anatomically reduced and rigidly fixed.

Several operative techniques have been described and recommended. Open reduction with internal screw fixation through a posterior approach has been reported as a suitable approach for stability achievement (4, 5). Given the deep location of the PCL and the complexity of the anatomy, minimally invasive arthroscopic techniques (1-3, 7-10) have been developed.

Here we introduce a new arthroscopic suture technique for the treatment of PCL avulsion fracture using Scorpion suture passer, which is easy to perform with reproducible results.

2. Methods

The diagnosis is established by history taking, clinical examination, and radiographic evaluation. The patients are selected for arthroscopic PCL avulsion fixation if there is a large displaced avulsion fracture fragment on the tibial side that seems susceptible to further displacement according to our clinical judgment. Besides, comminuted or small fragment PCL avulsions, which show more than 10 mm of post tibial translation in stress radiographs, are included as well. Those with a significant ligamentous injury in medial or lateral side according to varus-valgus stress tests and dial test are excluded.

2.1. Surgical Technique

A thorough physical examination of the affected lower extremity is performed under spinal or general anesthesia to confirm the diagnosis. The injured knee is prepared and draped in the supine position with a high tourniquet applied. With the knee flexed to 90 degrees, the standard anteromedial, anterolateral, and posteromedial portals are located at their standard position; i.e. 1 cm medial to the medial border of the patellar tendon, 1 cm lateral to the lateral border of the patellar tendon, and 1 cm posterior

to the posteromedial margin of femoral condyle, respectively. One cm above the joint line is almost always the safe distance from the menisci.

The injured joint is then inspected using a 30-degree arthroscope introduced through the anteromedial and anterolateral portals and any concomitant meniscal injury is treated accordingly. The posteromedial compartment is visualized by advancing between the PCL and the medial femoral condyle; a 20-gauge needle is penetrated to the joint to ascertain the location and direction of the portal (Figure 1). Hence, the posteromedial portal is made under direct vision.

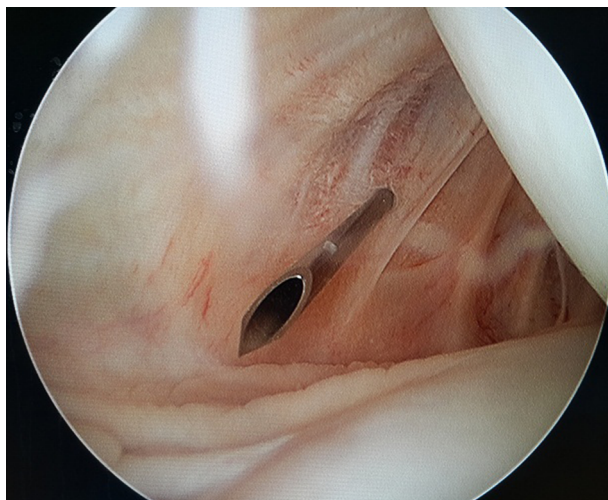


Figure 1. The Posteromedial Portal is Made Under Direct Vision Using a 20-Gauge Needle to Ascertain the Location and Direction of the Portal.

Scoping through the anteromedial portal, a power shaver is placed in the posteromedial compartment through the posteromedial portal; the hematoma and hypertrophic synovium behind the PCL is debrided (Figure 2). The free bony fragments are also removed using a curette and graspers and the fracture crater is explored as much as possible; however, the fragments connected to the PCL fibers or menisci are left untreated.

Scoping through a 70-degree arthroscope through the posteromedial portal, the main fragment attached to PCL is temporarily reduced into its anatomic position; mild anterior drawer force to the proximal tibia in conjunction with a probe entered from an accessory central transpatellar tendon portal (Figure 3) is helpful to manipulate the fragment. If necessary, we shave more synovium and debride the crater again to make a near anatomic reduction of the main fragment possible.

By changing the scope to the posteromedial portal, the base of PCL is viewed at its insertion into the main

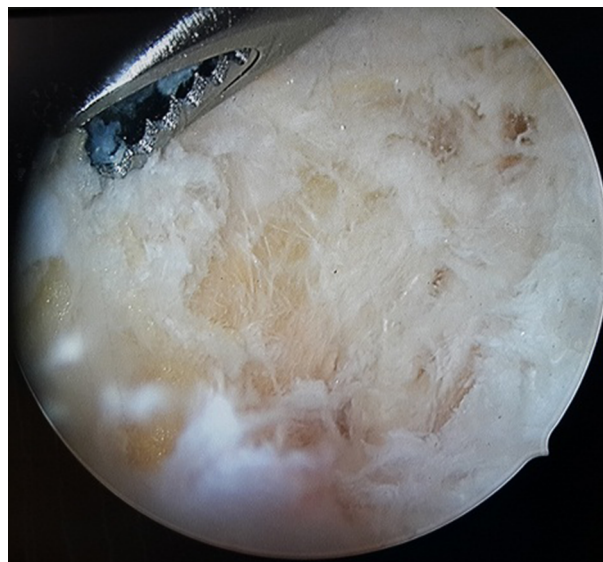

Figure 2. A Power Shaver is Placed in the Posteromedial Compartment and the Fracture Crater is Explored as Much as Possible.

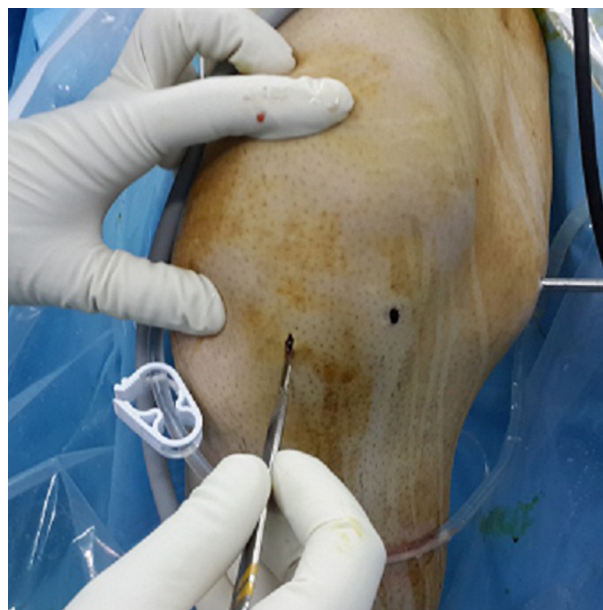


Figure 3. The Placement of Accessory Central Trans-Patellar Tendon Portal

fragment. A Scorpion suture passer (Arthrex, Naples, Fla) loaded with No. 2 FiberWire (Arthrex) is introduced to the base of PCL through the central transpatellar tendon portal and shot (Figure 4). To ascertain a firm fixation, another suture is passed in the same manner and 4 strands are taken out the transpatellar portal.

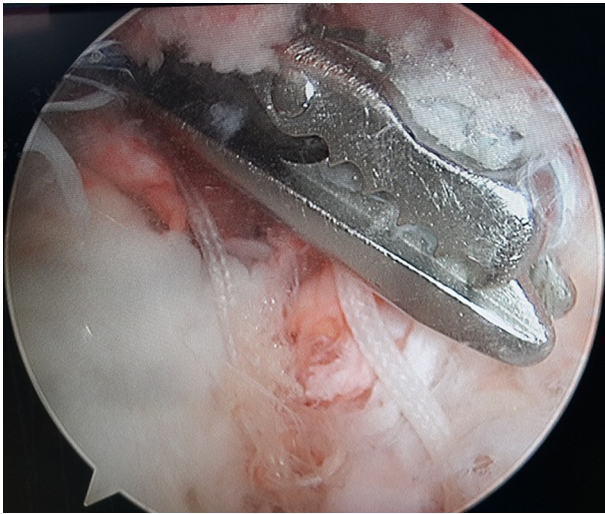


Figure 4. A Scorpion Suture Passer (Arthrex, Naples, Fla) Loaded with No. 2 FiberWire (Arthrex) is Introduced to the Base of PCL Through the Central Trans-Patellar Tendon Portal.

Scoping through the posteromedial portal, the fracture reduction is restored again by appropriate manipulation. A tibial target guide for PCL (Karl Storz, Tuttlingen, Germany) is introduced through the trans-patellar entry and rested on the PCL avulsion fragment to keep its reduction (Figure 5). A small stab incision is made 1 cm medial and distal to the tibial tubercle. A 2.7 cm threaded guide pin is inserted from the anteromedial cortex of the tibia to penetrate the center of the fracture site, and if large enough, it passed through the main fragment; this may temporarily stabilize the fragment. In order to prevent any injury to the posterior structures, the emergence of the guide wire must be directly observed through the posteromedial portal. With the tibial target guide kept in position, the wire is overdrilled with a 4.5 mm cannulated drill.

The guide wire is removed and a suture grasper is inserted through the tibial tunnel to pull back the two ends of the sutures. Alternatively, a double strand looped wire is put in through the tibial tunnel and the looped tip grasps out the trans-patellar portal. The two ends of the sutures are connected with the looped tip outside the trans-patellar portal and pulled in the tibial tunnel. Care must be taken not to engage ACL fibers by passing the looped wire and strands medial to ACL.

With continuous tension over the sutures, the knee is taken through a few cycles of a gentle range of motion to condition the PCL, bony fragment, and sutures. The two ends of the sutures are then knotted to a 16 mm wide Endotack (Karl Storz, Tuttlingen, Germany) at the anterior opening of the tibia with the knee in full extension; continuous

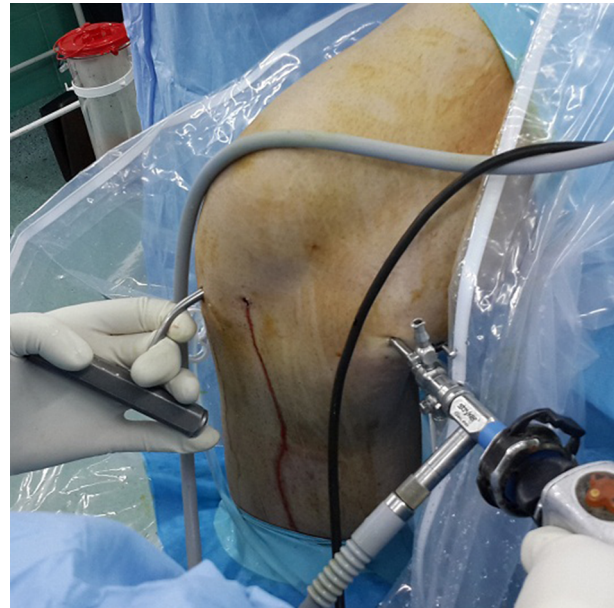


Figure 5. A Tibial Target Guide for PCL Rested on the PCL Avulsion Fragment to Keep Its Reduction Through the Trans-Patellar Portal.

tension over the suture and a posterior to anterior force to the proximal tibia decrease the risk of PCL loosening.

Before closing the wound, the knee is taken through a full range of motion; posterior drawer test is performed to confirm knee stability and appropriate reduction of the bony fragment and tightness of the PCL are checked arthroscopically (Figure 6). If necessary, the tension over PCL can be increased by twisting the Endotack over the tibia (Figures 7 - 9).

2.2. Postoperative Management

A hinged knee brace locked in full extension is applied for the first 2 weeks to prevent extension limitation. Quadriceps muscle strengthening, patella manipulation, and toe touch weight bearing using crutches are encouraged the day after the operation. At the 3rd week, the protected range of motion exercises is started aiming at 120 degrees flexion at 6 weeks; partial weight bearing is permitted, as well. The brace is removed at the 8th week and the patient can increase activity as convenient.

At 4 months interval, knee function is assessed according to the Lysholm Knee Scoring system, which includes eight items of pain, swelling, limp, support using cane or crutches, climbing stairs, instability, squatting, and locking sensation in the knee. Treatment efficacy was classified based on the Lysholm Knee Scoring Scale, as follows: excellent for > 85 points; good for 70 - 85 points; intermediate for 60 - 69 points; and poor for < 60 points.

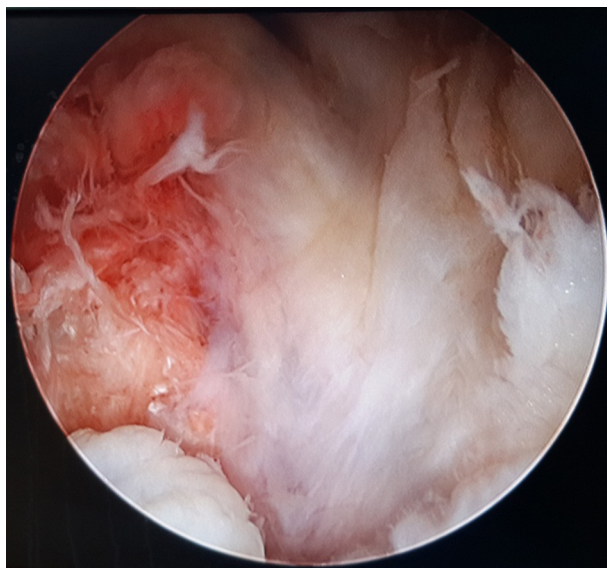


Figure 6. PCL Tibial Avulsion Reduction is Confirmed Through the Posteromedial Portal.

3. Results

A total of 12 patients (1 female and 11 males) with a mean age of 24.1 ± 6.0 were recruited (min: 18; max: 37). All the patients reported a dashboard injury (10 MCA and 2 CC). Associated fractures in the same lower limb were observed in 2 cases, one with femoral shaft fracture who underwent nail interlocking and another with comminuted patella fracture who underwent partial patellectomy. The mean duration between PCL avulsion fracture and arthroscopic fixation was 7 ± 2.7 days. We considered a delay of 7-10 days between the trauma and arthroscopy to provide the knee joint with appropriate capsular healing in order to prevent fluid extravasation. In cases of associated fractures, the major fractures were addressed in the first few days and the PCL avulsion was fixed within 7 days. All the patients were followed up for at least 4 months. A satisfactory near anatomical reduction of the main fracture fragment was obtained in 9 patients, while all of the operations were successful in obtaining a functional PCL.

A good wound healing was achieved in all the patients with no acute or late infection. The only significant complication was breakage of the tip of Scorpion needle in one patient, which was not removable.

The total Lysholm Score in the study population was 80.6 ± 20.2 (min: 40; max: 100), showing 3 patients with poor functional outcome; two with associated limb fracture reported poor Lysholm Score and the 3rd patient with poor score was an 18-year-old girl who suffered major de-

pression and did not cooperate in the follow-up physiotherapy (Table 1).

Table 1. Functional Outcome According to Lysholm Score in the Study Population

	No. (%) (n = 12)
Excellent > 90	5 (41.7)
Good 84 - 90	3 (25.0)
Fair 65 - 83	1 (8.3)
Poor < 65	3 (25.0)

Associated meniscal injury requiring arthroscopic repair was present in 5 patients all of which underwent inside-out suture fixation or partial meniscectomy for the associated meniscal tear (Table 2). The patients with no meniscal tear recorded a significantly better Lysholm score (P value = 0.05). However, the 2 patients with associated limb fracture who reported a poor Lysholm score had a concomitant meniscal tear, as well. Hence, in a second analysis, we excluded the 2 patients with associated limb fracture (analyzing 10 remaining patients) and this time there was no significant difference between the two groups regarding final Lysholm score (P value = 0.106), suggesting that the benefit of arthroscopic surgery for treating concomitant injuries may result in equal functional outcome in the two groups.

The operation was uneventful in all 12 patients, with a mean duration of 113.3 ± 36.8 (range 60 - 155) minutes. There was no significant correlation between duration of surgery and final Lysholm score ($r = -0.16$, P value = 0.612). However, there was an obvious progressive learning curve in our institution (Figure 10).

No posterior sagging was found in 8 patients while grade 1-2 posterior sagging was found in 4 patients, examined in posterior stress examination at the fourth month of follow-up; however, no patient showed a grade 3 sagging. Mean body mass index (BMI) was recorded as 22.2 ± 3.2 in the study population; however, considering BMI as a confounding variable, no significant association was found between final Lysholm score and BMI (P value > 0.05).

4. Discussion

Treatment approaches for PCL avulsion fracture are based mainly on open surgery (4, 5). However, arthroscopic surgeries are newly proposed to assist in lessening the neurovascular risks with the benefit of better cosmetic results. Open surgeries are usually performed through the traditional posterior or posteromedial approaches (4, 5). Disadvantages of these approaches include decreased the

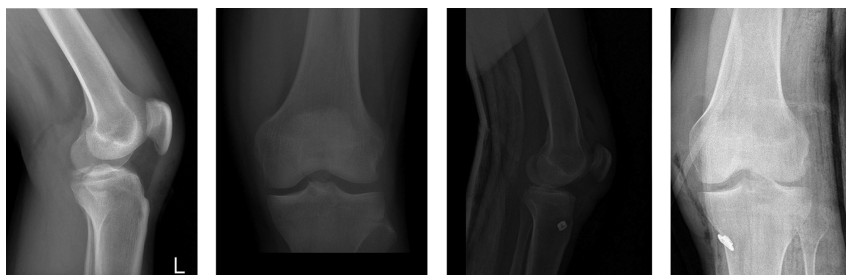


Figure 7. Anteroposterior and Lateral Pre- and Postoperative Radiographs of a Patient Using Endotack for Distal Fixation

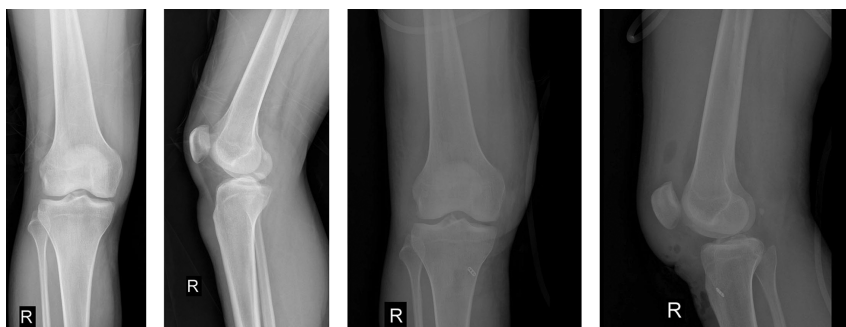

Figure 8. Anteroposterior and Lateral Pre and Postoperative Radiographs of a Patient Using Endobutton for Distal Fixation

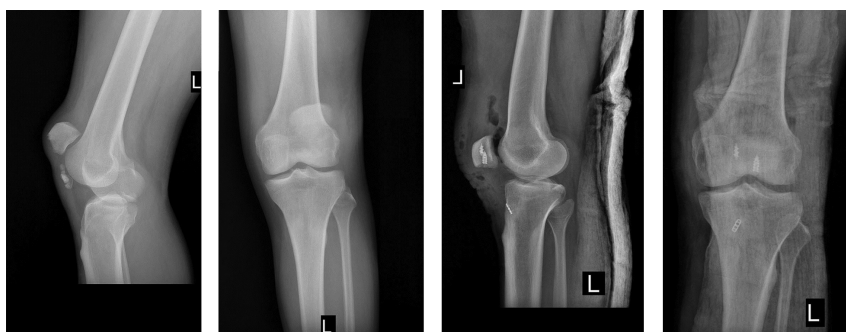

Figure 9. Anteroposterior and Lateral Pre and Postoperative Radiographs of a Patient with Partial Patellectomy.

Table 2. Lysholm Score According to an Associated Meniscal Injury Requiring Arthroscopic Repair in All of the Patients and After Excluding Patients with Associated Limb Fracture

Lysholm Score	No. (%)	Mean Lysholm Score	P Value
Lysholm Score According to an Associated Meniscal Injury Requiring Arthroscopic Repair in "all of the Patients" (n = 12)			
Meniscal tear	5 (41.7)	68.0 ± 25.6	0.05
No meniscal tear	7 (58.3)	89.6 ± 9.1	0.05
Lysholm Score According to Associated Meniscal Injury "After Excluding Patients with Associated Limb Fracture" (n = 10)			
Meniscal tear	3 (30.0)	83.3 ± 20.1	0.106
No meniscal tear	7 (70.0)	89.5 ± 9.1	0.106

range of motion due to large amounts of soft tissue scar after dissection to access the anatomic insertion site of the

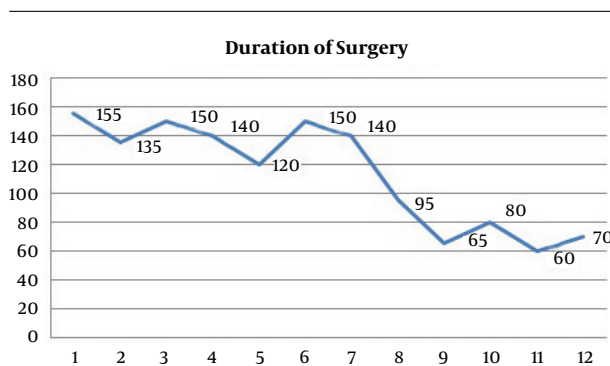


Figure 10. The Progressive Learning Curve in Arthroscopic Fixation of PCL Avulsion Fracture Treatment.

PCL deep within the posterior tibial plateau. The proximity of the popliteal neurovascular bundle also makes the open surgery a high-risk procedure. The trauma to the medial head of the gastrocnemius to enhance exposure of the avulsion site can lead to postoperative weakness of the muscle (4, 5).

On the other hand, using arthroscopic techniques, one can address concomitant lesions, such as meniscal tears. Besides, using less surgically invasive procedures, which eliminate the need for exposure of the posterior capsule and muscles, results in decreased soft-tissue damage and scar formation (1-3, 7-11).

After the first experimental arthroscopic fixation of avulsion fracture of PCL in cadaveric knees in 1988, (12) many attempts have been made to provide the orthopedic world with new practical and less invasive approaches towards this avulsion fracture. However, introducing less technical demand and less time consuming one that covers both large and small fragment comminuted fractures has always been enthusiastic.

As for PCL reconstruction surgeries that are technical demand, PCL avulsion fixation using arthroscopy needs skillful handling of the instruments in the posterior compartment of the knee. However, the simplicity of using Scorpion suture passer to put the suture around the PCL shortens the learning curve. We believe the surgical time necessary for this method is as little as 45 minutes in experienced hands and if even performed by general orthopedic surgeons, it is comparable to that of open surgery.

Biomechanically thinking, although we pull the suture anterior-distally through the tibial tunnel, putting the end of the tunnel at the base of the fracture turns the force directed along the PCL fibers. This helps have a functional PCL despite a non-anatomic reduction in comminuted fractures until union occurs at the bone-tendon interface. In open surgical approaches, despite a rigid bony fix-

ation, the associated PCL ruptures are ignored, making future PCL reconstruction sometimes inevitable (4, 5).

Our technique is practical to ascertain a reliable fixation in comminuted and small fragment fractures. Leaving comminuted fragments with small attachments to the posterior capsule or PCL fibers in site improves bone-tendon healing process while having a functional PCL restored. However, completely detached fragments with a tendency to form intra-articular loose bodies are debrided.

Here we presented a technical note that is the first description of Scorpion suture passer usefulness, as a user-friendly device in arthroscopy and in arthroscopic fixation of PCL avulsion in the literature. Further assessment of the technique needs a clinical trial study comparing the conventional open surgical procedure and the arthroscopic surgery in long term, considering the ethical concerns in this regard (13).

Footnote

Conflict of Interest: none.

References

- Kim SJ, Shin SJ, Choi NH, Cho SK. Arthroscopically assisted treatment of avulsion fractures of the posterior cruciate ligament from the tibia. *J Bone Joint Surg Am.* 2001;**83-A**(5):698-708. [PubMed: 11379739].
- Shino K, Nakata K, Mae T, Yamada Y, Shiozaki Y, Toritsuka Y. Arthroscopic fixation of tibial bony avulsion of the posterior cruciate ligament. *Arthroscopy.* 2003;**19**(2). E12. doi: 10.1053/jars.2003.50062. [PubMed: 12579141].
- Zhao J, He Y, Wang J. Arthroscopic treatment of acute tibial avulsion fracture of the posterior cruciate ligament with suture fixation technique through Y-shaped bone tunnels. *Arthroscopy.* 2006;**22**(2):172-81. doi: 10.1016/j.arthro.2005.10.020. [PubMed: 16458803].
- Yang CK, Wu CD, Chih CJ, Wei KY, Su CC, Tsuang YH. Surgical treatment of avulsion fracture of the posterior cruciate ligament and postoperative management. *J Trauma.* 2003;**54**(3):516-9. doi: 10.1097/01.TA.0000047048.37775.32. [PubMed: 12634532].
- Bali K, Prabhakar S, Saini U, Dhillon MS. Open reduction and internal fixation of isolated PCL fossa avulsion fractures. *Knee Surg Sports Traumatol Arthrosc.* 2012;**20**(2):315-21. doi: 10.1007/s00167-011-1618-6. [PubMed: 21761230].
- Seitz H, Schlenz I, Pajenda G, Vecsei V. Tibial avulsion fracture of the posterior cruciate ligament: K-wire or screw fixation? A retrospective study of 26 patients. *Arch Orthop Trauma Surg.* 1997;**116**(5):275-8. [PubMed: 9177803].
- Chen W, Tang D, Kang L, Ding Z, Sha M, Hong J. Effects of microendoscopy-assisted reduction and screw fixation through a single mini-incision on posterior cruciate ligament tibial avulsion fracture. *Arch Orthop Trauma Surg.* 2012;**132**(4):429-35. doi: 10.1007/s00402-011-1426-y. [PubMed: 22080931].
- Gui J, Wang L, Jiang Y, Wang Q, Yu Z, Gu Q. Single-tunnel suture fixation of posterior cruciate ligament avulsion fracture. *Arthroscopy.* 2009;**25**(1):78-85. doi: 10.1016/j.arthro.2008.08.011. [PubMed: 1911222].
- Kim SJ, Shin SJ, Cho SK, Kim HK. Arthroscopic suture fixation for bony avulsion of the posterior cruciate ligament. *Arthroscopy.* 2001;**17**(7):776-80. doi: 10.1053/jars.2001.22392. [PubMed: 11536101].

10. Gwinner C, Kopf S, Hoburg A, Haas NP, Jung TM. Arthroscopic Treatment of Acute Tibial Avulsion Fracture of the Posterior Cruciate Ligament Using the TightRope Fixation Device. *Arthrosc Tech.* 2014;**3**(3):e377-82. doi: [10.1016/j.eats.2014.02.005](https://doi.org/10.1016/j.eats.2014.02.005). [PubMed: [25126507](https://pubmed.ncbi.nlm.nih.gov/25126507/)].
11. Chen SY, Cheng CY, Chang SS, Tsai MC, Chiu CH, Chen AC, et al. Arthroscopic suture fixation for avulsion fractures in the tibial attachment of the posterior cruciate ligament. *Arthroscopy.* 2012;**28**(10):1454-63. doi: [10.1016/j.arthro.2012.04.141](https://doi.org/10.1016/j.arthro.2012.04.141). [PubMed: [22929009](https://pubmed.ncbi.nlm.nih.gov/22929009/)].
12. Martinez-Moreno JL, Blanco-Blanco E. Avulsion fractures of the posterior cruciate ligament of the knee. An experimental percutaneous rigid fixation technique under arthroscopic control. *Clin Orthop Relat Res.* 1988;**(237)**:204-8. [PubMed: [3191630](https://pubmed.ncbi.nlm.nih.gov/3191630/)].
13. Amouzadeh Omrani F, Kazemian G, Manafi Rasi A, Sarzaeem M, Khak M. Are Arthroscopic PCL Avulsion Fixation and its Long Learning Curve Morally Justified When Other Surgical Approaches are Valid? An Ethical Issue in Surgical Research. *J Orthop Spine Trauma.* 2017;**3**(1). e60943. doi: [10.5812/jost.60943](https://doi.org/10.5812/jost.60943).