



# Bilateral Pulmonary Artery Embolism Following Posterior Spinal Surgery

Kamran Mottaghi,<sup>1</sup> Farhad Safari,<sup>1</sup> Mohammad Hallajnejad,<sup>2</sup> and Masoud Nashibi<sup>1\*</sup>

<sup>1</sup>Anesthesiology Department, Loghman Hospital, Shahid Beheshti University of Medical Sciences, Tehran, IR Iran

<sup>2</sup>Neurosurgery Department, Loghman Hospital, Shahid Beheshti University of Medical Sciences, Tehran, IR Iran

\*Corresponding author: Masoud Nashibi, Loghman Hospital, Kamali Street, Kargar Ave, Tehran, IR Iran. P.O. Box: 13336-31151. Tel/Fax: +98-2155424040; +98-9128451648, E-mail: masoudnashibi@sbmu.ac.ir

Received 2016 December 26; Revised 2017 February 27; Accepted 2017 April 30.

## Abstract

**Introduction:** Lumbar spine laminectomy and spinal fixation are common procedures, associated with several recognized complications. Thromboembolic events have been reported during these types of procedures; although their incidence is low, the associated mortality is not.

**Case Presentation:** We present a 53-year-old woman with no medical history or risk factors for thromboembolic events, who underwent lumbar spine laminectomy and posterior spinal fixation. The clinical findings indicated the risk of pulmonary embolism following surgery, which was confirmed via capnography, arterial blood gas, electrocardiography, and computed tomography angiography.

**Conclusions:** Pulmonary embolism may be diagnosed, based on clinical findings and simple data provided by the analysis of vital signs and monitoring in the operating room.

**Keywords:** Spine Surgery, Pulmonary Embolism

## 1. Introduction

Lumbar spine laminectomy and spinal fixation are common procedures (1), associated with some recognized complications, such as postoperative infections (2), nerve root damage, dural tear (3), and pulmonary embolism (PE) (4), which can be fatal (5). The prevalence of thromboembolic events during these types of procedures ranges from 0% to 13% (6). Despite the low incidence of these events, the associated mortality is high (5).

Although there are many studies discussing the risk factors and incidence of PE (6), case reports are scarce (5). In this paper, we report a case of bilateral PE, which occurred after posterior lumbar spine fixation surgery in Loghman hospital, Tehran, Iran in 2016.

## 2. Case Presentation

The patient was a 53-year-old female, complaining of low back pain. She was a candidate for lumbar spine laminectomy and posterior spinal fixation due to a degenerative disease. She had no medical history and showed normal laboratory and electrocardiographic (ECG) findings. Accordingly, the cardiologist reported a low risk of

cardiac events. The patient's weight and height were 85 kg and 162 cm, respectively (BMI, 32.4 kg/m<sup>2</sup>).

Fentanyl (3 µg/kg/IV) and midazolam (0.03 mg/kg/IV) were injected as premedication. General anaesthesia was induced with propofol (2 mg/kg/IV), atracurium (0.5 mg/kg/IV), and lidocaine (1 mg/kg/IV). Anaesthesia was maintained with propofol infusion at a rate of 150 µg/kg/min/IV. Venous access was attained and an arterial line was inserted, while beat-to-beat blood pressure was being monitored.

Surgery started in the prone position. L4, L5, and S1 laminectomy was performed and pedicle screws were inserted in the vertebrae. After L4-L5 discectomy, anterior fusion with a lumbar cage and posterior fusion with rods were performed. Surgery continued for about 5 hours with 1200 mL of blood loss, which was compensated for with crystalloid fluids. The maximum allowable blood loss was 1400 mL for the patient. Blood pressure and heart rate were stable, and arterial blood gas (ABG) test was performed every 1.5 hours. The final ABG analysis was carried out 30 minutes before turning the patient back to the supine position; the results indicated satisfactory results (pH, 7.42; PaCO<sub>2</sub>, 46 mmHg; PaO<sub>2</sub>, 300 mmHg; BE, 4.1 mmol/L; HCO<sub>3</sub>,

29 mmol/L; and SaO<sub>2</sub>, 99%). The patient had a 400-mL urinary output.

At the end of the operation and reversal of muscle relaxants with neostigmine (0.06 mg/kg/IV) and atropine (0.02 mg/kg/IV), the patient was extubated; she opened her eyes and was responsive to verbal commands. The force of lower extremities was examined by the surgeon, which was acceptable. Three minutes later, the level of consciousness gradually decreased, and end-tidal CO<sub>2</sub> dropped from 35 to 12 mmHg on capnography.

Oxygen saturation dropped to 60%, whilst the expiratory tidal volume was about 550 mL in each breath with a respiratory rate of 25-30 bpm; the patient's blood pressure was 60/35 mmHg, and her heart rate was 45 bpm. She was intubated immediately and ventilated with a fraction of inspired oxygen (FiO<sub>2</sub>) of 1.0; nonetheless, the end-tidal CO<sub>2</sub> remained at 12 mmHg and SpO<sub>2</sub> was nearly 60%. ABG analysis showed mixed metabolic and respiratory acidosis (pH, 7.01; PaCO<sub>2</sub>, 81 mmHg; PaO<sub>2</sub>, 60 mmHg; BE, 10 mmol/L; and HCO<sub>3</sub>, 20.9 mmol/L).

The surgeon suspected screw dislodgement and blood loss; accordingly, 1 unit of packed red blood cells was transfused, and diagnostic peritoneal lavage was performed instantly, which was negative. However, PE was suspected due to the large gap between the end-tidal CO<sub>2</sub> and arterial PCO<sub>2</sub>. Moreover, despite satisfactory ventilation and acceptable tidal volume with FiO<sub>2</sub> of 1.0, low PaO<sub>2</sub> and low SpO<sub>2</sub> were detected. Then, 100 mEq of sodium bicarbonate was infused to compensate for metabolic acidosis and increase minute ventilation to compensate for respiratory acidosis. The results of ABG analysis improved (pH, 7.32; PaCO<sub>2</sub>, 45 mmHg; PaO<sub>2</sub>, 119 mmHg; BE, -2.4 mmol/L; and HCO<sub>3</sub>, 23.8 mmol/L), and ECG findings showed the SIQ3T3 pattern (Figure 1).

The patient's hemodynamic indices did not change; therefore, 10 µg of intravenous epinephrine was used, which had a transient effect. On the other hand, bradycardia with a heart rate as low as 35 bpm occurred. It was treated with the injection of epinephrine (100 µg) and 1 minute of chest compression, followed by intravenous epinephrine infusion (10 µg/min), which gradually decreased to 3 µg/min as hemodynamic indices became stable. Blood pressure, heart rate, and end-tidal CO<sub>2</sub> increased to 135/75 mmHg, 120 bpm, and 25 mmHg, respectively.

The ABG findings were as follows: pH, 7.23; PaCO<sub>2</sub>, 62 mmHg; PaO<sub>2</sub>, 88 mmHg; BE, -1.5 mmol/L, HCO<sub>3</sub>, 26.2 mmol/L; and SaO<sub>2</sub>, 94.5%. The patient's level of consciousness increased gradually. She opened her eyes and became agitated; accordingly, 50 µg of intravenous fentanyl was injected. After achieving adequate sedation with stable blood pressure and heart rate, spiral CT scan-angiography was performed, which showed stable and fixed screws

without any dislodgement, bilateral pulmonary artery embolism (Figures 2A and 2B), right ventricular enlargement, and leftward shift of the interventricular septum (Figure 2C).

The patient was transferred to the intensive care unit (ICU). Before starting a pharmacological therapy, protein C and protein S were measured in the plasma, which were found to be normal; then, anticoagulant therapy was started. Doppler ultrasound was requested, which confirmed our diagnosis by showing thrombi in deep veins below the knees of both legs. On the next day in the ICU, left-sided mydriasis and right hemiplegia were found on physical examination. On brain CT scan, ischemic lesions were evident in the left cerebral hemisphere with a midline shift. Despite medical therapy and close monitoring, brain death was confirmed on the fourth day, and the patient was referred for organ harvesting and donation.

### 3. Discussion

PE is well recognized in surgeries involving the bones (7, 8). PE after spinal surgery could occur due to bone marrow debris (1), thrombosis, septic embolism (9), and cement embolism (10), which are not common but fatal (5). It could be secondary to deep vein thrombosis (DVT) (6), which is related to vessel wall injury, blood pooling, and coagulation disorders (11).

Many reviews have attempted to find the risk factors for venous thromboembolism and PE in spinal surgeries. Charen et al. showed that general anaesthesia could be a risk factor for PE in orthopaedic procedures on large joints; however, general anaesthesia is mandatory in spinal surgeries (7). Moreover, Yoshika et al. proposed spinal tumours, neurological deficit, and advanced age as risk factors for venous thromboembolism in spinal surgeries (12).

Masuda et al. introduced older age, long duration of anaesthesia, and spinal trauma as risk factors for PE in spinal surgery, whilst Shoefeld et al. proposed BMI above 40 kg/m<sup>2</sup>, age above 80 years, surgery duration more than 261 minutes, and male gender as the predictors of PE. They suggested that some modifications in prophylaxis protocols and surgical manipulations might be required (13). Moreover, Hohl et al. found that extensive surgery, specifically fusion of 5 segments or more, can expose the patient to a greater risk of PE (14).

Clinical presentations are not reliable for diagnosis of PE; therefore, diagnostic tools are required to approve clinical suspicions. Ventilation-perfusion scan has been used as a reliable tool, although it has shown certain limitations. Today, spiral CT scan is the gold standard for diagnosis (11). The most common cause of PE in spinal surgery

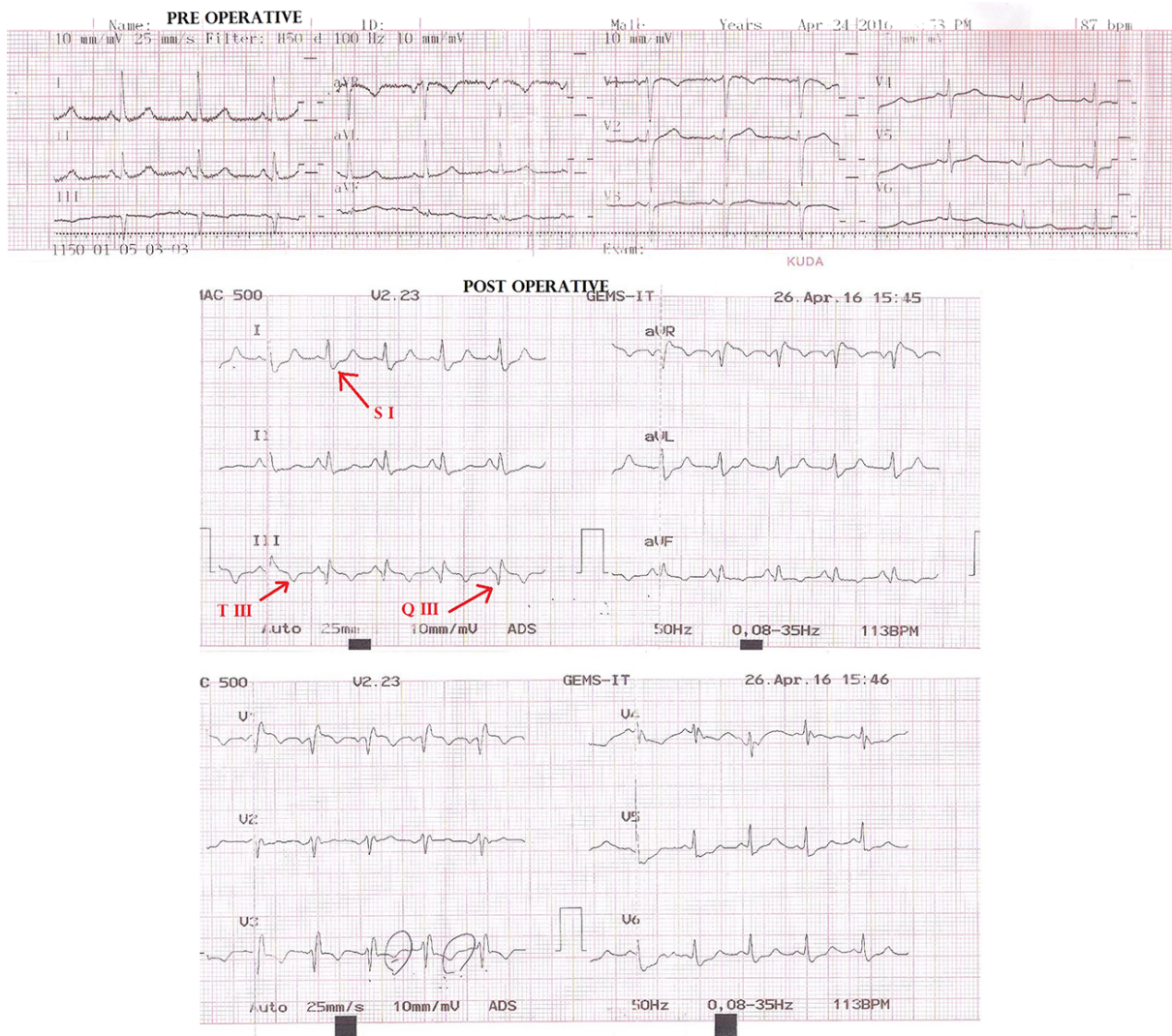


Figure 1. The ECG Findings (Preoperative, Upper Trace; Postoperative, Middle and Lower Traces)

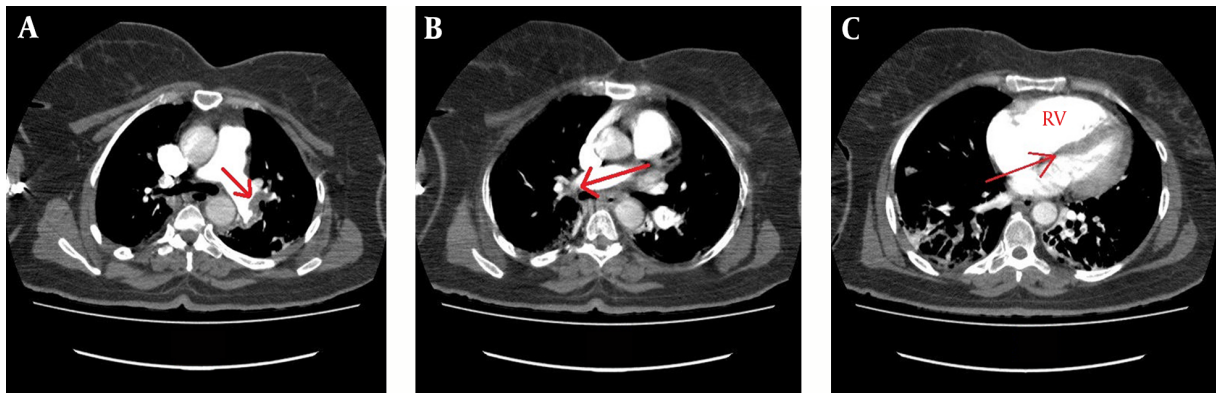
is cement embolism during kyphoplasty (9, 10). Takahashi suggested that insertion of spinal implants, particularly pedicle screws, could cause intraoperative PE with a mechanism similar to that of rod fixation into the intramedullary canal of a long bone (15).

Venous stasis in lower extremities is another cause of embolism, as well as a major risk factor for embolism in obese patients. Schizas et al. showed that lower-limb DVT was the main cause of thrombi, causing PE in spinal surgeries, whereas prophylaxis with low-molecular-weight heparin did not reduce the risk of PE in these patients (6). On the other hand, Yoshioka et al. reported that 60% of PE cases occurred with no DVT. This finding is in

line with a study by Buchl et al. which showed that screening via preoperative ultrasound of lower-limb deep veins, is not effective in preventing PE during spinal surgery (12).

Considering the relatively low prevalence of PE in spinal surgery and the additional risk of hematoma formation, routine use of pharmacological prophylaxis for PE is not supported and its efficacy and safety are controversial (16). It seems that vigilance and preparedness are essential to reliable and accessible prophylaxis. In our case, clinical presentations, especially the wide gap between arterial PCO<sub>2</sub> and end-tidal CO<sub>2</sub>, besides hypoxia refractory to supplemental oxygen (which reflected a significant dead space added to the respiratory system) provided inval-





**Figure 2.** A, The Filling Defect in the Left Main Pulmonary Artery, Indicating a Massive embolism; B, the Filling Defect in the Right Main Pulmonary Artery, Indicating a Massive Embolism; C, Right Ventricular (RV) Enlargement and Leftward Shift of the Interventricular Septum.

able evidence of the great risk of PE.

ECG findings are of great importance in the diagnosis of PE; as in the present case, a newly emerged pattern of S1Q3T3 was detected. Diagnosis was confirmed with spiral CT scan-angiography, which showed bilateral obstruction of pulmonary arteries and leftward displacement of the interventricular septum, reflecting great pulmonary artery pressure.

### 3.1. Conclusions

The large gap between end-tidal CO<sub>2</sub> and arterial CO<sub>2</sub> is useful in the diagnosis of massive PE. This could be determined via capnography not only during intubation, but also after extubation with a facemask and spontaneous ventilation, similar to our case. ECG findings could help diagnose PE and rule out differential diagnoses, such as acute coronary syndrome. Intermittent pneumatic compression therapy should be considered for obese patients and long operations. Moreover, transesophageal echocardiography during surgery may help anaesthesiologists diagnose or rule out PE.

### Footnotes

**Funding/Support:** The authors declare that they do not have any financial relationships with any organization.

**Conflict of Interest:** The authors declare that they have no conflicts of interest.

### References

1. Stundner O. Pulmonary complications after spine surgery. *World J Orthoped.* 2012;**3**(10):156. doi: [10.5312/wjo.v3.i10.156](https://doi.org/10.5312/wjo.v3.i10.156).
2. Lee JJ, Odeh KI, Holcombe SA, Patel RD, Wang SC, Goulet JA, et al. Fat Thickness as a Risk Factor for Infection in Lumbar Spine Surgery. *Orthopedics.* 2016;**39**(6):e1124-8. doi: [10.3928/01477447-20160819-05](https://doi.org/10.3928/01477447-20160819-05).

3. Choi DJ, Jung JT, Lee SJ, Kim YS, Jang HJ, Yoo B. Biportal Endoscopic Spinal Surgery for Recurrent Lumbar Disc Herniations. *Clin Orthope Surg.* 2016;**8**(3):325. doi: [10.4055/cios.2016.8.3.325](https://doi.org/10.4055/cios.2016.8.3.325).
4. Kim HJ, Kepler C, Cunningham M, Rawlins B, Boachie-Adjei O. Pulmonary Embolism in Spine Surgery. *Spine.* 2011;**36**(2):177-9. doi: [10.1097/BRS.0b013e318cb4717](https://doi.org/10.1097/BRS.0b013e318cb4717).
5. Tang S. Pulmonary embolism after a single-stage, combined anterior and posterior approach lumbar surgery. *Pak J Med Sci.* 2013;**29**(6). doi: [10.12669/pjms.296.3668](https://doi.org/10.12669/pjms.296.3668).
6. Schizas C, Neumayer F, Kosmopoulos V. Incidence and management of pulmonary embolism following spinal surgery occurring while under chemical thromboprophylaxis. *Eur Spine J.* 2008;**17**(7):970-4. doi: [10.1007/s00586-008-0668-z](https://doi.org/10.1007/s00586-008-0668-z).
7. Charen DA, Qian ET, Hutzler LH, Bosco JA. Risk factors for post-operative venous thromboembolism in orthopaedic spine surgery, hip arthroplasty, and knee arthroplasty patients. *Bull Hosp Jt Dis.* 2015;**73**(3):198-203.
8. Manafi Rasi A, Kazemian G, Emami Moghadam M, Tavakoli Larestani R, Fallahi A, Nematy A, et al. Deep Vein Thrombosis Following Below Knee Immobilization : The Need for Chemoprophylaxis. *Trauma Mon.* 2013;**17**(4):367-9. doi: [10.5812/traumamon.9158](https://doi.org/10.5812/traumamon.9158).
9. Karthik K, Shetty AP, Rajasekaran S. Intraoperative Life Threatening Acute Lung Injury Due to Multiple Septic Pulmonary Emboli during Transpedicular Biopsy and Kyphoplasty. *Asian Spine J.* 2014;**8**(2):197. doi: [10.4184/asj.2014.8.2.197](https://doi.org/10.4184/asj.2014.8.2.197).
10. Focardi M, Bonelli A, Pinchi V, De Luca F, Norelli GA. Pulmonary Cement Embolism After Kyphoplasty. *J Forensic Sci.* 2016;**61**(S1).
11. Kim HJ, Walcott-Sapp S, Adler RS, Pavlov H, Boachie-Adjei O, Westrich GH. Thromboembolic Complications Following Spine Surgery Assessed with Spiral CT Scans. *HSS J.* 2010;**7**(1):37-40. doi: [10.1007/s11420-010-9179-7](https://doi.org/10.1007/s11420-010-9179-7).
12. Yoshioka K, Murakami H, Demura S, Kato S, Hayashi H, Inoue K, et al. Comparative Study of the Prevalence of Venous Thromboembolism After Elective Spinal Surgery. *Orthopedics.* 2013;**36**(2):e223-8. doi: [10.3928/01477447-20130122-26](https://doi.org/10.3928/01477447-20130122-26).
13. Masuda K, Chikuda H, Yasunaga H, Hara N, Horiguchi H, Matsuda S, et al. Factors affecting the occurrence of pulmonary embolism after spinal surgery: data from the national administrative database in Japan. *Spine J.* 2012;**12**(11):1029-34. doi: [10.1016/j.spinee.2012.10.020](https://doi.org/10.1016/j.spinee.2012.10.020).
14. Hohl JB, Lee JY, Rayappa SP, Nabb CE, Devin CJ, Kang JD, et al. Prevalence of Venous Thromboembolic Events After Elective Major Thoracolumbar Degenerative Spine Surgery. *J Spinal Disord Techniques.* 2015;**28**(5):E310-5. doi: [10.1097/BSD.0b013e31828b7d82](https://doi.org/10.1097/BSD.0b013e31828b7d82).

15. Takahashi S, Kitagawa H, Ishii T. Intraoperative pulmonary embolism during spinal instrumentation surgery. *J Bone Joint Surg.* 2003;**85**(1):90-4. doi: [10.1302/0301-620X.85B1.13172](https://doi.org/10.1302/0301-620X.85B1.13172).
16. Namboothiri S. Incidence of deep vein thrombosis after major spine surgeries with no mechanical or chemical prophylaxis. *Evid Base Spine Care J.* 2012;**3**(3):29-33.