



Effects of Right Hepatic Artery Ligation

Abdolhossein Davoodabadi,^{1,2} Esmail Abdourrahimkashi,^{1,2,*} Tahereh Khomehchian,³ Hossein Akbari,⁴ Mehdi Alizadeh,^{1,2} Mehrdad Hosseinpour,^{1,2} and Esmail Fakharian⁵

¹Department of General Surgery, Faculty of Medicine, Kashan University of Medical Sciences, Kashan, IR Iran

²Trauma Research Center, Kashan University of Medical Sciences, Kashan, IR Iran

³Department of Pathology Kashan University of Medical Sciences, Kashan, IR Iran

⁴Department of Biostatistics and Epidemiology, Social Determinants of Health (SDH) Research Center, Kashan University of Medical Sciences, Kashan, IR Iran

⁵Department of Neurosurgery, Kashan University of Medical Sciences, Trauma Research Center, Kashan, IR Iran

*Corresponding author: Esmail Abdourrahimkashi, Department of General Surgery, Faculty of Medicine, Kashan University of Medical Sciences, Kashan, IR Iran. E-mail: eakashi@gmail.com

Received 2017 January 11; Revised 2017 March 26; Accepted 2017 May 30.

Abstract

Background: Injury to right hepatic artery (RHA) may occur during hepatobiliary operative procedures. Although it may not be detected and is clinically silent in most of the cases, liver abscess, bleeding, hemobilia, and right hepatic lobe ischemia needing surgical excision have been reported. The aim of this study was a more detailed evaluation of hepatic consequences following RHA injury in an animal model.

Methods: This study was conducted on 20 New Zealand rabbits 6 months of age. Blood samples for the measurement of hepatic enzymes was obtained from the rabbits before ligation of the hepatic artery. After 10 days, blood sampling was repeated and the animals were killed and 0.5×2 cm liver wedge biopsy was prepared from right lateral lobe, the distribution area of RHA. P values of < 0.05 were considered significant.

Results: Laboratory data before and after surgical intervention showed serum bilirubin of 0.133 ± 0.044 and 0.135 ± 0.042 , respectively (P value = 0.47). Serum alkaline phosphatase (ALP) was 122.4 ± 44.12 and 122.8 ± 44.43 , (P value = 0.36) respectively. Serum glutamic-pyruvic transaminase (SGPT) was 31.2 ± 5.34 and 86.2 ± 33.9 , (P value = 0.001) respectively. Serum glutamic oxaloacetic transaminase (SGOT) was 30.13 ± 8.46 and 69.4 ± 47.7 , respectively (P value = 0.001). Laparotomy showed no considerable change in median lobe of livers, except mild necrosis in one (5%) rabbit. Severe necrosis was found in the right lateral lobe of 15 rabbits (75%), moderate necrosis in 3 (15%), and mild necrosis in 2 (10%) cases. No abscess or gangrene was found. The Gall bladder was intact in all animals.

Conclusions: The RHA obliteration causes an increase in liver enzymes and considerable right lateral hepatic lobe necrosis (75%) but no liver abscess, gangrene or gall bladder abnormality.

Keywords: Right Hepatic Artery Ligation, Hepatic Complications, Animal Study, Segmental Hepatic Necrosis

1. Background

Injury to the right hepatic artery (RHA) is an important complication of hepatobiliary surgery (1, 2). In animal studies, disruption of RHA usually has not led to acute and significant complications and have been well tolerated when antibiotics were used (3, 4). Although accidental interruption of the right hepatic artery has no considerable hepatic necrosis, transient changes in SGOT and temporary low grade bilirubinemia are reported (5). However, accidental interruption of the hepatic artery or one of its principal branches may result in severe surgical complications, such as liver abscess, bleeding, hemobilia, and right hepatic lobe ischemia (6) requiring right hepatectomy or even may cause acute liver failure, for which liver trans-

plantation in 2 cases was reported (7, 8).

These controversies about the consequences of obliteration of the right hepatic artery when considering the high frequency of hepatobiliary operations, mandates further detailed research with animal models.

The rabbit liver is morphologically similar to that of humans in its arterial blood supply (9), and so is selected for this animal study to obtain information about liver enzyme changes and hepatic consequences of RHA closure.

2. Methods

After approval of the proposal by the ethics committee for animal research of Kashan University of Medical Sciences (KAUMS), this experimental study was conducted at

the anatomy research center of KAUMS on 20 New Zealand rabbits with 6 months of age. Before the procedure, blood samples were obtained from a peripheral vein to measure hepatic enzymes, as a baseline. Next, laparotomy and ligation of right hepatic artery was performed. After 10 days, before re-operation, blood sampling was repeated. During abdominal re-exploration, different parts of the liver were evaluated and a wedge biopsy of 0.5×2 cm was removed from suspected parts and sent for histopathologic examination for detection of possible ischemia or necrosis. After laparotomy, rabbits were exanimated.

2.1. Technique

In this animal study, 20 New Zealand white female rabbits with 6 months of age (1.2 ± 0.3 kg) were selected. The rabbits were kept in a controlled environment with an ambient room temperature of 24°C and artificial illumination (12 hours light-dark cycle) for at least 2 days before starting the experiment. They were fasted for 4 hours before the laparotomy, yet had free access to tap water. General anesthesia was induced by intravenous injection of ketamine hydrochloride (35 mg per Kg) in para-spinal muscles accompanied by oxygen at 0.5 L/minute. Hairs of surgical site were shaved and the skin was disinfected with 2% iodine tincture and positioned in supine position. The feet were fixed to the surgical Table. After preparation, the liver was exposed through a 6-cm midline abdominal incision and right hepatic artery dissected and ligated with 4-0 silk sutures (Figures 1 and 2). Then, the abdominal wall fascia and subcutaneous tissue were separately closed with absorbable monofilament suture in an identical manner.

After the operation, when the animals were stabilized, they were transferred to the animal care unit. During the first 5 days, 20 mL/kg of cefazolin was administered IM. Rabbits were under close observation for 10 days and then underwent second laparotomy. The liver was evaluated and a wedge, 5×2 cm, was biopsied from any abnormal area, especially right lateral lobe (distribution of RHA) for evaluation of ischemia or necrosis (Figure 2).

2.2. Statistical Analysis

SPSS 11 software statistical comparisons were made between discrete variables with Fisher's exact test. P values of less than 0.05 were considered significant.

3. Results

Blood samples were obtained before right hepatic artery ligation (RHAL) and 10 days after the procedure, just before re-exploration, and are presented as mean and standard deviation and include serum bilirubin of 0.133

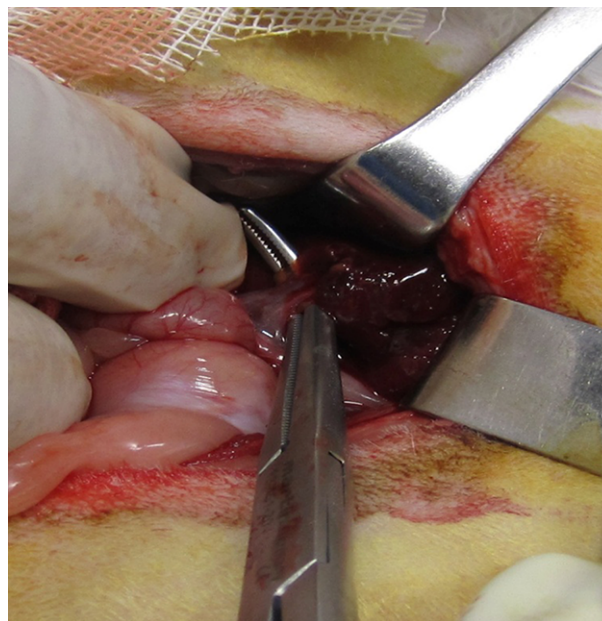


Figure 1. Isolated Right Hepatic Artery

± 0.044 and 0.135 ± 0.042 , respectively (P value = 0.47); serum alkaline phosphates (ALP) was 122.8 ± 4.43 and 86.2 ± 33.9 (P value = 0.36), Serum glutamic pyruvic transaminase (SGPT) was 31.2 ± 5.34 and 86.2 ± 33.9 (P value = 0.001), and serum glutamic oxaloacetic transaminase (SGOT) was 30.13 ± 8.46 and 69.4 ± 47.7 (P value = 0.001), respectively. In the second laparotomy, there was no considerable abnormality in median lobe of the liver of the rabbits, except for mild necrosis in 1 rabbit (Figure 3). Ischemic necrosis was found in the right lateral lobe of all rabbits, which was severe, although viable, in 15 (75%) cases (Figure 4), and moderate and mild in 2 and 3 cases, respectively (Figures 5, 6, 7, 8 and 9). Gall bladder and other parts of hepatobiliary system were normal. No hepatic abscess formation and segmental gangrene needing surgical resection occurred during the course of observation. All animals were afebrile and looking healthy, without icterus or confusion, as well.

3.1. Statistical Analysis

Statistical comparisons were made between discrete variables using Fisher's exact test, and statistical analyses were performed using SPSS 11 software. P values of less than 0.05 were considered significant.

4. Discussion

The most important consequence of RHA ligation in the current study was severe ischemic necrosis, that oc-

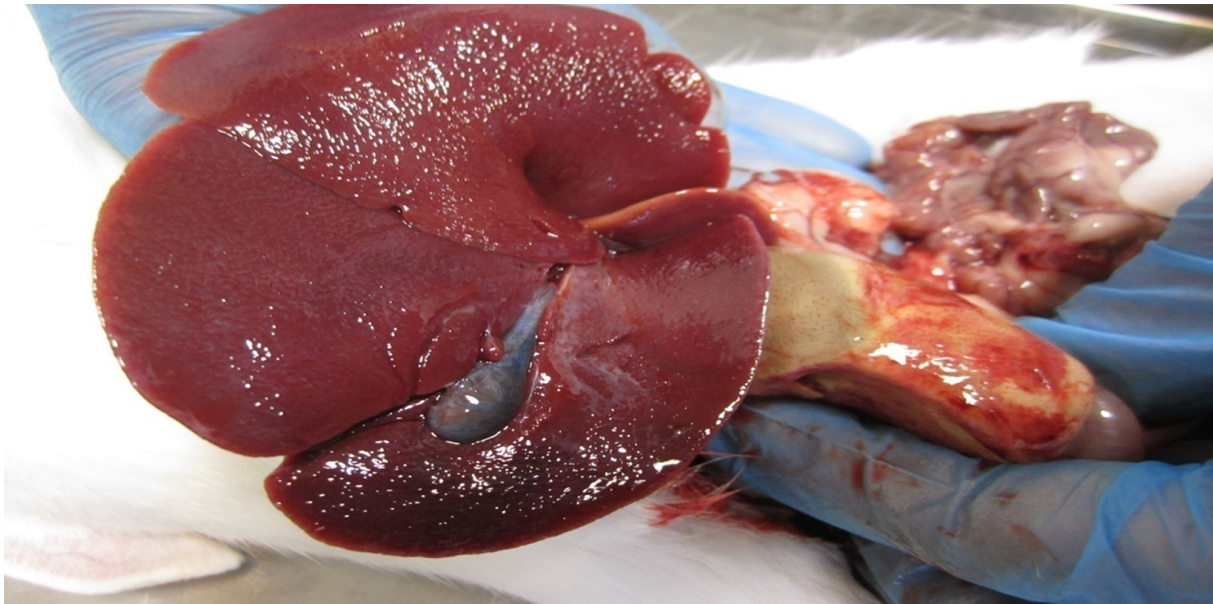


Figure 2. Severe Necrosis of Lateral Lobe in Distribution of RHA

Table 1. Assessment of Hepatic Pathology After Right Hepatic Artery Ligation^a

Pathology Finding	No Change	Mild Necrosis	Moderate Necrosis	Severe Necrosis	Abscess	Gangrene
Right medial lobe	n = 20 (100)	n = 1 (5)	0	0	0	0
Right lateral lobe	0 (0)	2 (10)	3 (20)	15 (75)	0	0
Total	20	3	3	15	0	0

^aValues are expressed as No. (%).

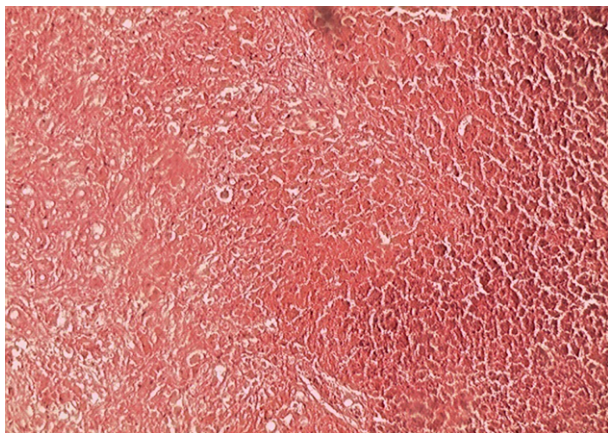


Figure 3. Photomicrograph of Liver Showing Severe Ischemic Necrosis

curred in 75% of rabbits' right lateral lobe (RLL). Although this is considerable, because most of the blood is supplied

to the right lateral lobe by the right hepatic artery, no abscess formation or gangrene appeared in the animals. The same may happen in human livers after similar injuries, because usually there is no need for segmental hepatic resection (RLL), and finally there is uneventful segmental atrophic changes (10). Less commonly, RLL ischemia may progress and convert to liver abscess or sepsis. Therefore, it may be recommended to ignore primary biliary repair after ligation of the RHA on a healthy liver, because it has no abnormal clinical presentation in most cases (8, 11-13).

Selective RHA ligation may have some therapeutic role in management of liver trauma (13, 14). Right hepatic artery ligation is reported in patients with severe liver trauma (grade 4 and 5) (15, 16) and hemodynamic instability, which requires perihepatic packing with a Pringle maneuver to stop arterial bleeding (16). In these patients because in the first operation anatomic resection is rarely tolerated (17), if hepatic segments are located in distribution of RHA (the vast majority of segment 5 and some neighboring areas, segment 6) (18, 19) selective vascular isola-

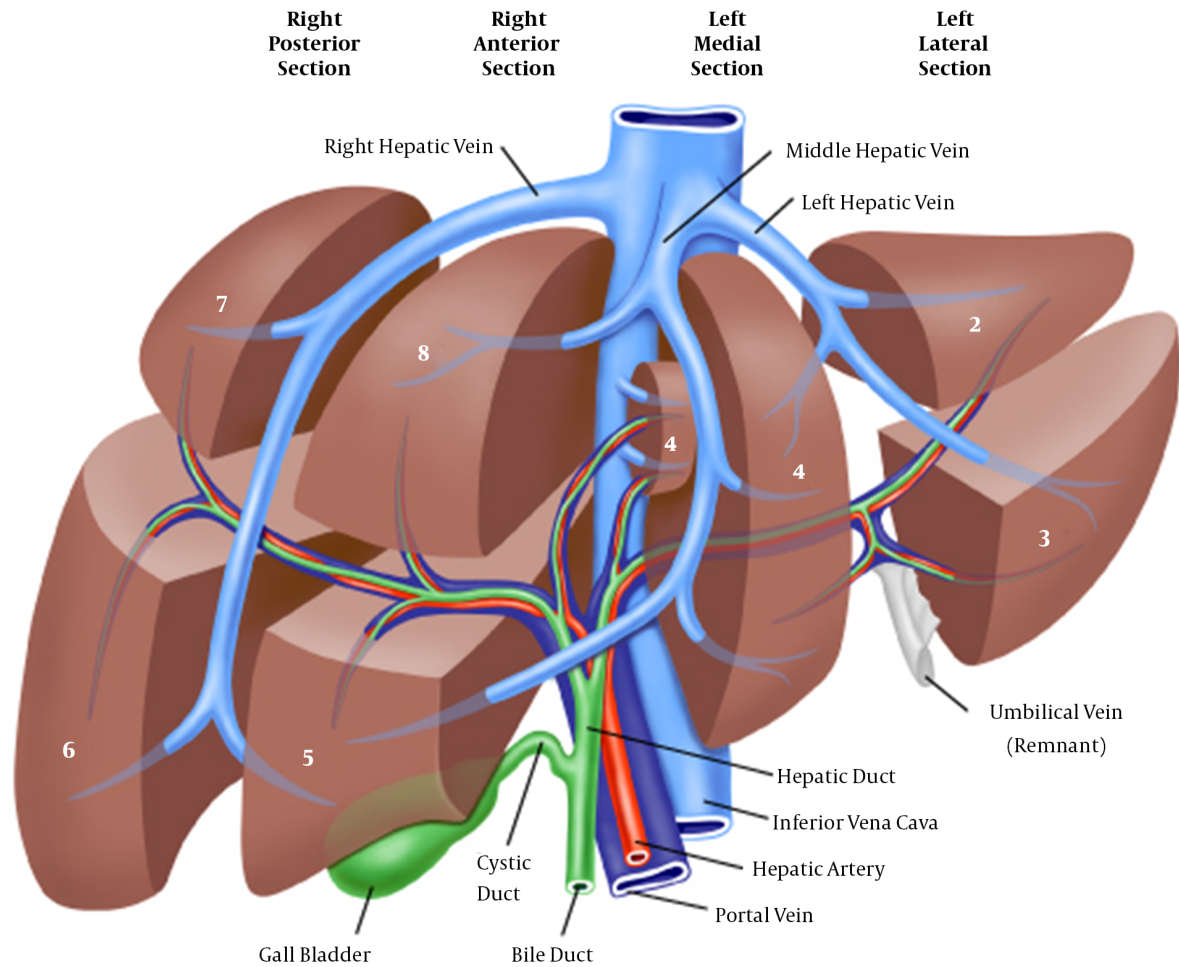


Figure 4. Couinaud's liver segments (I through VIII) numbered in a clockwise manner. The left lobe includes segments II to IV, the right lobe includes segments V to VIII, and the caudate lobe is segment I. IVC = inferior vena cava.

tion and ligation may be used for controlling bleeding (Figure 5). This option might enable anatomic resection at a later stage. Arterial embolization of RHA in hepatocellular carcinoma or treatment of specific pathologies, such as liver hemangioma, have produced appropriate options for patients, for whom surgical or percutaneous ablative treatment is contra-indicated (20). Therefore, embolization of RHA may cause liver segmental lobe ischemia and only necrosis. If confined to RHA, this part of the liver becomes atrophic and defunctionalized.

In Mathison's study, (RHA) injury with collateral flow from left hepatic artery, leads only to atrophy of the right liver (21).

Para-clinical data in this animal study showed that the enzymatic changes occurring most commonly were SGOT

and SGPT elevation up to 3 folds of the normal range without change in bilirubin and serum alkaline phosphates (ALP). Therefore, when encountered with RHA interruption, the levels of SGOT and SGPT should be more precisely considered, and normal levels of bilirubin and ALP would not rule out the RHA interruption.

The SGOT and SGPT are useful biomarkers of liver injury in a patient with some degree of intact liver function. The SGOT similar to SGPT is associated with liver parenchymal cells function. Although it is raised in acute liver damage, yet is also present in red blood cells, cardiac and skeletal muscle, and thus is not specific for the liver (15, 22).

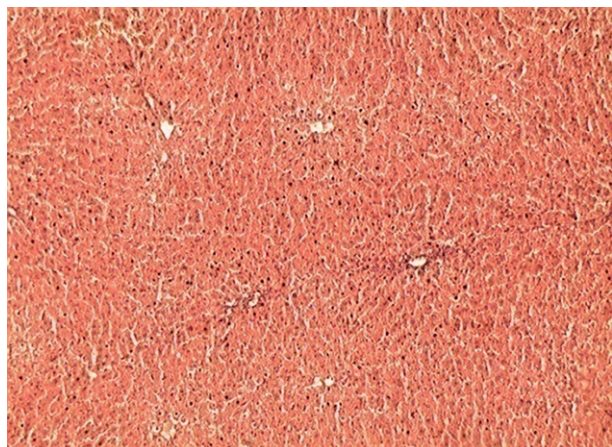


Figure 5. Photomicrograph of Liver Showing Normal Tissue

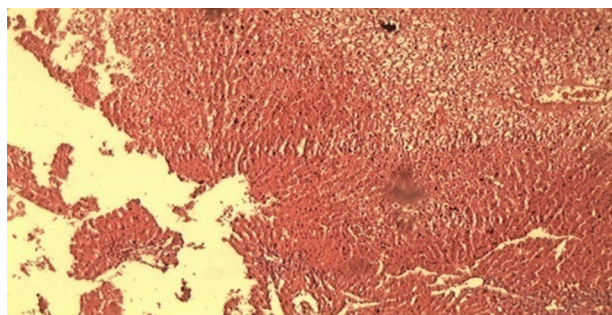


Figure 6. Photomicrograph of Liver Showing Mild Ischemic Tissue

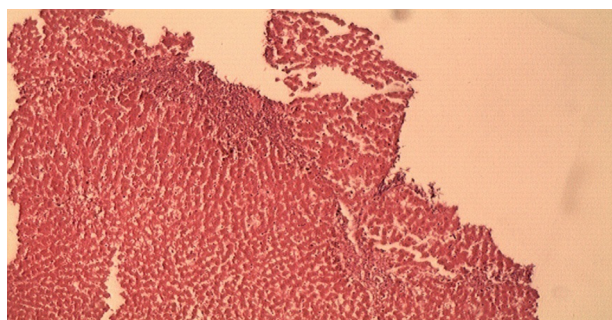


Figure 7. Photomicrograph of Liver Showing Mild Necrosis

4.1. Conclusion

The RHA damage during hepatobiliary surgery, treated with ligation, causes an increase of liver enzymes, SGOT and SGPT near 3 folds of normal without any change in bilirubin and ALP. Confronting RHA injury immediate ligation of the injured vessel may be life saving, and necrosis

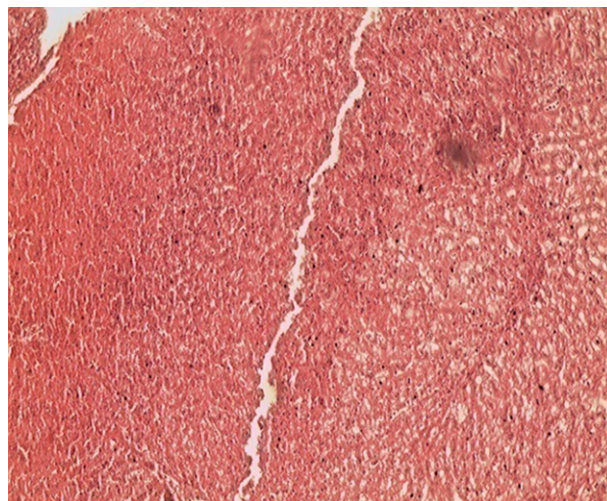


Figure 8. Photomicrograph of Liver Showing Moderate Necrosis

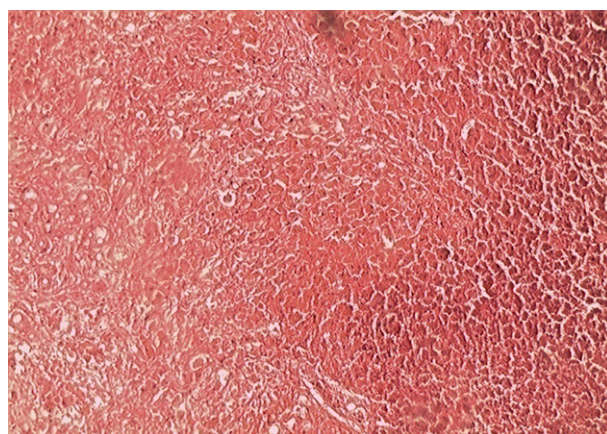


Figure 9. Photomicrograph of Liver Showing Severe Ischemic Necrosis

in right hepatic segment will not need segmental hepatic resection. Intended RHA occlusion may be favorable for treatment of HCC, hemangioma, and hemodynamically unstable liver trauma (grade 4 and 5) in distribution of RHA.

Acknowledgments

The authors wish to thank the animal laboratory personnel of Kashan University of Medical Sciences.

Footnotes

Authors' Contribution: Abdolhossein Davoodabadi, Esmail Abdourrahimkashi, Mehrdad Hosseinpour; Mehdi Al-

izadeh were the principal investigators of the study. Abdolhossein Davoodabadi also participated in drafting of the manuscript. Hossein Akbari performed the biostatistics analysis and Tahereh Khamehchian did the pathological assessments.

Funding/Support: This study was part of a thesis conducted at Kashan University of Medical Sciences with the cooperation of the animal laboratory of the university. This project was funded by Kashan University of Medical Sciences.

References

- Halasz NA. Cholecystectomy and hepatic artery injuries. *Arch Surg.* 1991;**126**(2):137-8. doi: [10.1001/archsurg.1991.01410260021002](https://doi.org/10.1001/archsurg.1991.01410260021002). [PubMed: 1992990].
- Madariaga JR, Dodson SF, Selby R, Todo S, Iwatsuki S, Starzl TE. Corrective treatment and anatomic considerations for laparoscopic cholecystectomy injuries. *J Am Coll Surg.* 1994;**179**(3):321-5. [PubMed: 8069429].
- Bengmark S, Rosengren K. Angiographic study of the collateral circulation to the liver after ligation of the hepatic artery in man. *Am J Surg.* 1970;**119**(6):620-4. doi: [10.1016/0002-9610\(70\)90228-X](https://doi.org/10.1016/0002-9610(70)90228-X). [PubMed: 5445983].
- Mays ET, Wheeler CS. Demonstration of collateral arterial flow after interruption of hepatic arteries in man. *N Engl J Med.* 1974;**290**(18):993-6. doi: [10.1056/NEJM197405022901804](https://doi.org/10.1056/NEJM197405022901804). [PubMed: 4594527].
- Brittain RS, Marchioro TL, Hermann G, Waddell WR, Starzl TE. Accidental Hepatic Artery Ligation in Humans. *Am J Surg.* 1964;**107**:822-32. doi: [10.1016/0002-9610\(64\)90169-2](https://doi.org/10.1016/0002-9610(64)90169-2). [PubMed: 14169009].
- Stewart L, Way LW. Bile duct injuries during laparoscopic cholecystectomy. Factors that influence the results of treatment. *Arch Surg.* 1995;**130**(10):1123-8. discussion 1129. doi: [10.1001/archsurg.1995.01430100101019](https://doi.org/10.1001/archsurg.1995.01430100101019). [PubMed: 7575127].
- Bacha EA, Stieber AC, Galloway JR, Hunter JG. Non-biliary complication of laparoscopic cholecystectomy. *Lancet.* 1994;**344**(8926):896-7. doi: [10.1016/S0140-6736\(94\)92873-8](https://doi.org/10.1016/S0140-6736(94)92873-8). [PubMed: 7916434].
- Schmidt SC, Settmacher U, Langrehr JM, Neuhaus P. Management and outcome of patients with combined bile duct and hepatic arterial injuries after laparoscopic cholecystectomy. *Surgery.* 2004;**135**(6):613-8. doi: [10.1016/j.surg.2003.11.018](https://doi.org/10.1016/j.surg.2003.11.018). [PubMed: 15179367].
- Stamatova-Yovcheva K, Dimitrov R, Yonkova P, Chaprazov T, Yovchev D, Fejzulla F. Anatomical radiological features of abdominal aorta and some of its branches in the rabbit in the segment Th12-L3. *Int J Res Engin Appl Sci.*
- Robles Campos R, Marin Hernandez C, Fernandez Hernandez JA, Sanchez Bueno F, Ramirez Romero P, Pastor Perez P, et al. [Delayed right hepatic artery haemorrhage after iatrogenic gallbladder by laparoscopic cholecystectomy that required a liver transplant due to acute liver failure: clinical case and review of the literature]. *Cir Esp.* 2011;**89**(10):670-6. doi: [10.1016/j.ciresp.2011.07.002](https://doi.org/10.1016/j.ciresp.2011.07.002). [PubMed: 21880307].
- Alves A, Farges O, Nicolet J, Watrin T, Sauvanet A, Belghiti J. Incidence and consequence of an hepatic artery injury in patients with post-cholecystectomy bile duct strictures. *Ann Surg.* 2003;**238**(1):93-6. doi: [10.1097/01.sla.0000074983.39297.c5](https://doi.org/10.1097/01.sla.0000074983.39297.c5). [PubMed: 12832970].
- Buell JF, Cronin DC, Funaki B, Koffron A, Yoshida A, Lo A, et al. Devastating and fatal complications associated with combined vascular and bile duct injuries during cholecystectomy. *Arch Surg.* 2002;**137**(6):703-8. discussion 708-10. doi: [10.1001/archsurg.137.6.703](https://doi.org/10.1001/archsurg.137.6.703). [PubMed: 12049542].
- Gurusamy KS, Sheth H, Kumar Y, Sharma D, Davidson BR. WITHDRAWN: Methods of vascular occlusion for elective liver resections. *Cochrane Database Syst Rev.* 2009;(1). CD006409. doi: [10.1002/14651858.CD006409.pub3](https://doi.org/10.1002/14651858.CD006409.pub3). [PubMed: 19160283].
- Flint LJ, Polk HJ. Selective hepatic artery ligation: limitations and failures. *J Trauma.* 1979;**19**(5):319-23. doi: [10.1097/00005373-197905000-00003](https://doi.org/10.1097/00005373-197905000-00003). [PubMed: 448766].
- Johnston DE. Special considerations in interpreting liver function tests. *Am Fam Physician.* 1999;**59**(8):2223-30. [PubMed: 10221307].
- Pringle JH. V. Notes on the Arrest of Hepatic Hemorrhage Due to Trauma. *Ann Surg.* 1908;**48**(4):541-9. doi: [10.1097/00000658-190810000-00005](https://doi.org/10.1097/00000658-190810000-00005). [PubMed: 17862242].
- Latifi R, Khalaf H. Selective vascular isolation of the liver as part of initial damage control for grade 5 liver injuries: Shouldn't we use it more frequently? *Int J Surg Case Rep.* 2015;**6C**:292-5. doi: [10.1016/j.ijscr.2014.12.021](https://doi.org/10.1016/j.ijscr.2014.12.021). [PubMed: 25569195].
- Bismuth H. Surgical anatomy and anatomical surgery of the liver. *World J Surg.* 1982;**6**(1):3-9. doi: [10.1007/BF01656368](https://doi.org/10.1007/BF01656368). [PubMed: 7090393].
- Couinaud C. [Liver lobes and segments: notes on the anatomical architecture and surgery of the liver]. *Presse Med.* 1954;**62**(33):709-12. [PubMed: 13177441].
- Murata S, Mine T, Ueda T, Nakazawa K, Onozawa S, Yasui D, et al. Transcatheter arterial chemoembolization based on hepatic hemodynamics for hepatocellular carcinoma. *ScientificWorldJournal.* 2013;**2013**:479805. doi: [10.1155/2013/479805](https://doi.org/10.1155/2013/479805). [PubMed: 23606815].
- Mathisen O, Soreide O, Bergan A. Laparoscopic cholecystectomy: bile duct and vascular injuries: management and outcome. *Scand J Gastroenterol.* 2002;**37**(4):476-81. doi: [10.1080/003655202317316123](https://doi.org/10.1080/003655202317316123). [PubMed: 11989840].
- Lopera JE. Embolization in trauma: principles and techniques. *Semin Intervent Radiol.* 2010;**27**(1):14-28. doi: [10.1055/s-0030-1247885](https://doi.org/10.1055/s-0030-1247885). [PubMed: 21359011].