



Unilateral Open Subtrochanteric Fracture in a Very Low Birth Weight Newborn: A Case Report

Amir Sobhani Eraghi,¹ and Nima Hosseinzadeh^{2,*}

¹M.D., Department of Orthopaedics Surgery, Rasoul Akram Hospital, Iran University of Medical Sciences, Tehran, IR Iran

²M.D., Bone and Joint Reconstruction Research Center, Shafa Orthopedic Hospital, Iran University of Medical Sciences, Tehran, IR Iran

*Corresponding author: Dr. Nima Hosseinzadeh, Department of Orthopaedics Surgery, Bone and Joint Reconstruction Research Center, Shafa Orthopedic Hospital, Hazrat-e Rasool General Hospital, Iran University of Medical Sciences, Tehran, IR Iran. Tel: +98-2164352264, E-mail: hosseinzade.nima@gmail.com

Received 2017 August 02; Accepted 2017 September 27.

Abstract

Background: This case report presents an open subtrochanteric fracture in a premature low birth weight newborn, which was treated with intramedullary Kirschner wire.

Methods: A neonate with left open subtrochanteric fracture was referred to the orthopedics department of the current study. Pavlik harness was applied yet treatment failed; therefore, an intramedullary Kirschner wire was applied.

Results: The pin was maintained for 6 weeks and fracture healing was confirmed by a radiograph. Follow up after 18 months showed complete healing, no limb length discrepancy, and normal gait.

Conclusions: In some patients, traditional methods, such as traction, cast, and Pavlik harness cannot be used. Intramedullary Kirschner wire insertion could be an alternative treatment option.

Keywords: Subtrochanteric Fracture, Newborn, Kirschner Wire

1. Background

Birth-related fractures are relatively uncommon. Fracture of the femur is the most common fracture in the lower extremity (1). Long bone fractures often occur in vaginal deliveries, breech presentation, low birth weight, and large fetus (2, 3), yet they can also occur during cesarean section (CS) (4, 5). Management of these fractures is challenging and optimal treatment is the matter of debate. This study reports on an open subtrochanteric fracture in a premature low birth weight newborn, who was treated with an uncommon method. The authors obtained the patient's parental informed written consent for print and electronic publication of the case report.

2. Case Report

A 2-day-old female neonate with left open subtrochanteric fracture was referred to the orthopedics department. She was delivered by caesarian section at 32 weeks of gestation, weighing only 780 g. Her mother was a 22-years-old primigravida with no specific medical history. Exact data of the delivery details and fetus presentation was not available. The neonate was kept in an incubator at the neonatal intensive care unit (NICU). There was a small

wound on the anterior surface of the thigh and a sharp beak of proximal segment was felt. X-rays revealed left subtrochanteric spiral fracture.

Traction could not be used for treatment because the patient was premature and was kept in an incubator, therefore the patient underwent pavlik harness application. The small size of the newborn's body made it difficult to provide a pavlik, so the pavlik was not fit.

The proximal segment often goes in the abduction, external rotation, and flexion deformity, therefore, the Pavlik was applied in approximately 90 degrees of flexion and 40 degrees of abduction and sterile dressing was applied on the wound. Because of no improvement in the reduction and wound condition, flexion of the pavlik was increased on the third and fifth day yet did not solve the problem. Because the traditional methods of treatment could not be used, it was decided to perform an uncommon treatment. Under anesthesia in the operating room and after close reduction, an intramedullary Kirschner wire (2-mm diameter) was applied from the proximal end of the femur just for keeping the alignment and preventing bone exposure from the wound. The proximal end of the Kirschner wire was not buried. Also, the limb with splint or brace was not immobilized. This method did not interfere with keeping the newborn in the incubator and allowed better wound

care.

After 10 days, the control radiograph showed the callus formation at the margins of the fracture. Weekly follow up revealed a good result and wound healing without any morbidity. At the end of the sixth week, the Kirschner wire was removed. Follow up after 24 months showed complete healing, no limb length discrepancy, and normal gait (Figures 1 - 5).

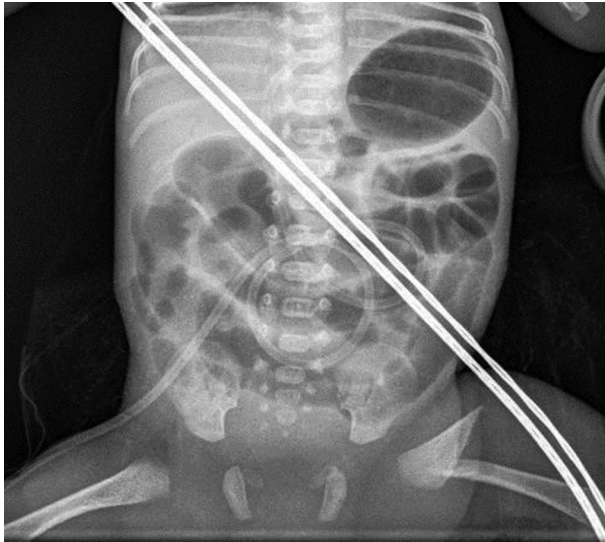


Figure 1. Radiograph Showing a Subtrochanteric Open Fracture in the Newborn

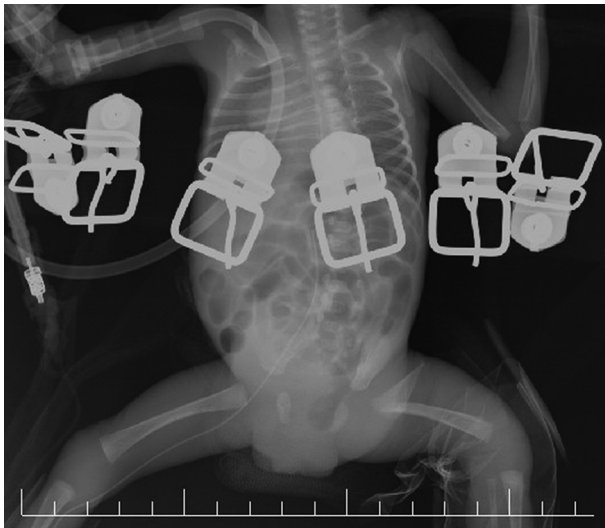


Figure 2. Three days after pavlik application. No improvement had occurred.

3. Discussion

Fetal injuries may occur during CS delivery in approximately 1.1% of cases (3). Fractures may also happen due to significant mechanical forces during the delivery. The most common is a clavicle fracture (5, 6). Fracture of the femur during CS in newborns is a rare condition with an incidence of 0.308 per 1000 CS (7). Researches have demonstrated that risk factors associated with femoral fractures during CS are large fetus, breech presentation, difficult delivery, inadequate uterine relaxation, inadequate incision in the lower uterine segment, low birth weight, twin pregnancies, leiomyoma of the uterus, osteogenesis imperfecta, prematurity, and osteoporosis (8-10). Because of low incidence, there is no consensus for management of these fractures. Treatment options are also limited including Pavlik harness, spica cast, and traction.

Kancherla et al. (2) reported a series of 8 femoral shaft fractures and 2 subtrochanteric fractures, which were treated with toe-groin cast and limb-body strapping, respectively. All healed completely after 4 weeks with no long-term sequel.

In another series, Givon et al. (11) retrospectively, reviewed 13 femur fractures. All of them were treated with Bryant skin traction of both legs for 2 to 3 weeks. All fractures healed satisfactorily with no residual deformity or functional impairment.

D Andrea (12) reported a case of femoral shaft fracture treated with an innovative method. They applied an Orthofix External Fixator for fracture stabilization for 30 days. The 2 years follow up was satisfactory.

In the present case, there were no exact data on the delivery details yet prematurity and low birth weight were predisposing factors for a femur fracture. According to prior studies and due to patient's condition, it was decided to manage the fracture with pavlik harness. When it failed, the treatment plan changed to insertion of intramedullary Kirschner wire. It allows aligning the fracture and decreases the rate of malunion, yet does not control the rotation. Complete healing was confirmed with radiologic findings 6 weeks after surgery and the Kirschner wire was removed.

3.1. Conclusions

Femoral fractures in newborns are rare injuries. Early diagnosis and treatment often results in a good outcome. In some patients, traditional methods such as traction, cast and pavlik harness cannot be used. Intramedullary Kirschner wire insertion could be an alternative treatment option. This method is simple, minimally invasive and inexpensive and postoperative care is easy.

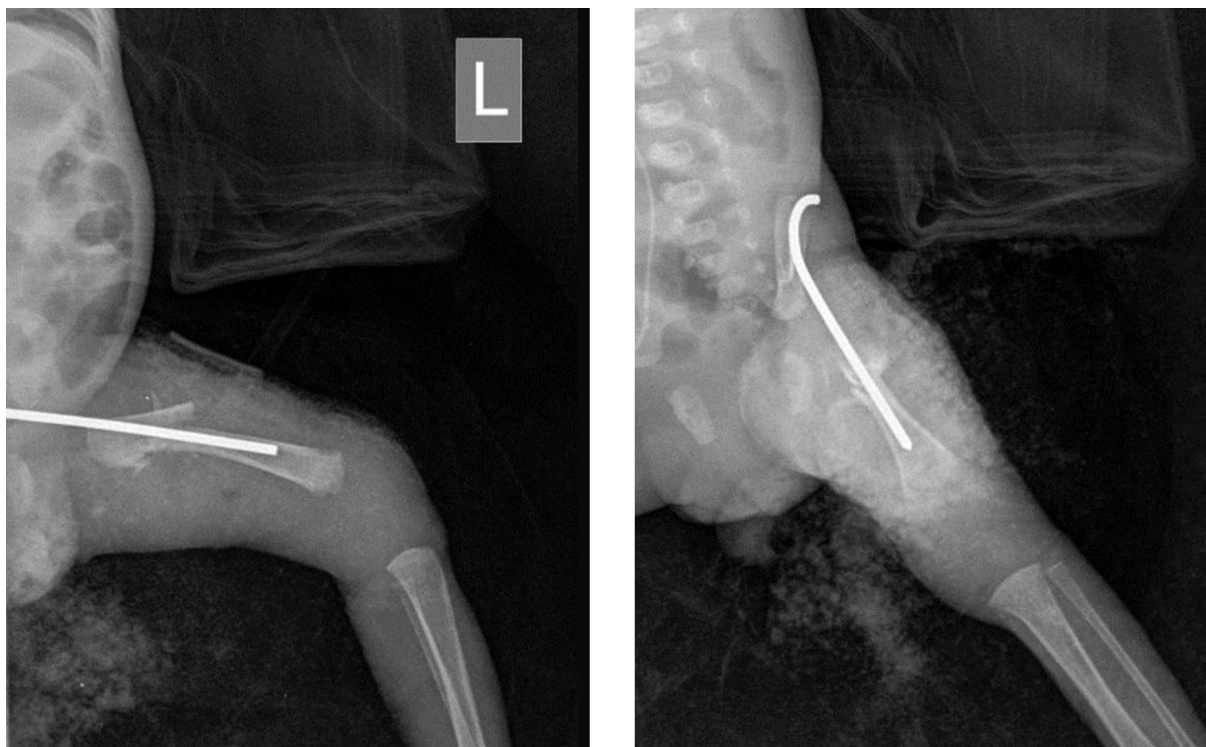


Figure 3. Radiograph After Insertion of INTRAMEDULLARY KIRSCHNER WIRE

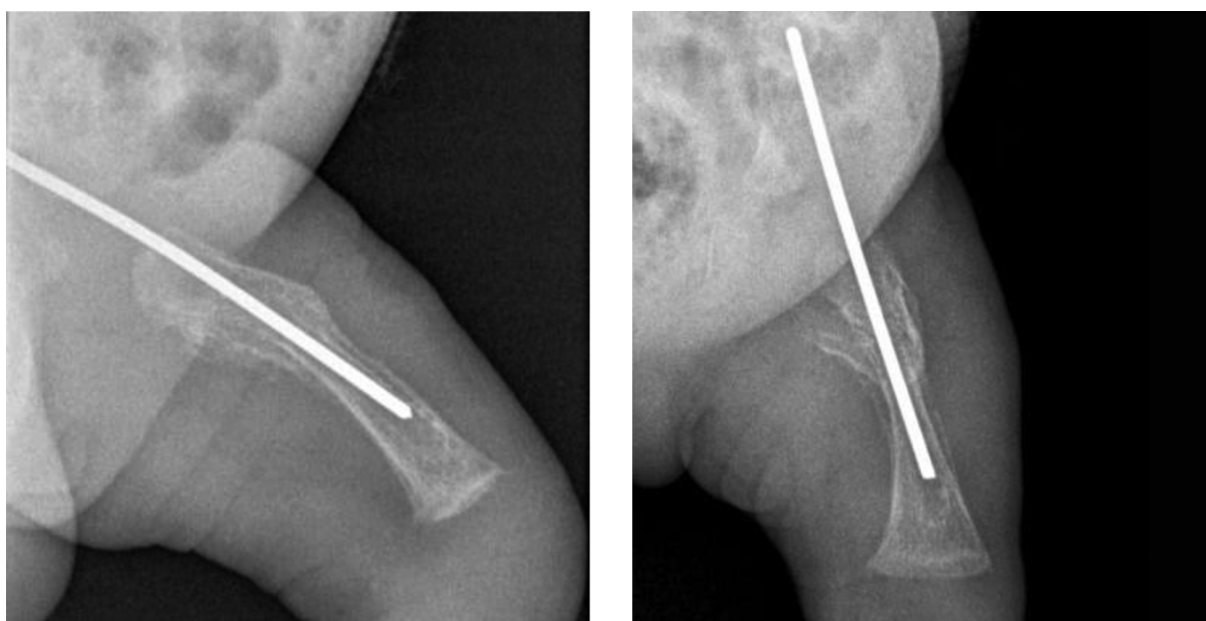


Figure 4. Radiograph Shows Healing After 6 Weeks

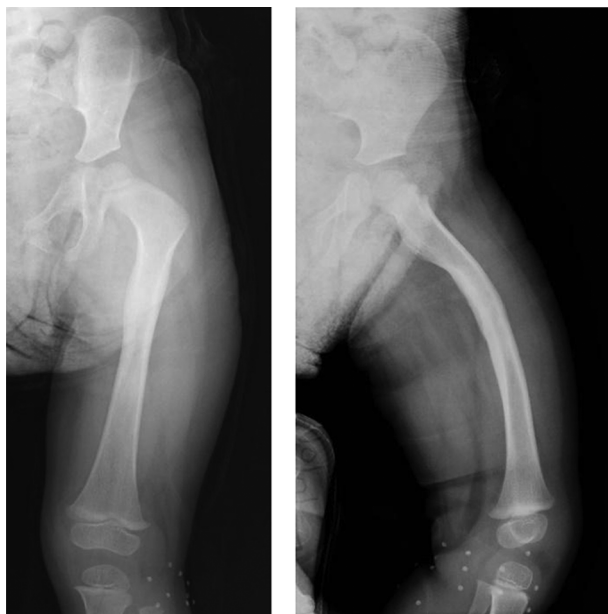

Figure 5. Radiograph Shows Remodeling of the Femur After 24 Months

Footnote

Conflict of Interest: “The authors declare that they had no conflict of interest.”

References

1. Vasa R, Kim MR. Fracture of the femur at cesarean section: case report

and review of literature. *Am J Perinatol.* 1990;7(1):46-8. doi: [10.1055/s-2007-999445](https://doi.org/10.1055/s-2007-999445). [PubMed: 2403793].

2. Kancherla R, Sankineani SR, Naranje S, Rijal L, Kumar R, Ansari T, et al. Birth related femoral fracture in newborns: risk factors and management. *J Child Orthop.* 2012;6(3):177-80. doi: [10.1007/s11832-012-0412-4](https://doi.org/10.1007/s11832-012-0412-4).

3. Kim YS, Han HS, Sang JH. Unilateral femoral fracture in a low birth weight infant: a case report. *J Nippon Med Sch.* 2015;82(2):106-8. doi: [10.1272/jnms.82.106](https://doi.org/10.1272/jnms.82.106). [PubMed: 25959202].

4. Farikou I, Bernadette NN, Daniel HE, Aurelien SM. Fracture of the Femur of A Newborn after Cesarean Section for Breech Presentation and Fibroid Uterus : A Case Report and Literature Review. *J Orthop Case Rep.* 2014;4(1):18-20. doi: [10.13107/jocr.2250-0685.141](https://doi.org/10.13107/jocr.2250-0685.141). [PubMed: 27298938].

5. Al Haddan I. Birth related fractures of long bones. *Indian J Pediatr.* 2003;70(12):959-60. [PubMed: 14719783].

6. Rijal L, Ansari T, Trikha V, Yadhav CS. Birth injuries in caesarian sections: cases of fracture femur and humerus following caesarian section. *Nepal Med Coll J.* 2009;11(3):207-8. [PubMed: 20334074].

7. Toker A, Perry ZH, Cohen E, Krymko H. Cesarean section and the risk of fractured femur. *Isr Med Assoc J.* 2009;11(7):416-8. [PubMed: 19911493].

8. Capobianco G, Viridis G, Lisai P, Cherchi C, Biasseti O, Dessole F, et al. Cesarean section and right femur fracture: a rare but possible complication for breech presentation. *Case Rep Obstet Gynecol.* 2013;2013:613709. doi: [10.1155/2013/613709](https://doi.org/10.1155/2013/613709). [PubMed: 23533865].

9. Cebesoy FB, Cebesoy O, Incebiyik A. Bilateral femur fracture in a newborn: an extreme complication of cesarean delivery. *Arch Gynecol Obstet.* 2009;279(1):73-4. doi: [10.1007/s00404-008-0639-y](https://doi.org/10.1007/s00404-008-0639-y). [PubMed: 18368414].

10. Morris S, Cassidy N, Stephens M, McCormack D, McManus F. Birth-associated femoral fractures: incidence and outcome. *J Pediatr Orthop.* 2002;22(1):27-30. [PubMed: 11744849].

11. Givon U, Sherr-Lurie N, Schindler A, Blankstein A, Ganel A. Treatment of femoral fractures in neonates. *Isr Med Assoc J.* 2007;9(1):28-9. [PubMed: 17274352].

12. D Andrea L, Catena N. Femoral shaft fracture in a newborn infant treated with axial external fixator: a case report. *J Pediatr Orthop.* 2008;28(1):17-9. doi: [10.1097/bpo.0b013e31815b4dea](https://doi.org/10.1097/bpo.0b013e31815b4dea). [PubMed: 18157041].