

Progressive Non-infectious Anterior Vertebral Fusion (Copenhagen Syndrome); A Case Report and Literature Review

*Farzad Omid-Kashani¹

¹Professor of Orthopedics and Spine Surgery, Orthopedic Department, Faculty of Medicine, Mashhad University of Medical Sciences, Mashhad, Iran.

Abstract

Progressive anterior vertebral fusion (PAVF or Copenhagen syndrome) is a very rare cause of pathologic kyphosis that gradually and progressively leads to anterior vertebral fusion. In this report, we described a 13-year-old girl with PAVF presented to the orthopedic clinic of Imam Reza Hospital with rigid thoracic kyphosis (90⁰) in 2019. She underwent two stages anterior and posterior spinal surgery and was finally discharged with a normally aligned spine and good general condition. In pediatric patients presented with thoracic or thoracolumbar kyphosis, in addition to the common diseases that cause kyphosis, PAVF should also be considered.

Key Words: Child, Spinal Fusion, Kyphosis, Vertebral body fusion overgrowth.

*Please, cite this article as Omid-Kashani F. Progressive Non-infectious Anterior Vertebral Fusion (Copenhagen Syndrome); A Case Report and Literature Review. Int J Pediatr 2020; 8(12): 12629-634 DOI: **10.22038/IJP.2020.51773.4119**

*Corresponding Author:

Farzad Omid-Kashani, MD, Orthopedic Department, Imam Reza Hospital, Imam Reza Square, Mashhad University of Medical Sciences, Mashhad, Iran. Postal Code: 9137913316. Fax: +98 51 3859 5023.

Email: omidif@mums.ac.ir

Received date: Jul.23, 2020; Accepted date: Oct.12, 2020

1- INTRODUCTION

Progressive non-infectious anterior vertebral fusion (PAVF or Copenhagen syndrome) is a very rare cause of pathologic thoracic or thoracolumbar kyphosis, in which the anterior parts of the intervertebral discs fuse together gradually and progressively (1, 2). These bridging bones tether the anterior vertebral growth and leads to regional progressive kyphosis (3). Fewer than 100 cases of the disease in patients with different ages have been reported throughout the world (4). Here we report a 13-year-old patient with a diagnosis of that disease.

2- CASE REPORT

A 13-year-old girl presented to the orthopedic clinic of Imam Reza Hospital, Mashhad, Iran, in 2019 with a chief complaint of deformity without any associated pain or respiratory distress. Deformity was noticed from three years ago, but was untreated. She was in a pre-menarche state. Laboratory tests were completely normal. Past medical history revealed nothing and physical examination showed a rigid thoracic kyphosis, with balanced spine, intact skin, and normal neurologic state (Figure.1).

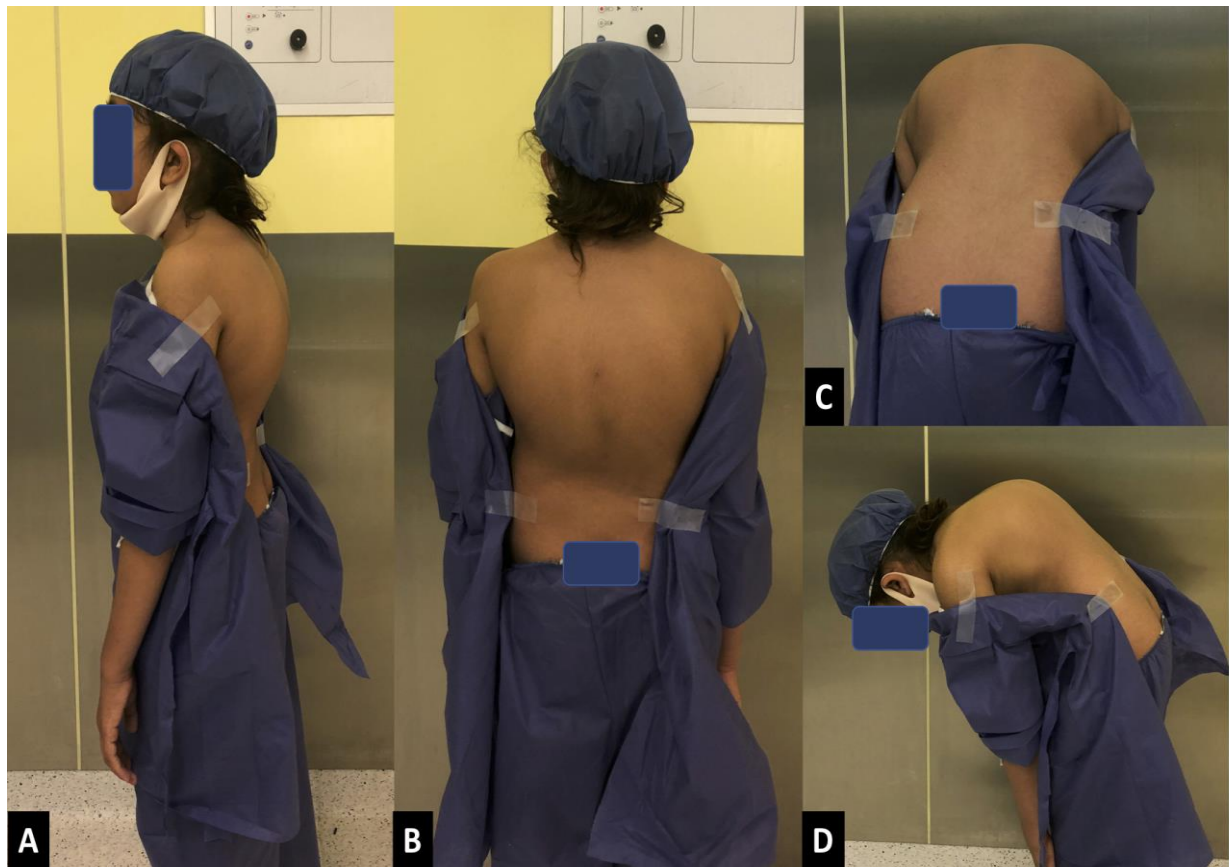

Fig.1. Photography of the affected patient shows angular thoracic kyphosis.

The stature was relatively short but there were no signs of any associated anomalies. Plain radiography in upright and supine hyperextension positions revealed a completely rigid thoracic kyphosis of 90° with anterior fusion of some of the involved disc spaces, while posterior disc spaces were

nearly intact (Figure.2). MRI revealed anterior disc space narrowing and endplate irregularities. In the vertebral levels of T12-L1 and T10-T11, complete obliteration of the disc space and fusion have already occurred (Figure.3).

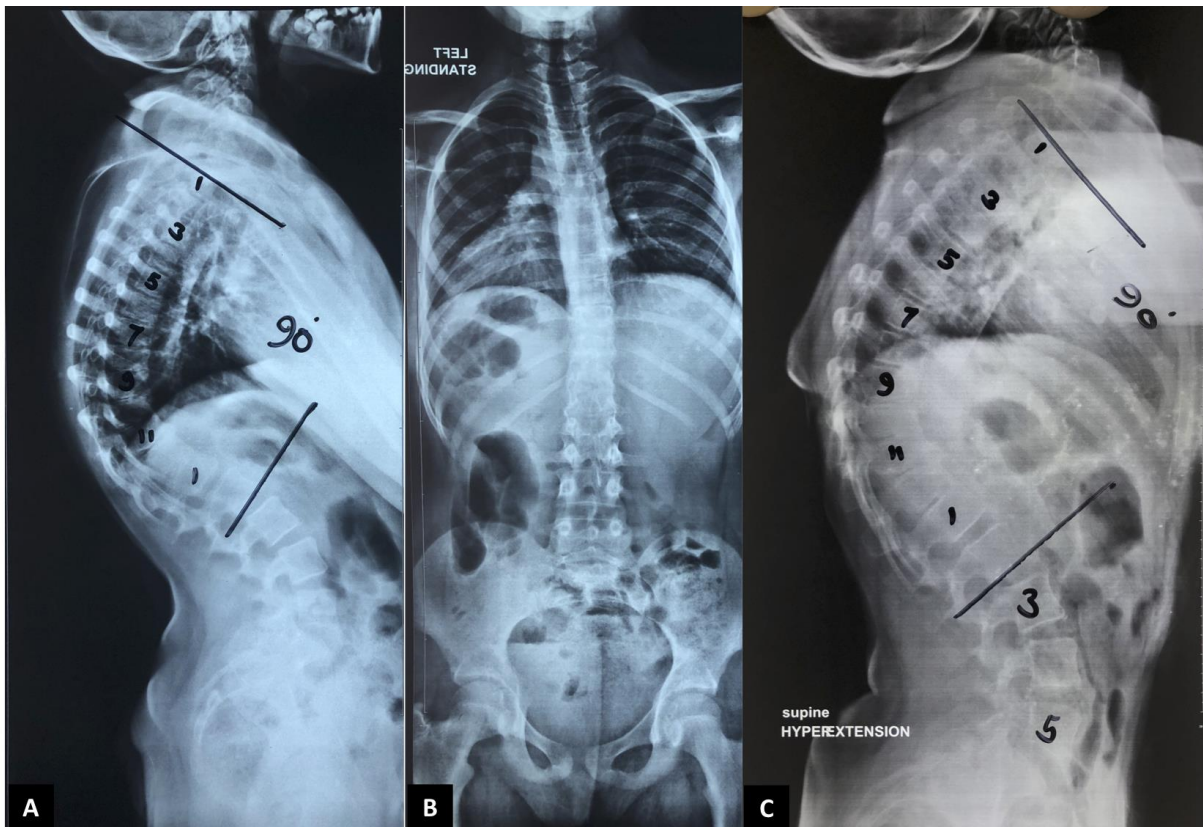


Fig. 2: Plain radiography of the spine. A and B: Lateral and posteroanterior upright view of the spine show T1-L1 kyphosis of 90° with apex at T9. C: Supine hyperextension lateral view of the spine shows complete stiffness of the kyphosis.

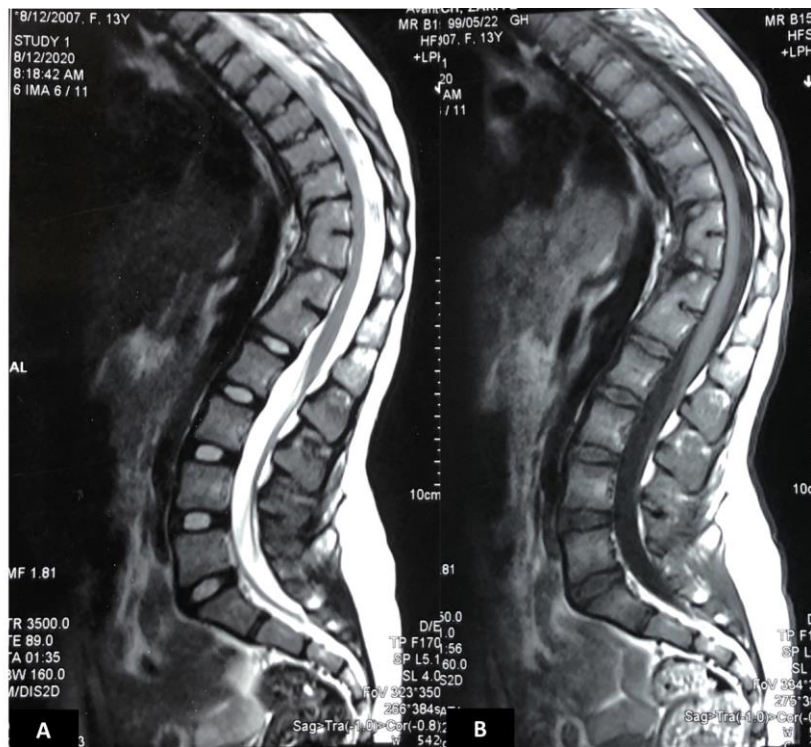


Fig. 3: Sagittal MRI T2 and T1 sequence images (A and B) show anterior disc narrowing, endplate irregularity, and anterior fusion of the involved discs.

The patient underwent a two stage operation. Both stages were carried out under strict control of intraoperative neuromonitoring. In the first stage, the patient was positioned in right lateral decubitus and left thoracotomy on the 8th rib was carried out. The rib was completely resected and anterior surface of the spine exposed. We first temporary

clamped the segmental vessels and waited about 20 minutes for any abnormal neuromonitoring signal change, and then ligated them. Intact areas of the intervertebral spaces were initially recognized and then, by gentle osteotomy and bone resection, anterior disc spaces were released and reconstructed (**Figure.4**).

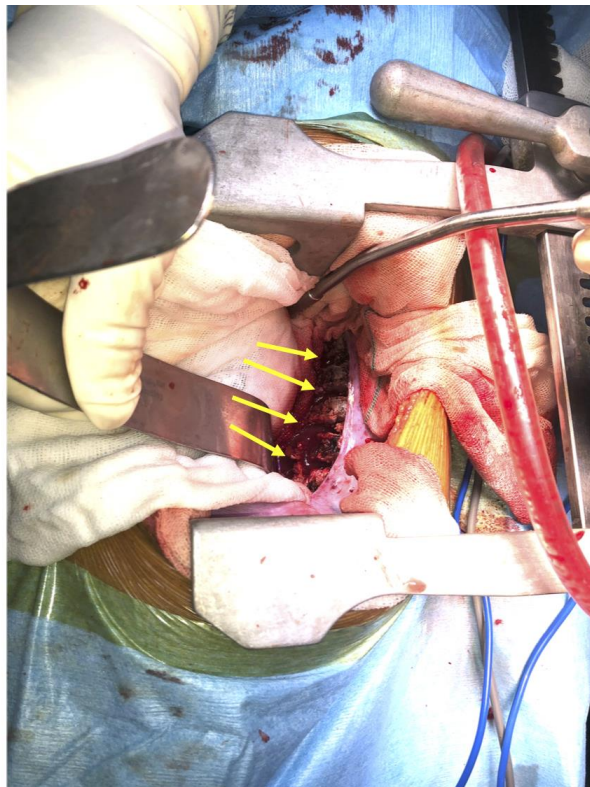


Fig. 4: Intraoperative photography during thoracotomy after releasing the intervertebral discs. Arrows show the intervertebral spaces before grafting with morsellized rib.

Next, morsellized bone graft harvested from the resected rib was placed in the intervertebral disc spaces. In the second stage performed one week later, we did posterior spinal fusion and instrumentation from T2 to L4 (**Figure.5**). We intended to restore thoracic kyphosis to only about 45° in order to avoid proximal junctional kyphosis due to the aggressive correction.

During both surgical stages, we did not receive any abnormal signal change from cord monitoring. Postoperatively, neurological status was completely intact. We mobilized the patient on the second day of the last operation and she was discharged from the hospital on the third day while wearing a soft corset.

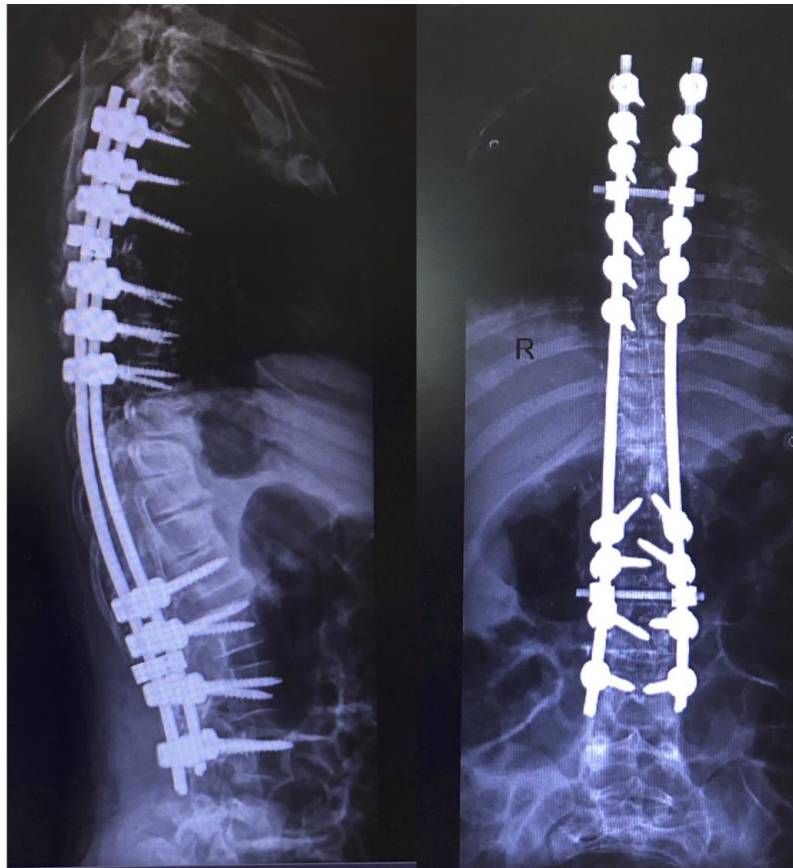

Fig. 5: Postoperative anteroposterior and lateral views of the spine.

3- DISCUSSION

PAVF was first reported by Knutsson in 1949 in a 14-year-old boy and since then, less than one hundred cases have been reported including 26 cases from the university Hospital of Copenhagen (2-7). For this reason, some authors named the disease as Copenhagen syndrome (8). In some cases, the disease occurs hereditary or may be associated with other anomalies including hearing defects, extremities anomalies (tibial agenesis, foot deformities), Klippel-Feil syndrome, Ito syndrome, pulmonary artery stenosis, and hemisacralization of L5 vertebra (9). Neurologic deficit is unusual, but in severe cases with acutely angled thoracic kyphosis, spinal cord compression and consequently, upper motor neuron disease may be occurred. Narrowing, erosion and irregularity of the anterior endplates progresses gradually and eventually, disc space obliteration and bony ankylosis

occurs, first anteriorly and then, complete vertebral fusion in three columns happens. The process may affect one level or several contiguous or non-contiguous levels. Magnetic resonance imaging (MRI) can clearly show the anterior disc narrowing, endplate irregularity, and edema, especially within the anterior discovertebral margin. Signal intensity changes proceed radiographic changes; therefore, MRI can detect early changes in PAVF and it also reflects the disease activity (8). Differential diagnosis of PAVF includes congenital kyphosis type II, anterior limbus vertebra, Scheuermann's disease, thalidomide embryopathy in children, and ankylosing spondylitis and diffuse idiopathic skeletal hyperostosis in adults. PAVF is similar to type II congenital kyphosis (failure of segmentation) but in PAVF, disc spaces and vertebral bodies are normal at birth and later become anteriorly fused, for this

reason, some authors named the disease as a delayed type II of congenital kyphosis. Limbus vertebra is a well-corticated unfused secondary ossification center, usually in anterosuperior corner of the vertebral body. The fragment has a sclerotic margin and a triangular shape, but does not exactly fit into the adjacent bone (versus acutely fractured fragment) (10). The other quoted similar diseases also have some distinct characteristics that differentiate them from PAVF. Based on maturity of anterior vertebral fusion mass, five stages have been described for the disease: Stage 1, anterior disc space narrowing; stage 2, anterior endplates sclerosis; stage 3, anterior endplates fragmentation; stage 4, anterior endplate fusion; and stage 5, development of kyphosis (1). The disease causes anterior vertebral body tethering; therefore, growth continues in the posterior disc space and column and then, progressive kyphosis happens. In stages 1 to 3, thoracolumbar flexion control braces may be effective, but in lumbar spine an associated posterior spinal fusion may be indicated. In stages 4 or 5, in cases the disease caused significant deformity, the patient needs a kind of osteotomy to re-establish normal spinal alignment.

4- CONCLUSION

In pediatric patients presented with thoracic or thoracolumbar kyphosis, in addition to the common diseases that cause kyphosis (such as Scheuermann's, postural, or congenital kyphosis), we should also consider the rarer causes of kyphosis (such as PAVF), and treat it according to the cause of the disease.

5- ACKNOWLEDGEMENTS

The author would like to thank Ghasem Soltani, MD for his kind cooperation in suggestions and editing this manuscript.

6- CONFLICT OF INTEREST: None.

7- REFERENCES

1. Van Buskirk CS, Zeller RD, Dubousset JF: Progressive anterior vertebral fusion: a frequently missed diagnosis. Presented at Scoliosis Research Society, New York, 1998.
2. Smith JRG, Martin IR, Shaw DG, Robinson RO. Progressive non-infectious anterior vertebral fusion. *Skelet Radiol* 1986; 15(8):599-604.
3. Cebulski A, Nectoux E, Bigot J, Cagneaux M, Mézel A, Fron D, et al. Progressive anterior vertebral fusion: a report of three cases. *Diagn Interv Imaging*. 2012;93(1):53-6.
4. Malagelada F, Sewell MD, Fahmy A, Gibson A. Long-term clinical and radiological outcomes of Copenhagen syndrome with 19 affected levels: a case report. *Spine J*. 2015; 15(4): e19-23.
5. Andersen J, Rostgaard-Christensen E. Progressive non-infectious anterior vertebral fusion. *J Bone Joint Surg [Br]* 1991; 73(5): 859-62.
6. Murray RO, Jacobsen HG, Stoker DJ. The radiology of skeletal disorders. 3rd edn. London: Longman Group; 1990: 236.
7. Hughes RJ, Saifuddin A. Progressive non-infectious anterior vertebral fusion (Copenhagen Syndrome) in three children: features on radiographs and MR imaging. *Skeletal Radiol* 2006; 35(6): 397-401.
8. Kharrat K, Dubousset J. Progressive anterior vertebral fusion in children (author's transl). *Rev Chir Orthop Reparatrice Appar Mot* 1980; 66(8): 485-92.
9. Sanal HT, Yilmaz S, Simsek I. Limbus vertebra. *Arthritis Rheum* 2012; 64(12): 4011.
10. Warner WC, Sawyer JR. Scoliosis and Kyphosis. In: Azar FM, Beaty JH, Canale ST. *Campbell's operative orthopaedics*. 13rd ed. Philadelphia, USA: Elsevier; 2017: 2057-58.