

Biliary of Fascioliasis in Kermanshah Province, Western Iran**Homayoon BASHIRI^{1,2}, Arezoo BOZORGOMID¹, *Yazdan HAMZAVI³**

1. Infectious Diseases Research Center, Health Institute, Kermanshah University of Medical Sciences, Kermanshah, Iran
2. Department of Internal Medicine, School of Medicine, Kermanshah University of Medical Sciences, Kermanshah, Iran
3. Department of Medical Parasitology and Mycology, School of Medicine, Kermanshah University of Medical Sciences, Kermanshah, Iran

Corresponding Author:** Email: yhamzavi@kums.ac.ir**(Received 12 Aug 2019; accepted 25 Aug 2019)*Dear Editor-in-Chief**

Fascioliasis is a zoonotic infection caused by liver fluke species of the genus *Fasciola*, which commonly affects livestock and humans, are accidental hosts (1). We reported three female patients with a mean age of 45 yr during the chronic stage of fascioliasis diagnosed and treated using endoscopic retrograde cholangiopancreatography (ERCP) between 2010 and 2015. Patients were referred to our hospital with complaints of icterus and pain in the right upper quadrant of the abdomen. In our three cases, parasitological examination of feces was negative and one of patients presented with the eosinophil count within normal

ranges. Their laboratory findings were interpreted as biliary obstruction and cholangitis. Ultrasound imaging showed dilated common bile duct, but did not help for arriving at the correct diagnosis. ERCP showed the presence of mobile liver flukes in the biliary ducts (Fig. 1A). After sphincterotomy, the leaf-like worms were extracted from the common bile duct using a balloon (Fig. 1B). The patients were given single dose of triclabendazole (500 mg) for two days and after treatment; clinical findings were completely disappeared, liver enzymes and the other laboratory values returned to normal.

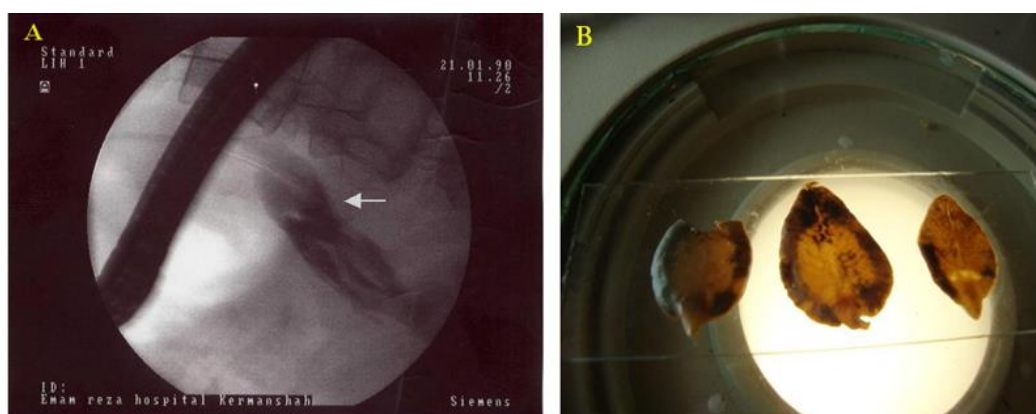


Fig. 1: ERCP image showed a radiolucent, crescent-like shadow in the CBC (white arrows) (A), adult *Fasciola hepatica* flukes measuring 1.5-2 cm×1 cm in diameter isolated from patients (B)



Patients lived in Kermanshah, western province of Iran where minor emergence of human fasciolosis was observed in 1998 (2). Subsequently, human fascioliasis was rarely found in this area. Epidemiology of fascioliasis in Kermanshah Province has demonstrated the presence of snail intermediate hosts of disease in the area (3). Morphologic features of the flatworm in our patients verified *F. hepatica*. Almost all cases of human fascioliasis in Iran have been reported as *F. hepatica* (4, 5). Nevertheless, the first molecular confirmation of the presence of *F. gigantica* was reported in a patient from the northwest of country (6).

This case series is a reminder that fascioliasis still exists and physicians working in our province should be kept in mind of chronic cholecystitis associated with fascioliasis. They should know the clinical symptoms so that a suitable diagnosis and therapy can be performed. If liver fluke is suspected and time permits, multiple stool examinations using the sedimentation technique are performed for the presence of parasites. It also important to educate allied health staff to identify parasites in stool samples, this is critical for efficient control of the disease in the country.

Acknowledgements

The authors would like to thank the Clinical Research Development Center of Imam Reza Hospital affiliated to Kermanshah University of Medical Sciences for their kind support. This report did not have financial support.

Conflict of interest

The authors declare that there is no conflict of interest.

References

1. Bozorgomid A, Rouhani S, Harandi MF, et al (2020). Genetic diversity and distribution of *Fasciola hepatica* haplotypes in Iran: molecular and phylogenetic studies. *Vet Parasitol Reg Stud Reports*, doi: 10.1016/j.vprsr.2019.100359.
2. Hatami H, Asmar M, Masoud J, et al (2012). The first epidemic and new-emerging human fascioliasis in Kermanshah (western Iran) and a ten-year follow up, 1998-2008. *Int J Prev Med*, 3(4):266-272.
3. Bozorgomid A, Nazari N, Eshrat Beigom K, et al (2018). Epidemiology of fascioliasis in Kermanshah Province, western Iran. *Iran J Public Health*, 47(7):967-972.
4. Badirzadeh A, Sabzevari S (2017). Hepatic fascioliasis in Mashhad, Northeast Iran: first report. *Rev Soc Bras Med Trop*, 50(4):571-4.
5. Hosamirudsari H, Roudsari YJ (2015). *Fasciola hepatica* an unusual cause of chronic cholecystitis. *Int J Infect*. 2015 ; 2(2):e23108. doi: 10.17795/iji-23108.
6. Rokni MB, Bozorgomid A, Heydarian P, et al (2018). Molecular evidence of human fasciolosis due to *Fasciola gigantica* in Iran: a case report. *Iran J Public Health*, 47(5):750-754.