



A Giant Mass in the Liver: Is It Always Bad to be Fat?

Niloofer Nazeri^{1,*} and Donya Farrokh^{1,**}

¹Radiology Department, Imam Reza Hospital, Mashhad, Iran

*Corresponding author: Radiology Department, Imam Reza Hospital, Mashhad, Iran. Email: royal_padma@yahoo.com

**Corresponding author: Radiology Department, Imam Reza Hospital, Mashhad, Iran. Email: farrokhd@mums.ac.ir

Received 2019 September 01; Revised 2019 December 30; Accepted 2020 January 25.

Abstract

Introduction: Hepatic lipomas are rare benign lesions of the liver with characteristic findings on imaging, which differentiate them from other more important tumors of the liver and prevent unessential invasive procedures.

Case Presentation: A 62-year-old man with intense acute dyspnea referred to our emergency department in Imam Reza Hospital, Mashhad city, Iran. We performed initial diagnostic tests, Chest X-Ray (CXR), and non-contrast lung CT scan for further evaluation. Laboratory tests were in the normal range, but two well-defined lobulated masses with typical features of lipomas were noted on abdominal sections of plain CT scan in the patient's liver. The aim of this report is to define the characteristic appearance of these benign neoplasms on imaging techniques and to help exclude some more prevalent hepatic tumors with similar appearances without invasive procedures.

Conclusions: Although there are numerous fat-containing lesions in the liver and some have heterogeneous and atypical features, it is often possible to make a definitive diagnosis of hepatic lipomas based on their typical imaging features, including pure fat density on CT scan, well-defined margins, chemical shift artifact on MRI, etc.

Keywords: Benign Hepatic Tumor, Hepatic Angiomyolipoma, Hepatic Lipoma, Hepatic Lipoma CT Scan, Hepatic Tumor, Hepatic Angiomyolipoma, Liver Lipoma MRI

1. Introduction

Liver lipomas are rare, benign, asymptomatic tumors with unclear etiology, which are usually diagnosed incidentally during radiologic examination (1). Risk factors or evidence of malignant degeneration of hepatic lipomas have not yet been reported. In most cases, there are characteristic findings on ultrasound, CT scan, and MRI, which are enough for accurate diagnosis of liver lipomas and ruling out the need for invasive diagnostic procedures, such as needle biopsy or open biopsy.

Liver lipomas have been sporadically reported in the literature during the last decades. Here, we report a case of giant liver lipoma that was incidentally discovered in a patient referred to our academic center with acute severe dyspnea.

2. Case Presentation

A 62-year-old man was presented to the Edalatian Emergency Department (Mashhad University of Medical Sciences, Mashhad, Iran) with intense acute dyspnea. He complained of progressive shortness of breath during the last

few weeks, which was deteriorated in the last two days and was also accompanied by chest pain. He had a history of CABG due to coronary heart disease and hypertension and hyperlipidemia, which were controlled by medical treatment. The findings in the initial examination and laboratory tests are summarized in Table 1.

Chest radiography revealed pneumothorax in the left hemithorax, bilateral pleural effusion and consolidation in the left upper lobe (Figure 1). After implementing emergency procedures and inserting a chest tube in the left

Table 1. The Initial Assessment of the Patient

| Evaluation | Results |
|--------------------------------------|----------|
| EKG | Normal |
| Complete blood count | Normal |
| O ₂ saturation (room air) | 88% |
| Pulse rate (pulse/min) | 108 |
| Respiratory rate (respiration/min) | 17 |
| Liver function tests | Normal |
| Hepatitis serologic tests | Negative |

hemithorax, the patient was stabilized and a non-contrast chest CT scan was performed for further evaluation. On the non-contrast chest CT scan, pleural effusion, left lung collapse, and consolidation were evident.

In the visible parts of the patient's abdomen, a large lobulated well-defined mass was seen in the liver. The maximum diameter of the mass was about 11 centimeters. There was no displacement or invasion into the adjacent organs and omental fat. The lesion had a homogenous appearance with some visible thin septa. A 10-mm² region of interest (ROI) was placed within the mass and the measured attenuation was between -90 to -100 Hounsfield unit (Figures 2 and 3). According to the fat attenuation of the mass in the non-contrast CT scan, this imaging modality confirmed the diagnosis of giant intrahepatic lipoma and no further evaluation was required.

3. Discussion

With the exception of hemangioma, which is the most common benign hepatic lesion, benign tumors of the liver are quite rare (1-3). Lipid-containing tumors are rarely observed within the liver. Lipomatous tissues may be seen in unusual hepatic tumors such as lipoma, myolipoma, and angiomyolipoma (2, 4). True lipoma is an extremely rare lesion, which is composed of mature adipose tissue and has not been well described due to its low prevalence. The first

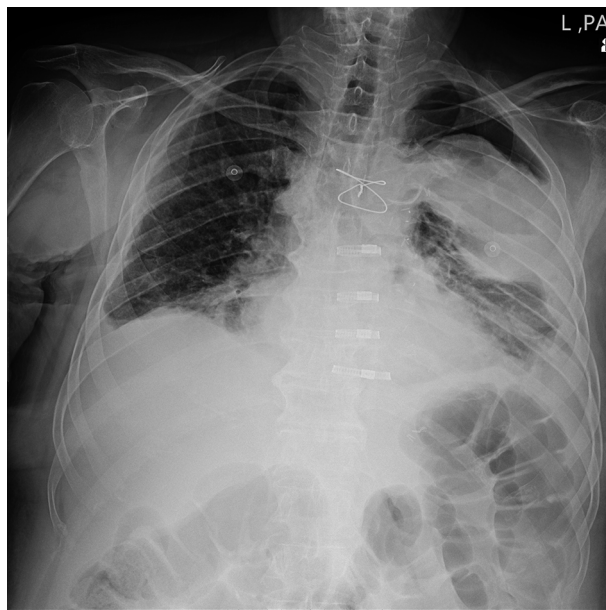


Figure 1. Chest X-Ray reveals left pneumothorax, bilateral pleural effusion and consolidation in the left upper lobe.

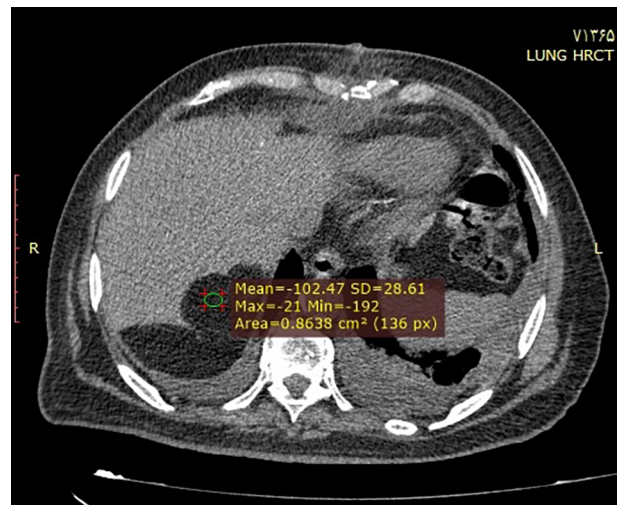


Figure 2. Non-contrast axial CT images show two hypodense, well distinct masses in segment 7 of the liver with an average density of -102.

description of liver lipoma was made by Ranchland et al. in 1970 as an incidental finding at autopsy in a young male (2). Since then, less than 50 cases of hepatic lipomas were reported in the literature. As much as we know, none of these cases were as large as the present case. Some of these cases in recent years are summarized in Table 2.

Lipomas are tumors consisting of mature adipose tissue that are rarely seen in the liver parenchyma (1). If small, these tumors are usually asymptomatic and need no treatment (1). Larger tumors may cause abdominal pain and mass effect on the adjacent structures. The etiology of liver lipoma is not clear and the development of these tumors has not been reported to be associated with any specific risk factors. However, it seems that there is an association between liver lipoma and non-alcoholic liver steatosis (2).

Radiologic diagnosis could be challenging and some features of fat-containing lesions may cause pitfalls in the accurate diagnosis. The ultrasound examination of lipomas usually shows a sharply bordered, uniformly hyperechoic mass with posterior attenuation that is usually located in the peripheral regions of the liver. When this view is observed on ultrasound images, differential diagnosis is primarily made based on a higher prevalence of other echogenic liver lesions such as liver hemangioma and metastatic lesions. Hemangioma and hepatic metastases are the leading causes of hyperechoic masses on ultrasound. In most patients, the ultrasound appearance of liver lipoma can be confused with hemangioma, especially when the tumor is small.

Metastatic lesions are the most common malignant tumors of the liver and generally show hypoechoic appear-

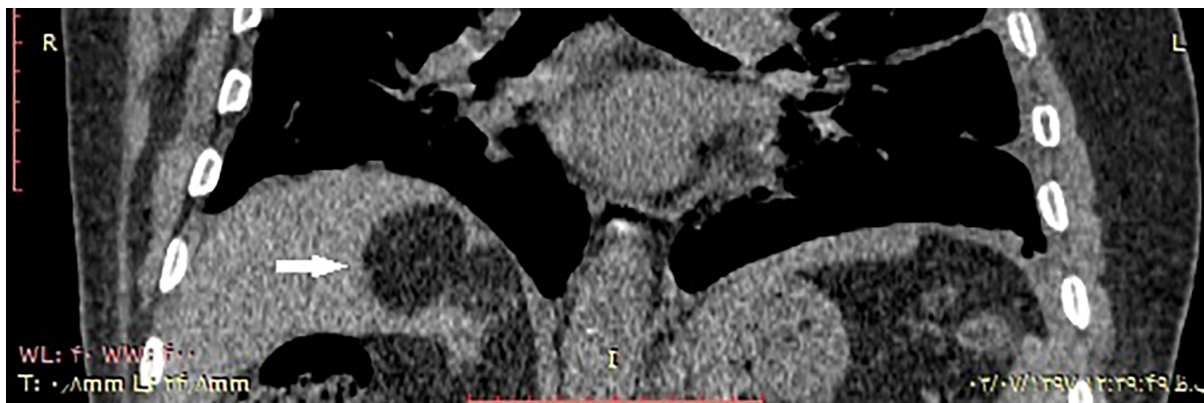


Figure 3. Coronal CT image of liver lipomas in the upper posterior segment

Table 2. Hepatic Lipoma Case Reports in Recent Years

| Authors | Year | Location of Lipoma | Size | Patient Symptoms and History | Imaging Features |
|-------------------|------|---|-------------------------|--|---|
| Shelar et al. (5) | 2019 | Right lobe of the liver | Less than 7 centimeters | A 43-year-old female patient with vague abdominal pain and no significant past medical history | Large and well-defined mass of mixed echogenicity (isohyperechoic) on the ultrasound and homogeneous with the density of fat (-20 to -115 HU) on the CT scan |
| Reddy et al. (6) | 2019 | Right lobe of the liver Segments V, VI, VII | Seven centimeters | A 76-year-old female patient with a 5-month history of the right upper abdominal quadrant pain and nausea. Physical examination revealed an enlarged liver by 3 cm below the costal margin | Abdominal ultrasound showed a solid, homogenous, hyperechoic, well-delineated tumor in the right liver lobe. Contrast-enhanced CT scan confirmed tumor presenting as large, hypodense smoothly margined rounded mass with Hounsfield units ranging from -30 to -100 and without enhancement |
| Makama et al. (7) | 2016 | Falciform ligament | Moderate size | A 38-year-old female patient with a 5-day history of an exacerbated epigastric pain which had been on and off for 3 years | Abdominal ultrasound demonstrated an area of well-defined, hypoechoic mass, which was situated dorsally to the rectus muscles |

ance on ultrasound, but some types of metastasis, especially those with gastrointestinal origin, may appear hyperechoic (2). Also, other less common fatty liver lesions such as angiomyolipoma, metastasis from liposarcoma, and fatty changes in hepatocellular carcinoma may have a hyperechoic appearance on ultrasound examination. Although ultrasound is the most used imaging modality in screening the patients for liver lesions, it may not characterize the true nature of liver lipoma and computed tomography (CT) and magnetic resonance imaging (MRI) increase the diagnostic accuracy of the liver lipoma and are usually recommended for definitive diagnosis. The presence of homogenous fat attenuation in non-contrast abdominal CT scan in a liver mass or loss of signal in the mass on the fat-saturated MRI sequences are hallmark features of these lesions (1). Lipomas are not at risk of malignant transformation and the presence of characteristic findings on the CT or MRI obviates the need for further evaluation (2, 6, 8).

In most cases, imaging modalities, especially CT and/or

MRI show characteristic findings, which are satisfactory for the diagnosis of liver lipoma. Therefore, most authors do not recommend more aggressive diagnostic procedures such as core needle biopsy or open biopsy (2, 6). Liver lipomas have a good prognosis and usually, the majority of them do not require any treatment. The physicians need to be aware of the characteristic appearance of lipoma in the CT scan and MRI to avoid unnecessary workup.

3.1. Conclusions

Hepatic lipomas are very rare lesions that are usually discovered incidentally on imaging and have been reported sporadically in the literature over the past decades. Although they are usually clinically asymptomatic and not require any treatment, liver lipomas can mimic many other more prevalent hepatic lesions. So being familiar with the imaging characteristics of this tumor is important to distinguish it from other fat-containing hepatic lesions to prevent unnecessary invasive procedures. This

case report emphasizes the importance of observing and measuring the pure density of fat from the tumor in non-contrast-enhanced computed tomography, which can confirm the diagnosis of liver lipoma and differentiate it from other fat-containing liver lesions.

Footnotes

Authors' Contribution: Donya Farrokh and Niloofar Nazeri developed the original idea and the protocol, abstracted and analyzed data, and wrote the manuscript.

Conflict of Interests: The authors declare no conflict of interest.

Funding/Support: No grant or support was received for this work.

Patient Consent: Written informed consent was obtained from the patient for the publication of the patient's information and images.

References

1. Manenti G, Picchi E, Castrignano A, Muto M, Nezzo M, Floris R. Liver lipoma: A case report. *BJR Case Rep.* 2017;**3**(2):20150467. doi: [10.1259/bjrcr.20150467](https://doi.org/10.1259/bjrcr.20150467). [PubMed: 30363260]. [PubMed Central: PMC6159265].
2. Valls C, Iannaccone R, Alba E, Murakami T, Hori M, Passariello R, et al. Fat in the liver: Diagnosis and characterization. *Eur Radiol.* 2006;**16**(10):2292-308. doi: [10.1007/s00330-006-0146-0](https://doi.org/10.1007/s00330-006-0146-0). [PubMed: 16477402].
3. Husainy MA, Sayyed F, Peddu P. Typical and atypical benign liver lesions: A review. *Clin Imaging.* 2017;**44**:79-91. doi: [10.1016/j.clinimag.2017.05.002](https://doi.org/10.1016/j.clinimag.2017.05.002). [PubMed: 28486156].
4. Harman M, Nart D, Acar T, Elmas N. Primary mesenchymal liver tumors: Radiological spectrum, differential diagnosis, and pathologic correlation. *Abdom Imaging.* 2015;**40**(5):1316-30. doi: [10.1007/s00261-014-0268-9](https://doi.org/10.1007/s00261-014-0268-9). [PubMed: 25311993].
5. Shelar RS, Patil P, Mathur N. An unusual case of liver lipoma. *Int J Sci Res.* 2019;**8**(10).
6. Reddy O, Gafoor JA, Suresh B, Prasad PO. Lipoma in liver: A rare presentation. *J Dr NTR Univ Health Sci.* 2015;**4**(3):185. doi: [10.4103/2277-8632.165398](https://doi.org/10.4103/2277-8632.165398).
7. Makama JG, Kache SA, Yusuf N, Sale D, Baduku ST. Lipoma of the falciform ligament of the liver as a rare cause of chronic epigastric pain: A case report and review of literature. *Arch Med Surg.* 2016;**1**(2):53.
8. Parente DB, Oliveira Neto JA, de Araujo ALE, Rodrigues RS, Perez RM, Marchiori E. Fat-containing liver lesions: A pictorial review. *Radiol Bras.* 2018;**51**(1):52-7. doi: [10.1590/0100-3984.2016.0147](https://doi.org/10.1590/0100-3984.2016.0147). [PubMed: 29559766]. [PubMed Central: PMC5846325].