



Sepsis Caused by *Elizabethkingia meningoseptica* Successfully Treated by Polymyxin B: A Case Report

Meiling Yu¹, Benquan Qi², Qi Zou³, Shengyong Zheng³, Chen Liu³ and Jingbo Ma^{4,*}

¹Department of Pharmacy, the First Affiliated Hospital of Bengbu Medical College, Anhui, Bengbu, PR China

²Department of Emergency Internal Medicine, the First Affiliated Hospital of Bengbu Medical College, Anhui, Bengbu, PR China

³Department of Critical Care Medicine, the First Affiliated Hospital of Bengbu Medical College, Anhui, Bengbu, PR China

⁴Department of Medical Section, the First Affiliated Hospital of Bengbu Medical College, Anhui, Bengbu, PR China

*Corresponding author: Department of Medical Section, the First Affiliated Hospital of Bengbu Medical College, Anhui, Bengbu, PR China. +86-5523086240, Email: majingbobyfy@sina.com

Received 2019 October 08; Revised 2020 January 21; Accepted 2020 February 08.

Abstract

Introduction: *Elizabethkingia meningoseptica* (EM) is a non-fermenting Gram-negative bacterium that is a conditional pathogen and easily causes infection in neonates and immunocompromised patients. The infection of the bacterium is prone to develop multi-drug resistance, difficult to treat, and associated with a high mortality rate.

Case Presentation: A 28-year-old female was admitted to the intensive care unit (ICU) of our hospital due to fulminant myocarditis, cardiogenic shock, acute heart failure, and multiple organ dysfunction syndrome (MODS) on 24 April 2019. The patient developed a lung infection and sepsis after admission. Two sputum culture tests on 27 April and 4 May showed infection with *Pseudomonas aeruginosa* and multi-drug resistance. The minimum inhibitory concentration (MIC) for imipenem was 4 mg/L and 8 mg/L, respectively. Four blood cultures on 9 May suggested an EM infection and multi-drug resistance, the MIC for imipenem was ≥ 16 mg/L. Due to the serious condition of the patient, imipenem-resistant lung infection, and typical sepsis manifestations, we initiated a regimen of polymyxin B combined with meropenem between 3 and 12 May. The infection was well-controlled and the patient was discharged on 14 May.

Conclusions: A polymyxin B-based combinational regimen is effective in the treatment of sepsis due to EM and play an important role in controlling EM-associated mixed infections.

Keywords: Chryseobacterium, Polymyxin B, Meropenem, Sepsis

1. Introduction

Chryseobacterium meningosepticum, also known as EM, is a non-fermenting Gram-negative bacterium that is widely found in water, soil, and even food. This bacterium can also be found in water pools in hospitals, nasal feeding tubes, and various liquid-filled bottles (1, 2). EM is a conditional pathogen and can cause infections in premature infants, neonates, and immunocompromised patients, including meningitis, sepsis, endocarditis, pulmonary infections, skin and soft tissue infections, and urinary tract infections (1-4). Infections caused by EM are difficult to treat. The mortality of neonatal meningitis caused by EM is as high as 57% (1), while EM-caused hospital-acquired infections has a 41% mortality rate and the mortality rate of community EM infections is also as high as 9.1% (5). The high mortality rate of EM-caused infections is associated with multi-drug resistance of the bacterium. This bacterium can produce metal β -lactamase and extended-spectrum β -

lactamase (6-8), and is resistant to β -lactam antibiotics, imipenem, colistin, and aminoglycosides. EM is only sensitive to quinolones, piperacillin tazobactam, cefoperazone sulbactam, vancomycin, and tigecycline, therefore options of treatment are limited (1, 2, 9, 10).

The ICU is one of the main departments for patients with EM infections, accounting for approximately 60% of total EM infections (11), while a proportion of ICU patients have infections in multiple sites. When an EM infection is complicated with other infections, treatment is more difficult and there are fewer drugs to choose. The patient we report herein had EM sepsis complicated with a pulmonary infection (*P. aeruginosa* multi-drug resistant infection, resistant to imipenem). Considering the serious condition of the patient, multi-drug and imipenem resistance revealed by the sputum culture test, we chose a regimen of polymyxin B in combination with meropenem to treat the patient from 3 to 12 May 2019. The patient's temperature,

white blood cell count, procalcitonin (PCT), and C-reactive protein (CRP) level decreased significantly. The patient was discharged to home on 14 May. Even though Dias et al. (12) reported that EM was resistant to polymyxin B, this case demonstrates that polymyxin B is effective in treating EM-induced sepsis, and the treatment regimen used in this patient can provide a reference for similar cases.

2. Case Presentation

A 28-year-old female was admitted to the ICU of our hospital (the First Affiliated Hospital of Bengbu Medical College, Bengbu, China) on 24 April 2019 because of "palpitations and fatigue for 7 days, and aggravation for 1 day". The patient's condition worsened 15 hours before admission, when she experienced peri-oral cyanosis, facial pallor, instability when standing, and blurred vision. Routine blood testing at the time of admission showed white blood cell count $14.27 \times 10^9/L$, neutrophil count $10.05 \times 10^9/L$. Blood biochemistry revealed that creatinine was $194 \mu\text{mol/L}$, urea 22.28 mmol/L , uric acid $719 \mu\text{mol/L}$, alanine aminotransferase 199 U/L ; aspartate aminotransferase 258 U/L , albumin 39.5 g/L , creatine kinase isoenzyme MB (CKMB) $88 \mu\text{mol/L}$, troponin $12.56 \mu\text{g/mL}$, and brain natriuretic peptide (BNP) $782 \mu\text{g/mL}$. The coagulation profile was normal. The patient was previously healthy and had no history of food or drug allergies. The physical examination at the time of admission revealed that her body temperature was 36°C , pulse $129/\text{min}$, respirations $37/\text{min}$, blood pressure $85/65 \text{ mmHg}$, and SPO_2 80% . The patient was conscious and had a poor spirit. Other symptoms included orthopnea, shortness of breath, sweating, and anemia. The patient was normally developed and responded to questions properly. Auscultation revealed coarse breath sounds and moist rales were extensively distributed in the bilateral upper and lower lungs. Limb ends were cold and the nail beds were cyanotic. The patient was clinically diagnosed with fulminant myocarditis, acute heart failure, cardiogenic shock, ventricular tachycardia, and multiple organ dysfunction (acute respiratory failure, acute liver injury, and acute kidney injury). After the patient was admitted, efforts were directed to improving the circulation, stabilizing the cardiomyocytes, use of cardiotoxic agents, anti-arrhythmics, and anti-virals, hepatoprotection, and continuous renal replacement therapy (CRRT). On the second day of admission (25 April), the patient had a high fever (the highest recorded temperature was 40.6°C). Routine blood testing showed white blood cell count $24.82 \times 10^9/L$, neutrophil count $22.41 \times 10^9/L$, and $\text{BNP} > 35,000 \text{ pg/mL}$. Considering the patient's serious condition and lung infection, we adjusted the anti-infective regimen. The moxifloxacin sodium chloride injection was terminated and

replaced with imipenem cilastatin sodium (1 g q6h) combined with vancomycin (1 g q6h). The patient's temperature was slightly decreased after the treatment. On 28 April (the 5th day in the ICU), the highest temperature was 38.1°C and laboratory tests showed CRP 130.9 mg/L , PCT 70.68 ng/mL , white blood cell count $35.04 \times 10^9/L$ and neutrophil count $27.49 \times 10^9/L$. On 2 May (day 9 in the ICU), the patient developed recurrent hyperthermia. The highest body temperature was 39.7°C . The PCT level decreased to 32.36 ng/mL , but was still high. On 3 May, white blood cell count was $12.34 \times 10^9/L$, neutrophil count $11.82 \times 10^9/L$, and CRP 88.5 mg/L . The infection was not well-controlled and a bloodstream infection could not be ruled out considering the symptoms and signs. The patient had been in the ICU for 10 days and had undergone multiple invasive procedures. Three indwelling catheters were placed in the right subclavian vein catheter (for infusions), right femoral vein catheter (for CRRT), and left subclavian vein catheter (for a temporary cardiac pacemaker). The patient was at high-risk for a bloodstream infection. In addition, there existed multi-drug resistant colonizing bacteria in the ICU ward. The anti-infection regimen was thereby adjusted to polymyxin B (50 mg q12h) plus meropenem (1g q8h via an infusion pump for 3 h) between 3 and 12 May. Following treatment, the temperature, PCT, CRP, white blood cell count and neutrophil count all decreased significantly (Figure 1).

During the hospitalization, two sputum cultures (on 27 April and 4 May) and four blood cultures (on 9 May) were detected. The sputum and blood cultures were collected by strictly following relevant guidelines. Blood cultures were collected as two sets from two separate sites, each set consists of one aerobic bottle and one anaerobic bottle. The automated BACT/ALERT® 3D 480 system (BioMérieux, France) was used to detect the presence or absence of microorganisms in the blood samples. Positive blood cultures and the sputum cultures were transferred to the blood and chocolate agar plates for further inoculation at 35°C for 18 - 24 h. The automated VITEK® 2 compact system (BioMérieux, France) was then used for bacterial identification and susceptibility testing. For this patient, the sputum cultures showed multi-drug resistant *P. aeruginosa*, and the MIC for imipenem was 4 mg/L and 8 mg/L, respectively. Four blood cultures on 9 May were positive for multi-drug resistant EM infections, the MIC for imipenem was $\geq 16 \text{ mg/L}$ (Table 1). Only piperacillin tazobactam, levofloxacin, ciprofloxacin, and compound sulfamethoxazole were sensitive (Figure 2 and Table 1), confirming that the patient had a lung infection complicated by sepsis. On 14 May, the vital signs were stable and the patient was discharged. On 16 May, two blood cultures were negative. Follow-up evaluations on 19 June and 1 July were normal and the patient had no discom-

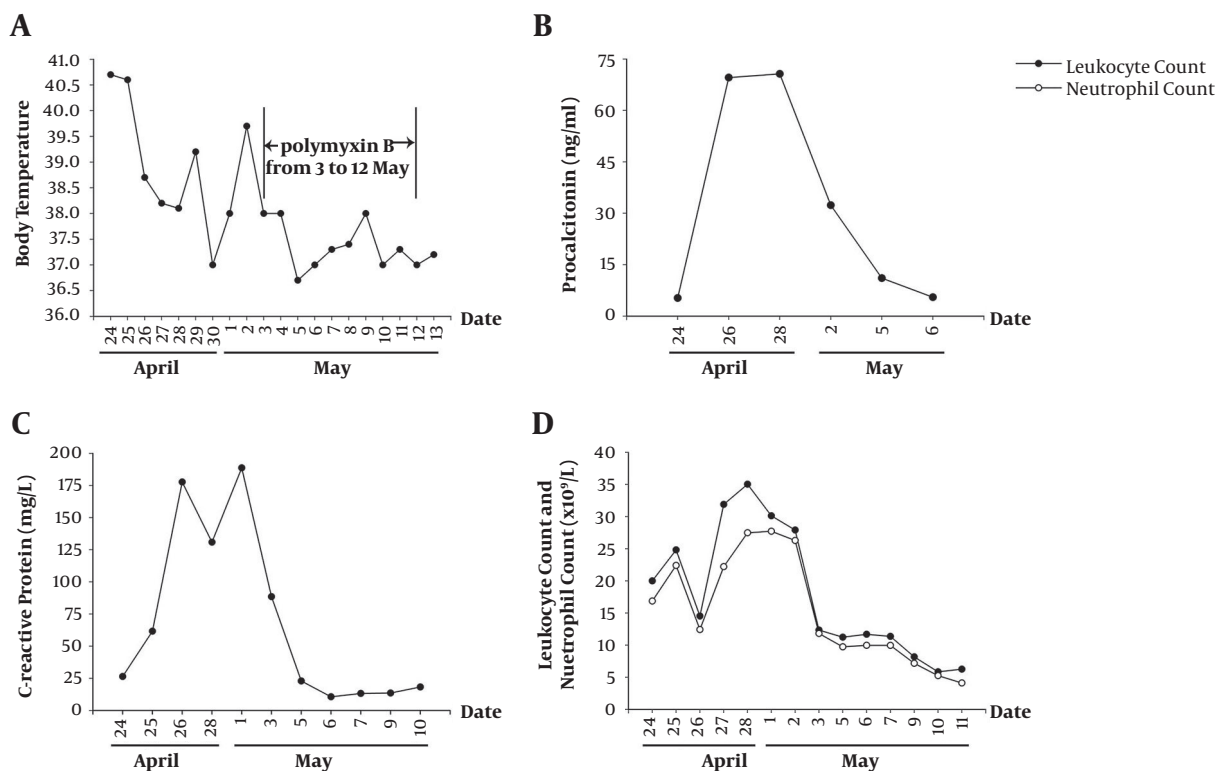


Figure 1. Changes in body temperature, white blood cell count, neutrophil count, PCT, and CRP during hospitalization. A, Changes in temperature from 24 April to 13 May; B, changes in PCT from 24 April to 6 May; C, changes in CRP from 24 April to 10 May; D, changes in white blood cell and neutrophil counts from 24 April to 11 May. The X axis represents the date.

fort.

In conclusion, even though Dias et al. (12) reported that clinical isolates of EM were resistant to polymyxin B, our study indeed first confirmed that a polymyxin B-based combination regimen effectively controls EM-induced severe infection (Table 2). Previous reports showed that quinolones, vancomycin and piperacillin/Tazobactam are effective for EM infections (Table 2), but most of them are mild and moderate infections, so this report provides new insight for the pharmacotherapy of severe infection caused by EM.

3. Discussion

Elizabethkingia meningoseptica infections are difficult to treat, especially in the ICU. It has been reported that quinolones and vancomycin may be good choices for the treatment of EM infections (12-17). Our study first confirmed that a polymyxin B-based combination regimen effectively controls sepsis caused by EM complicated by multi-drug resistant *P. aeruginosa*-associated lung infections, providing new insight for the pharmacotherapy of

EM infections, especially mixed infections.

Although quinolones and vancomycin are effective for EM infections (12-17), and EM is also sensitive to cefoperazone sulbactam, piperacillin sulbactam, and tigecycline, however, patients in the ICU often have multiple infections. For example, the patient reported here had EM sepsis complicated by a lung infection caused by multi-drug resistant *P. aeruginosa*. In 2018, the China CHINET Monitoring Data Network showed that resistance rates of *Acinetobacter baumannii* to ciprofloxacin, imipenem, piperacillin tazobactam, cefoperazone sulbactam, amikacin, tigecycline, and polymyxin B were 80.1%, 73.2%, 74.4%, 49.7%, 54.4%, 5%, and 0.7%, respectively, and the resistance rates of *Klebsiella pneumoniae* to the same seven antibiotics were 37.6%, 25%, 28.7%, 32.1%, 17.1%, 3.4%, and 0.9%, respectively. The resistance rates of *P. aeruginosa* to ciprofloxacin, imipenem, piperacillin tazobactam, cefoperazone sulbactam, amikacin, and polymyxin B were 18.9%, 30.7%, 16.7%, 17.1%, 6.2%, and 1.2%, respectively. *A. baumannii*, *P. aeruginosa*, and *K. pneumoniae* are three most common pathogens in the ICU and are multi-drug resistant in many cases (19, 20). The above data indicate that when EM infections are com-

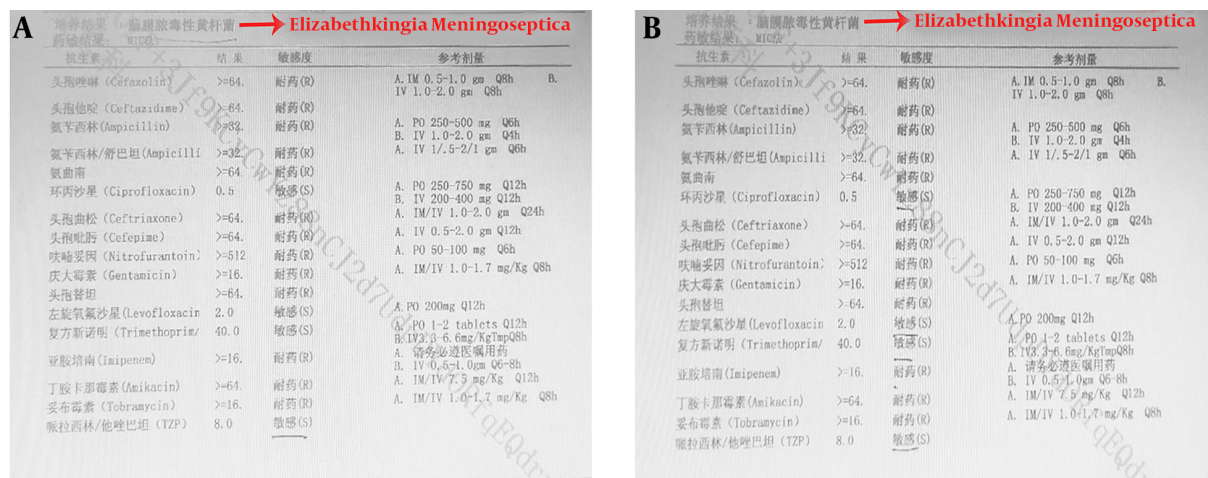

Figure 2. Results of blood cultures on 9 May (the results of four blood cultures on 9 May were consistent, and two times of results were showed here). The results suggested an infection with multi-drug resistant EM. The imipenem MIC was ≥ 16 mg/L, with sensitivity to piperacillin tazobactam, levofloxacin, ciprofloxacin, and trimethoprim-sulfamethoxazole.

Table 1. Results of Blood Cultures on 9 May 2019, Elizabethkingia meningoseptica

Antibiotics	MIC value, mg/L	Sensitivity
Cefozolin	≥ 64	resistant
Ceftazidime	≥ 64	resistant
Ampicillin	≥ 32	resistant
Ampicillin sulbactam	≥ 32	resistant
Aztreonam	≥ 64	resistant
Ciprofloxacin	0.5	sensitive
Ceftriaxone	≥ 64	resistant
Cefepime	≥ 64	resistant
Nitrofurantoin	≥ 512	resistant
Gentamicin	≥ 16	resistant
Cefotetan	≥ 64	resistant
Levofloxacin	2.0	sensitive
Compound trimethoprim	40.0	sensitive
Imipenem	≥ 16	resistant
Amikacin	≥ 64	resistant
Tobramycin	≥ 16	resistant
Piperacillin tazobactam	8.0	sensitive

combined with infections of other bacteria, although EM is sensitive to quinolones, piperacillin tazobactam, and cefoperazone sulbactam, other common pathogens are often resistant to these antibiotics, especially *A. baumannii*, which shows sensitivity only to tigecycline and polymyxin B. According to the report by Yang et al. (18), a 66-year-old male

patient was blood culture-positive for EM. After treatment with vancomycin, the temperature was normal and blood culture-negative, but after 11 days the patient developed a secondary infection with *A. baumannii* and died (18). The case confirms the effectiveness of vancomycin in treating EM infections, however, when complicated by a mixed infection with *A. baumannii*, vancomycin may not be the best choice.

The use of polymyxin B has gradually increased since its launch in China, which is related to the prevalence of carbapenem-resistant enterobacteriaceae infections. In the present case, in addition to polymyxin B, because our hospital does not have piperacillin tazobactam, meropenem was also included in the regimen. Hsu et al. (11) suggested that the choice of proper antibiotics is the key to decrease the mortality rate associated with EM infections. The authors also showed the 14-day mortality rate of patients using carbapenems was higher than other antibiotics (11). The rationale behind the use of meropenem in this patient, and whether or not meropenem can achieve satisfactory pharmacokinetic needs further study. The resistance rate of *P. aeruginosa* to levofloxacin is 28.5% in our hospital. Moreover, the lung infection in this patient was caused by multi-drug resistant *P. aeruginosa*. In such a situation, a combined regimen is required. Levofloxacin injection could be added to the polymyxin B based regimen (multiple blood culture results in this patient all indicated an infection with multi-drug resistant EM that was only sensitive to piperacillin tazobactam, levofloxacin, ciprofloxacin, and compound sulfamethoxazole). The efficacy of the combined regimen, consisting of piperacillin

Table 2. Our Study and Previous Reported Studies

Clinical Diagnosis	Main Drugs	Clinical Outcome	Reference or Our Study
Case 1: Bacteremia caused by EM	Case 1: vancomycin and ceftazidime	Case 1: cured	
Case 2: EM bacteremia with meningitis	Case 2: piperacillin/tazobactam and ciprofloxacin	Case 2: cured	(12)
Case 3: Urine infection caused by EM	Case 3: ciprofloxacin	Case 3: cured	
Vertebral osteomyelitis	Ciprofloxacin	Cured	(13)
Bacteremia caused by EM	Vancomycin	Cured	(14)
Meningitis caused by EM	Vancomycin	Cured	(15)
Bullous pneumonia caused by EM	Vancomycin, trimethoprim/sulfamethoxazole and ciprofloxacin	Cured	(16)
EM sepsis with meningitis	Ciprofloxacin plus vancomycin or piperacillin-tazobactam	Cured	(17)
EM and <i>Acinetobacter baumannii</i> septemia	Vancomycin	Died	(18)
EM sepsis and pulmonary infection (caused by <i>Pseudomonas aeruginosa</i> , multi-drug resistant bacteria)	Polymyxin B plus meropenem	Cured	Our study

Abbreviation: EM, *Elizabethkingia meningoseptica*.

tazobactam, cefoperazone sulbactam, quinolones, and even carbapenems, warrants further study.

In conclusion, our study first confirmed the feasibility of a polymyxin B-based regimen in EM sepsis with a lung infection due to *P. aeruginosa*. The study provides evidence for pharmacotherapy against EM-associated mixed infections in the ICU. The role of a tigecycline and/or polymyxin B combined regimen in the treatment of EM mixed infections will be further investigated.

Acknowledgments

The authors are grateful to technician Pu Guo, Doctor Weidong Qian and technician Xiaomeng Chen for their technical assistances.

Footnotes

Authors' Contribution: Meiling Yu and Benquan Qi drafted the manuscript. Qi Zou and Chen Liu collected the data. Jingbo Ma finalized the manuscript. All authors approved the final version of manuscript.

Conflict of Interests: All authors declare that there are no conflicts of interests.

Ethical Approval: The report was approved by the Ethical and Clinical Research Committee of the First Affiliated Hospital of Bengbu Medical College.

Funding/Support: This work is supported by the natural science foundation of the Provincial Education Department of Anhui (no.: KJ2018A0244).

Informed Consent: Written informed consent was obtained from the patient for publication of this case report and any accompanying images.

References

- Bloch KC, Nadarajah R, Jacobs R. *Chryseobacterium meningosepticum*: An emerging pathogen among immunocompromised adults. Report of 6 cases and literature review. *Medicine (Baltimore)*. 1997;76(1):30–41. doi: [10.1097/00005792-199701000-00003](https://doi.org/10.1097/00005792-199701000-00003). [PubMed: [9064486](https://pubmed.ncbi.nlm.nih.gov/9064486/)].
- Ceyhan M, Celik M. *Elizabethkingia meningosepticum* (*Chryseobacterium meningosepticum*) Infections in Children. *Int J Pediatr*. 2011;2011:215237. doi: [10.1155/2011/215237](https://doi.org/10.1155/2011/215237). [PubMed: [22046191](https://pubmed.ncbi.nlm.nih.gov/22046191/)]. [PubMed Central: [PMC3199185](https://pubmed.ncbi.nlm.nih.gov/PMC3199185/)].
- Lin PY, Chu C, Su LH, Huang CT, Chang WY, Chiu CH. Clinical and microbiological analysis of bloodstream infections caused by *Chryseobacterium meningosepticum* in nonneonatal patients. *J Clin Microbiol*. 2004;42(7):3353–5. doi: [10.1128/JCM.42.7.3353-3355.2004](https://doi.org/10.1128/JCM.42.7.3353-3355.2004). [PubMed: [15243115](https://pubmed.ncbi.nlm.nih.gov/15243115/)]. [PubMed Central: [PMC4446307](https://pubmed.ncbi.nlm.nih.gov/PMC4446307/)].
- Chiu CH, Waddington M, Greenberg D, Schreckenberger PC, Carnahan AM. Atypical *Chryseobacterium meningosepticum* and meningitis and sepsis in newborns and the immunocompromised, Taiwan. *Emerg Infect Dis*. 2000;6(5):481–6. doi: [10.3201/eid0605.000506](https://doi.org/10.3201/eid0605.000506). [PubMed: [10998378](https://pubmed.ncbi.nlm.nih.gov/10998378/)]. [PubMed Central: [PMC2627967](https://pubmed.ncbi.nlm.nih.gov/PMC2627967/)].
- Boroda K, Li L. *Elizabethkingia meningosepticum* in a patient with six-year bilateral perma-catheters. *Case Rep Infect Dis*. 2014;2014:985306. doi: [10.1155/2014/985306](https://doi.org/10.1155/2014/985306). [PubMed: [25161782](https://pubmed.ncbi.nlm.nih.gov/25161782/)]. [PubMed Central: [PMC4139023](https://pubmed.ncbi.nlm.nih.gov/PMC4139023/)].
- Bellais S, Poirel L, Naas T, Girlich D, Nordmann P. Genetic-biochemical analysis and distribution of the Ambler class A beta-lactamase CME-2, responsible for extended-spectrum cephalosporin resistance in *Chryseobacterium* (*Flavobacterium*) *meningosepticum*. *Antimicrob Agents Chemother*. 2000;44(1):1–9. [PubMed: [10602714](https://pubmed.ncbi.nlm.nih.gov/10602714/)]. [PubMed Central: [PMC89619](https://pubmed.ncbi.nlm.nih.gov/PMC89619/)].
- Hung PP, Lin YH, Lin CF, Liu MF, Shi ZY. *Chryseobacterium meningosepticum* infection: Antibiotic susceptibility and risk factors for mortality. *J Microbiol Immunol Infect*. 2008;41(2):137–44. [PubMed: [18473101](https://pubmed.ncbi.nlm.nih.gov/18473101/)].
- Gonzalez LJ, Vila AJ. Carbapenem resistance in *Elizabethkingia meningoseptica* is mediated by metallo-beta-lactamase BlaB. *Antimicrob Agents Chemother*. 2012;56(4):1686–92. doi: [10.1128/AAC.05835-11](https://doi.org/10.1128/AAC.05835-11). [PubMed: [22290979](https://pubmed.ncbi.nlm.nih.gov/22290979/)]. [PubMed Central: [PMC3318372](https://pubmed.ncbi.nlm.nih.gov/PMC3318372/)].

9. Perera S, Palasuntheram C. Chryseobacterium meningosepticum infections in a dialysis unit. *Ceylon Med J*. 2004;**49**(2):57-60. [PubMed: [15334801](#)].
10. Lin YT, Chan YJ, Chiu CH, Lin ML, Yu KW, Wang FD, et al. Tigecycline and colistin susceptibility of Chryseobacterium meningosepticum isolated from blood in Taiwan. *Int J Antimicrob Agents*. 2009;**34**(1):100-1. doi: [10.1016/j.ijantimicag.2009.01.011](#). [PubMed: [19261450](#)].
11. Hsu MS, Liao CH, Huang YT, Liu CY, Yang CJ, Kao KL, et al. Clinical features, antimicrobial susceptibilities, and outcomes of Elizabethkingia meningoseptica (Chryseobacterium meningosepticum) bacteremia at a medical center in Taiwan, 1999-2006. *Eur J Clin Microbiol Infect Dis*. 2011;**30**(10):1271-8. doi: [10.1007/s10096-011-1223-0](#). [PubMed: [21461847](#)].
12. Dias M, Fernandes A, Furtado Z. Case series: Elizabethkingia meningosepticum. *J Clin Diagn Res*. 2012;**6**(9):1550-1. doi: [10.7860/JCDR/2012/4076.2557](#). [PubMed: [23285454](#)]. [PubMed Central: [PMC3527794](#)].
13. Lee CH, Lin WC, Chia JH, Su LH, Chien CC, Mao AH, et al. Community-acquired osteomyelitis caused by Chryseobacterium meningosepticum: Case report and literature review. *Diagn Microbiol Infect Dis*. 2008;**60**(1):89-93. doi: [10.1016/j.diagmicrobio.2007.07.009](#). [PubMed: [17889489](#)].
14. Bayrak B, Fincanci M, Binay UD, Cimen C, Ozkantar Unlugunes GU. [Elizabethkingia meningosepticum bacteremia in a patient with Bardet-Biedl syndrome and chronic renal failure]. *Mikrobiyol Bul*. 2014;**48**(3):495-500. Turkish. [PubMed: [25052117](#)].
15. Soman R, Agrawal U, Suthar M, Desai K, Shetty A. Successful management of Elizabethkingia meningoseptica meningitis with intraventricular vancomycin. *J Assoc Physicians India*. 2016;**64**(10):98-9. [PubMed: [27766817](#)].
16. Esteban I, Morales C, Pinheiro JL, Galvan ME, Isasmendi A, Castanos C. [Bullous pneumonia secondary to Elizabethkingia meningoseptica, its clinical and radiological evolution]. *Arch Argent Pediatr*. 2019;**117**(2):e150-4. Spanish. doi: [10.5546/aap.2019.e150](#). [PubMed: [30869495](#)].
17. Tai IC, Liu TP, Chen YJ, Lien RI, Lee CY, Huang YC. Outbreak of Elizabethkingia meningoseptica sepsis with meningitis in a well-baby nursery. *J Hosp Infect*. 2017;**96**(2):168-71. doi: [10.1016/j.jhin.2016.11.018](#). [PubMed: [28077242](#)].
18. Yang J, Xue W, Yu X. Elizabethkingia meningosepticum endocarditis: A rare case and special therapy. *Anatol J Cardiol*. 2015;**15**(5):427-8. doi: [10.5152/akd.2015.6014](#). [PubMed: [25993718](#)]. [PubMed Central: [PMC5779184](#)].
19. Yue D, Song C, Zhang B, Liu Z, Chai J, Luo Y, et al. Hospital-wide comparison of health care-associated infection among 8 intensive care units: A retrospective analysis for 2010-2015. *Am J Infect Control*. 2017;**45**(1):e7-13. doi: [10.1016/j.ajic.2016.10.011](#). [PubMed: [27856076](#)].
20. Wang M, Wei H, Zhao Y, Shang L, Di L, Lyu C, et al. Analysis of multidrug-resistant bacteria in 3223 patients with hospital-acquired infections (HAI) from a tertiary general hospital in China. *Bosn J Basic Med Sci*. 2019;**19**(1):86-93. doi: [10.17305/bjbm.2018.3826](#). [PubMed: [30579325](#)]. [PubMed Central: [PMC6387671](#)].