



Drug Reaction with Eosinophilia and Systemic Symptoms (DRESS) Presenting with Primary Diagnosis of Hepatocellular Carcinoma

Ahmad Hormati ^{1,2}, Faezeh Alemi ¹, Seyed Hasan Adeli ³ and Mohaddeseh Zojaji ^{4,*}

¹Gastroenterology and Hepatology Disease Research Center, Qom University of Medical Sciences, Qom, Iran

²Gastrointestinal and Liver Disease Research Center, Firoozgar Hospital, Iran University of Medical Sciences, Tehran, Iran

³Faculty of Medicine, Qom University of Medical Sciences, Qom, Iran

⁴Gastroenterology and Hepatology Disease Research Center, Shahid Beheshti Hospital, Qom University of Medical Sciences, Qom, Iran

*Corresponding author: Gastroenterology and Hepatology Disease Research Center, Shahid Beheshti Hospital, Qom University of Medical Sciences, Qom, Iran. Email: mohaddeseh.zojaji@gmail.com

Received 2019 October 22; Accepted 2020 February 12.

Abstract

Drug reaction with eosinophilia and systemic symptoms (DRESS) syndrome is an uncommon systemic allergic reaction, which usually occurs due to a specific medication. The most common presentation is fever, skin eruption, and lymphadenopathy that presents two to eight weeks after exposure to the culprit drug. In some cases, evidence of internal organ involvement including renal failure, respiratory symptoms, or liver involvement may present. These symptoms may present weeks to months after the exposure or even discontinuing the drug, which makes the diagnosis challenging. This report presents a young man with first presentation of icter and elevated liver enzymes, whose laboratory and imaging studies failed to diagnose the disease. A liver biopsy was performed and the pathologist reported hepatocellular carcinoma (HCC). A high level of serum alpha-fetoprotein was consistent with the histologic findings, but concerning the uncommon clinical setting, the pathologic specimen was reviewed by another pathologist, which reported hepatocyte regeneration following hepatitis. This finding was consistent with elevated serum alpha-fetoprotein. A retrospective review revealed the history of using ceftriaxone nine months before the presentation and his final diagnosis was the DRESS syndrome with a dramatic response to corticosteroid treatment.

Keywords: Hepatitis, Drug Hypersensitivity Syndrome, Carcinoma, Hepatocellular

1. Introduction

Drug reaction with eosinophilia and systemic symptoms (DRESS) syndrome is a rare condition, characterized by a systemic allergic reaction, usually to a medication. The prevalence of this condition is estimated at approximately one in 5,000 to 10,000 cases of the prescription of suspected causal drugs. This reaction may be delayed; it is usually long-standing and in some cases starts or continues even after discontinuation of the causal drug. Classic presentations of the disease are fever, rash, lymphadenopathy, and serum eosinophilia. However, it can lead to multi-organ failure, including liver failure, cardiac, renal, and lung involvement, which may be severe enough to cause mortality. The mortality rate due to severe DRESS syndrome is estimated at approximately 10% (1, 2).

The diagnosis of the DRESS syndrome is challenging due to its low prevalence, chronic and progressive nature of the disease, and extended and somehow confusing list of its differential diagnosis.

Here, we introduce a case of DRESS syndrome whose

first presentation was a hepatic failure with pathologic features of hepatocellular carcinoma (HCC).

2. Case Presentation

A 17-year-old man presented to our gastroenterology clinic with a complaint of epigastric pain, nausea, and icter within the past month. In the description of the course of the disease, he mentioned fever and coryza nine months ago, which was treated with three doses of intramuscular ceftriaxone injection. After receiving the third dose, the patient showed allergic reactions including erythema in the whole of the body and swelling of eyelids. He was admitted to a hospital and treated with intravenous and oral corticosteroids for two weeks. After 10 days of treatment, the patient presented to the hospital again with frequent cough, which led to cyanosis and hypoxia. Bronchoalveolar lavage confirmed the diagnosis of CMV and Pneumocystis carinii pneumonia. He was admitted to ICU and treated with co-trimoxazole and ganciclovir. After two months, the

present illness began with generalized bone pain, poor appetite, weight loss, epigastric pain, and icter.

His vital signs at presentation included blood pressure 120/70 mmHg, pulse rate 100/min, respiratory rate 14/min, and body temperature 38°C (oral root). In the general appearance, his sclera and skin seemed icteric. In the physical examination of the abdomen, the liver and the spleen were palpable three centimeters below the costal margin, with a soft consistency. No evidence of fluid accumulation or mass was detected. Evidence of candidiasis was seen in the oral cavity. The rest of the examination had no significant positive or negative points. The results of the blood tests are summarized in Table 1 that indicated a direct hyperbilirubinemia, elevated transaminase level, and eosinophilia.

Table 1. Results of Primary Blood Tests

Lab Test	Measured Value	Normal Range
WBC, μ L	12700	4000 - 11000
Eosinophilia, %	26	
Lymph, %	10.5	
Neut, %	60	
Hb, g/dL	12.3	12 - 16
PLT, μ L	239000	150.000 - 450.000
Bil Direct, mg/dL	20.4	< 0.4
Bil total, mg/dL	29.3	< 2
AST, U/L	660	Up to 35
ALT, U/L	673	Up to 45
ALKP, IU/L	324	98 - 279
INR	1.18	1 - 1.17
BUN, mg/dL	11.2	6 - 20
Creatinine, mg/dL	0.5	0.5 - 1.2
Amylase, IU/L	69	< 100
LDH, IU/L	225	122 - 222

An abdominal ultrasound study detected hepatosplenomegaly with no evidence of mass or fluid. The abdominopelvic CT scan revealed a minimal fluid accumulation in the abdomen with no evidence of mass or cystic lesion in the liver. Further evaluations were performed on blood, urine, and fecal samples, including viral hepatitis A, B, and C markers, fecal and serology of Strongyloides parasite, rheumatologic markers including ESR, CRP, ANCA, FANA, Anti Sm and Anti SSA, FISH, and RT-PCR for rolling out leukemia and lymphoma and ASMA and ANA as the serologic markers for autoimmune hepatitis, all of which showed no diagnostic results.

Finally, the patient was a candidate for liver biopsy for

diagnosis (Figure 1). The pathologic study of liver tissue revealed diffuse-type clear cell hepatocellular carcinoma. The serum alpha-fetoprotein level was 2,500 ng/dL (with a normal range of 10 - 15 μ g/L). Concerning the unusual presentation, another expert pathologist in a referral center studied the pathologic specimen. The second study reported the presence of premature hepatocytes because of hepatic regeneration. The high level of alpha-fetoprotein was explainable with the report.

The final diagnosis was a drug reaction to ceftriaxone or DRESS syndrome. Autoimmune cholangiopathy, which presents with evidence of hepatitis with cholestatic pattern in laboratory tests, could be a differential diagnosis. However, it was rolled out concerning negative autoantibodies, non-compatible liver histology, and no recurrence of symptoms after tapering corticosteroid.

The patient was treated with high-dose prednisone and clinical and laboratory symptoms completely resolved within one month. Then, corticosteroids were tapered within the next two months and in the next three-month follow-up, he had no signs and symptoms representing recurrence.

3. Discussion

DRESS syndrome is a severe drug reaction, which presents with skin eruptions, hematologic disorders (including atypical lymphocytosis and eosinophilia), lymphadenopathy, and involvement of the liver, lung, or kidneys. The disease presents after two to eight weeks of incubation period from the drug exposure. The symptoms may continue or recur, despite discontinuing the medication (3-5).

The underlying cause of the allergic reaction is a drug, which is usually discovered by taking a precise and targeted history. A broad spectrum of drugs had been reported in case reports as the culprit agents of DRESS syndrome among which, anticonvulsants including carbamazepine, lamotrigine, and phenobarbital account for one-third of cases. Some antibiotics and antiretroviral drugs including vancomycin, sulfamethoxazole, and abacavir have been reported in a few case reports; however, concerning the small number of reports, it is not exactly clear that the main cause of the reaction is due to these drugs, or it was only synchronism. Patients' clinical presentations usually include fever, skin eruptions, edema, and eosinophilia (more than 700 eosinophils per μ L) (6, 7).

Some autoimmune diseases including type 1 diabetes mellitus, Grave's disease, and autoimmune hemolytic anemia present in some DRESS syndrome patients within months to years after recovery. Although the DRESS syndrome can affect multiple organs, the most affected in-

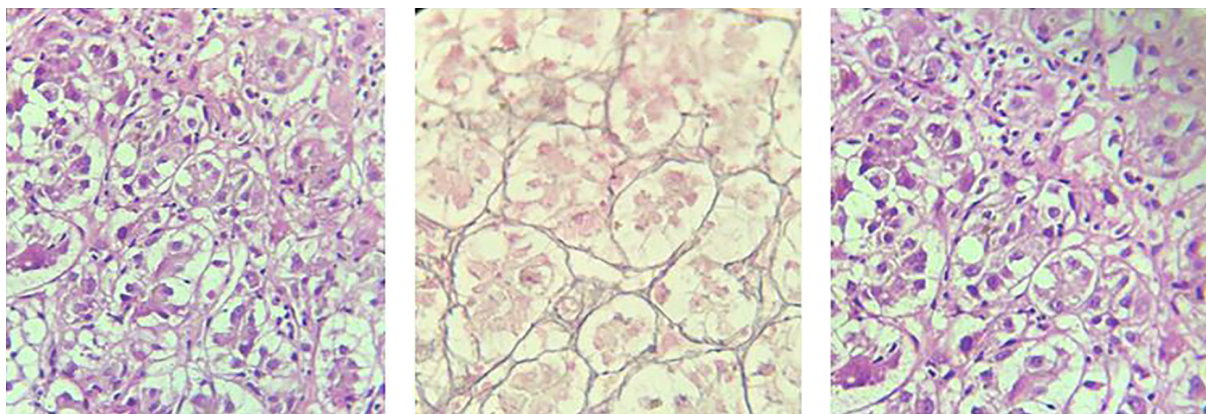


Figure 1. Pathologic view of liver tissue

ternal organ is the liver. The prognosis of the patient directly depends on the degree of liver injury and in severe cases, it is accompanied by a high mortality rate. The registry of the International Study Group Investigating Severe Cutaneous Reactions (RegiSCAR) scoring system defined diagnostic criteria for the DRESS syndrome and liver failure due to DRESS. The diagnostic criteria for acute liver injury (ALI)/acute liver failure (ALF) include serum transaminases levels of greater than $\times 2$ upper limit of normal (ULN) or serum bilirubin of greater than $\times 2$ ULN for two consecutive days or serum glutamic-oxaloacetic transaminase (SGOT), gamma-glutamyl transferase (GGT), and alkaline phosphatase of greater than $\times 2$ ULN at least in one measurement (8, 9). In the case of severe liver dysfunction, liver transplantation can increase the patients' survival although no standard golden time has been defined for transplantation in the literature (10).

Liver histology in most of the available case reports presents inflammation, lymphocyte activation, eosinophil infiltration, intralobular necrosis, and Kupffer cell hyperplasia. The study of liver histology in these cases was performed at the first 48 h of admission (10). In our patient, premature hepatocytes were dominant in the liver histology, which was due to hepatocyte regeneration following liver damage.

Patients should manage supportively. The main step is to discontinue the suspected drug and to avoid any other new medications. In the case of mild cutaneous symptoms, management could be in an ambulatory setting with topical potent corticosteroids, warm bath, and emollients. Patients with severe symptoms or the involvement of internal organs need hospital admission.

Fluid resuscitation, management of electrolyte disturbance, and nutritional support are primary and necessary

issues in such patients. In the case of asymptomatic renal and pulmonary involvement or liver involvement with liver enzymes of less than three times of normal upper limit, supportive treatment including skincare and hydration will be sufficient (2, 11, 12).

Patients with the symptoms of pulmonary involvement (dyspnea, hypoxemia, or radiologic abnormalities) or renal involvement (elevation in serum creatinine, proteinuria, or hematuria) should receive high-dose systemic corticosteroid (0.5 to 2 mg/kg/day prednisone) until clinical and laboratory abnormalities are resolved and tapered within eight to 12 weeks. The effectiveness of systemic corticosteroids in liver involvement and acute hepatitis is controversial. If symptoms of fulminant hepatitis present, liver transplantation may be a reasonable decision (13-15). In the case of organ failure with unresponsiveness to systemic corticosteroids, cyclosporine is the next step of treatment. In a stable clinical setting, the patients' follow-up should be performed by CBC, liver enzymes, PT, bilirubin, BUN, and creatinine, weekly. Complete remission usually occurs within three months.

Footnotes

Authors' Contribution: None declared.

Conflict of Interests: All authors confirm that they have no conflict of interest regarding the publication of the present article.

Ethical Approval: None declared.

Funding/Support: Nothing to disclose.

Informed Consent: Informed consent was signed by the patient.

References

1. Descamps V, Ranger-Rogez S. DRESS syndrome. *Joint Bone Spine*. 2014;**81**(1):15–21. doi: [10.1016/j.jbspin.2013.05.002](https://doi.org/10.1016/j.jbspin.2013.05.002). [PubMed: 23816504].
2. Corneli HM. DRESS syndrome: Drug reaction with eosinophilia and systemic symptoms. *Pediatr Emerg Care*. 2017;**33**(7):499–502. doi: [10.1097/PEC.0000000000001188](https://doi.org/10.1097/PEC.0000000000001188). [PubMed: 28665896].
3. Kimura I, Takahashi K. Inflammatory role of eosinophil in allergic reactions. *Nippon Rinsho*. 1993;**51**(3):651–6.
4. Bocquet H, Bagot M, Roujeau JC. Drug-induced pseudolymphoma and drug hypersensitivity syndrome (drug rash with eosinophilia and systemic symptoms: DRESS). *Semin Cutan Med Surg*. 1996;**15**(4):250–7. doi: [10.1016/s1085-5629\(96\)80038-1](https://doi.org/10.1016/s1085-5629(96)80038-1). [PubMed: 9069593].
5. Husain Z, Reddy BY, Schwartz RA. DRESS syndrome: Part I. Clinical perspectives. *J Am Acad Dermatol*. 2013;**68**(5):693 e1–14. quiz 706–8. doi: [10.1016/j.jaad.2013.01.033](https://doi.org/10.1016/j.jaad.2013.01.033). [PubMed: 23602182].
6. Cacoub P, Musette P, Descamps V, Meyer O, Speirs C, Finzi L, et al. The DRESS syndrome: A literature review. *Am J Med*. 2011;**124**(7):588–97. doi: [10.1016/j.amjmed.2011.01.017](https://doi.org/10.1016/j.amjmed.2011.01.017). [PubMed: 21592453].
7. Chen YC, Chang CY, Cho YT, Chiu HC, Chu CY. Long-term sequelae of drug reaction with eosinophilia and systemic symptoms: A retrospective cohort study from Taiwan. *J Am Acad Dermatol*. 2013;**68**(3):459–65. doi: [10.1016/j.jaad.2012.08.009](https://doi.org/10.1016/j.jaad.2012.08.009). [PubMed: 22959230].
8. Kardaun SH, Sekula P, Valeyrie-Allanore L, Liss Y, Chu CY, Creamer D, et al. Drug reaction with eosinophilia and systemic symptoms (DRESS): an original multisystem adverse drug reaction. Results from the prospective RegiSCAR study. *Br J Dermatol*. 2013;**169**(5):1071–80. doi: [10.1111/bjd.12501](https://doi.org/10.1111/bjd.12501). [PubMed: 23855313].
9. Kardaun SH, Sidoroff A, Valeyrie-Allanore L, Halevy S, Davidovici BB, Mockenhaupt M, et al. Variability in the clinical pattern of cutaneous side-effects of drugs with systemic symptoms: Does a DRESS syndrome really exist? *Br J Dermatol*. 2007;**156**(3):609–11. doi: [10.1111/j.1365-2133.2006.07704.x](https://doi.org/10.1111/j.1365-2133.2006.07704.x). [PubMed: 17300272].
10. Ichai P, Laurent-Bellue A, Saliba F, Moreau D, Besch C, Francoz C, et al. Acute liver failure/injury related to drug reaction with eosinophilia and systemic symptoms: Outcomes and prognostic factors. *Transplantation*. 2017;**101**(8):1830–7. doi: [10.1097/TP.0000000000001655](https://doi.org/10.1097/TP.0000000000001655). [PubMed: 28207633].
11. Chen YC, Chiu HC, Chu CY. Drug reaction with eosinophilia and systemic symptoms: a retrospective study of 60 cases. *Arch Dermatol*. 2010;**146**(12):1373–9. doi: [10.1001/archdermatol.2010.198](https://doi.org/10.1001/archdermatol.2010.198). [PubMed: 20713773].
12. Um SJ, Lee SK, Kim YH, Kim KH, Son CH, Roh MS, et al. Clinical features of drug-induced hypersensitivity syndrome in 38 patients. *J Investig Allergol Clin Immunol*. 2010;**20**(7):556–62. [PubMed: 21313995].
13. Uhara H, Saiki M, Kawachi S, Ashida A, Oguchi S, Okuyama R. Clinical course of drug-induced hypersensitivity syndrome treated without systemic corticosteroids. *J Eur Acad Dermatol Venereol*. 2013;**27**(6):722–6. doi: [10.1111/j.1468-3083.2012.04547.x](https://doi.org/10.1111/j.1468-3083.2012.04547.x). [PubMed: 22540194].
14. Funck-Brentano E, Duong TA, Bouvresse S, Bagot M, Wolkenstein P, Roujeau JC, et al. Therapeutic management of DRESS: A retrospective study of 38 cases. *J Am Acad Dermatol*. 2015;**72**(2):246–52. doi: [10.1016/j.jaad.2014.10.032](https://doi.org/10.1016/j.jaad.2014.10.032). [PubMed: 25592341].
15. Davern TJ. Drug-induced liver disease. *Clin Liver Dis*. 2012;**16**(2):231–45. doi: [10.1016/j.cld.2012.03.002](https://doi.org/10.1016/j.cld.2012.03.002). [PubMed: 22541696].