



Effects of Cyclosporine Therapy on Liver and Kidney Retrieval in Poisoned Male Rats by *Mesobuthus eupeus* Scorpion Venom

Sara Zangiabadi¹, Shahrokh Navidpour², Hossein Zolfagharian³ and Gholamhassan Vaezi^{1, *}

¹Department of Biology, Damghan Branch, Islamic Azad University, Damghan, Iran

²Razi Reference Laboratory of Scorpion Research, Razi Vaccine and Serum Research Institute, Agricultural Research Education and Extension Organization, Karaj, Iran

³Department of Venomous Animal and Antivenom Production, Razi Vaccine and Serum Research Institute, Agricultural Research, Education and Extension Organization (AREEO), Tehran, Iran

*Corresponding author: Department of Biology, Damghan Branch, Islamic Azad University, Damghan, Iran. Email: gh.vaezi@yahoo.com

Received 2020 January 20; Revised 2020 April 15; Accepted 2020 June 07.

Abstract

Background: *Mesobuthus eupeus* venom is a member of Buthidae family, which can enter the blood circulation exerting detrimental effects on body organs, such as the liver and kidney through inflammation. Cyclosporine, known as an anti-inflammatory drug, is used to treat many inflammation-associated diseases.

Objectives: In this study, cyclosporine was selected to inhibit the scorpion toxin effects on rat organs.

Methods: This experimental study was conducted in the Razi Vaccine and Serum Research Institute, Agricultural Research Education and Extension Organization, Karaj, Iran, from June to November 2019. Fifty male rats were randomly divided into five groups of 10, including the control (10 mg/kg olive oil i.p.), *M. eupeus* venom (10 mg/kg i.p.), cyclosporine 10 mg/kg (venom 10 mg/kg for 30 min i.p followed by cyclosporine 10 mg/kg for 7 day i.p.), cyclosporine 20 mg/kg (venom 10 mg/kg for 30 min i.p followed by cyclosporine 20 mg/kg for 7 day i.p.), and cyclosporine 30 mg/kg (venom 10 mg/kg for 30 min i.p followed by cyclosporine 30 mg/kg for 7 day i.p.). After treatment with cyclosporine, the liver and kidney function was analyzed by calculating some biochemical enzymes, including serum glutamate-pyruvate transaminase (SGPT), serum glutamic oxaloacetic transaminase (SGOT), nitric oxide (NO), interleukin-2 (IL-2), malondialdehyde (MDA), creatinine, and urea via ELISA and spectrophotometry. Then, to determine the rate of apoptosis in tissue, terminal deoxynucleotidyl transferase-mediated dUTP nick-end labeling method was done.

Results: At the end of the study, the results showed a significant elevation in SGPT (164.5 ± 10 vs. 126.2 ± 7 , $P < 0.0001$), SGOT (190.37 ± 11 vs. 148 ± 10 , $P < 0.0001$), NO (24.4 ± 1.17 vs. 17.4 ± 1.4 , $P = 0.02$), and MDA (0.42 ± 0.05 vs. 0.22 ± 0.04 , $P < 0.0001$) in the venom group compared with the control group. There were no significant differences in the urea, IL-2, and creatinine between the venom and control groups. However, the group receiving cyclosporine (30 mg/kg) showed a significant decline in SGPT (96.42 ± 5.7 vs. 164.5 ± 10 , $P < 0.0001$), SGOT (144.57 ± 9.24 vs. 190.37 ± 11 , $P < 0.0001$), urea (28.83 ± 1.32 vs. 38.83 ± 1.6 , $P = 0.00$), creatinine (0.023 ± 0.01 vs. 0.29 ± 0.005 , $P < 0.0001$), and MDA (0.10 ± 0.01 vs. 0.42 ± 0.05 , $P < 0.0001$), as well as increased apoptosis rate ($P < 0.05$), compared with the venom group. No significant difference was observed between the cyclosporine and venom groups in NO and IL-2.

Conclusions: Cyclosporine at a dose of 30 mg was able to decrease inflammatory responses and induce apoptosis rate. Therefore, it could be a suitable drug for patients bitten by a scorpion sting.

Keywords: Mesobuthus, Venom, Cyclosporine

1. Background

The scorpion is among the first animals to have become fully terrestrialised and adapted to the surrounding environments. Scorpions are arthropods, of which 1250 species have been identified. The scorpion venom has more than one million types of peptides, but unfortunately, only 200 peptides have been determined until today (1, 2). *Mesobuthus eupeus* scorpion is one of the most important scorpions in Iran, which does not have any dis-

persion in other parts of the world (3). Generally, this scorpion is found in tropical regions of Iran, specifically in the southern tropical regions.

Scorpion venoms consist of mucopolysaccharides, hyaluronidase, phospholipases, enzyme inhibitors, neurotoxins, histamine releasers, protease inhibitors, amino acids, and enzymes (hyaluronidases and metalloproteases) (4). The clinical manifestations of the scorpion sting in humans are very variable and are varied depending on the type of scorpion, host, and venom. The scorpion

sting can manifest itself in different ways from severe localized skin reactions to nervous symptoms, cardiorespiratory changes, edema, and a systemic inflammatory response (5). Activation of the complex signaling pathways is involved in the pathogenesis of scorpion sting, with oxidative stress and inflammation being considered as the primary routes of tissue destruction after venom injection (5, 6). After scorpion stings, various mechanisms induce the activation of immune cells, including neurotoxins that, by activating ion channels on the nerve release neurotransmitters and peptides, ultimately triggers an inflammatory response (7). This inflammatory response causes metabolic disorders and damages various organs (8).

The kidneys and liver are considered as the most important sites for the excretion of the venom and are highly vulnerable to the toxin (9). These tissues can then be directly affected by the venom by its toxins or indirectly through the release of mediators and modulators, such as cytokines, oxygen-free radicals, neurotransmitters, etc. (9). Unlike other components of the venom, toxins appear very quickly in the bloodstream and accumulate in the liver and kidney tissues, causing direct damage (10). In other words, the binding of toxins to specific receptors on the vascular ion channels by the release of catecholamines and angiotensin II causes severe vasoconstriction and ultimately leads to ischemia and further damages (11). Hence, it is necessary to find some effective therapeutic approaches to deal with the scorpion sting.

Cyclosporine is considered to be a widespread drug for reducing inflammation because of its anti-inflammation effects. For example, cyclosporine prevents the secretion of tumor necrosis factor-alpha (TNF- α) and interleukin-2 (IL-2) in monocyte-derived dendritic cells (DCs) and bone marrow-derived dendritic cells (BMDCs) (12-14). This anti-inflammatory drug has less solubility in water and is produced in the forms of suspension and emulsion for treating some diseases, including rheumatoid arthritis, psoriasis, and Crohn's disease (15). Cyclosporine is composed of aromatic peptides, which affect T lymphocyte cells to prevent cytokines production, especially IL-2 after exposure to antigens (16, 17).

2. Objectives

Scorpion stings have considered as one of the major health problems in Iran. There is no effective and specific treatment to prevent local and systemic complications of the scorpion sting. Also, inflammation and oxidative stress are involved in the pathogenesis of scorpion stings (6, 9). Because of the anti-inflammatory and anti-oxidant effects of cyclosporine, we designed this experimental study to

investigate the potential effects of cyclosporine, a powerful anti-inflammatory drug, on reducing *M. eupeus* venom damage on liver function, kidney performance, oxidative stress, and inflammation. Specifically, we evaluated the effects of cyclosporine on histological abnormalities of the kidney and liver once the rat groups received venom.

3. Methods

This experimental study was conducted in the Razi Vaccine and Serum Research Institute, Agricultural Research Education and Extension Organization, Karaj, Iran, from June to November 2019. This institute is known as a national pharmaceutical company. Likewise, it is the reference and government institution for the production of anti-venom serums derived from snake and scorpion venom, where scientists are constantly studying the development of new drugs and vaccines to reduce the complications of the venom. This study was approved by the State Committee on Animal Ethics, Razi Vaccine and Serum Research Institute, Agricultural Research Education and Extension Organization, Karaj, Iran (ethics code: RVSRI.REC.980003; 2019/5/6). In this experimental study, the protocol and experiments were performed following the National Institutes of Health for animal studies (NIH, Bethesda, MD, USA). Also, the study was conducted in accordance with the Basic and Clinical Pharmacology Toxicology policy for experimental and clinical studies (18).

The sample size was calculated according to the difference in the mean of urea concentration based on the study conducted by Lamraoui et al. (19). It was determined considering a 95% confidence interval, 80% power ($\alpha = 0.05$ and $\beta = 0.02$), and the related mean and Standard deviation of the urea levels in the study. In this study, the calculated sample size for each group was 10 rats.

$$\begin{aligned} s1 &= 4.74 \\ s2 &= 19.35 \\ m1 &= 41.7 \\ m2 &= 53.59 \\ \alpha &= 0.05 \\ \beta &= 0.2 \\ n/\text{group} &= 10 \end{aligned}$$

$$n = \frac{\left(Z_{1-\frac{\alpha}{2}} + Z_{1-\beta} \right)^2 (\delta_1^2 + \delta_2^2)}{(\mu_1 - \mu_2)^2} \quad (1)$$

3.1. Materials

A total of 50 five-week-old male rats (25 g \pm 10 g) were obtained from the Pasteur Institute (Tehran, Iran). *M. eupeus* was used with the venom of this scorpion made in the Razi Vaccine and Serum Research Institute

(Karaj, Iran). Olive oil (8001-25-0), solid paraffin (br/107162), hematoxylin and eosin stain (115935), ethanol (200-578-6), and resin (101691) were prepared from the Merck Company (Germany). Cyclosporine was bought from Novartis Company (Switzerland). In situ cell death detection kit (11684795910) was purchased from the Sigma Aldrich Company. In this study, all equipment, including ELISA Microplate Washer (Bio-Tek, VA, USA), ELISA Microplate Reader (Bio-Tek, VA, USA), spectrophotometer (Cecil Instruments Ltd., Cambridge, UK), Homogenizer (Omni International, Warrenton, VA, USA), inverted confocal microscope (Olympus, Tokyo, Japan) were calibrated according to the standard protocols before the usage.

3.2. Animals

The animals were housed under a standard light/dark cycle (12-hour light/12-hour darkness circulation), humidity (65% \pm 10%), and controlled temperature (22°C \pm 2°C). Also, they had ad libitum access to water and food. After one week of acclimatization period, the rats were randomly divided into five groups (n = 10 per group) using simple randomization: group A: olive oil as control (10 mg/kg intraperitoneally (i.p.)), group 2: venom (10 mg/kg i.p.), group 3: venom (10 mg/kg) + cyclosporine (10 mg/kg i.p.), group 4: venom (10 mg/kg) + cyclosporine (20 mg/kg i.p.), group 5: venom (10 mg/kg) + cyclosporine (30 mg/kg i.p.).

3.3. Experimental Protocol

The control group received olive oil (10 mg, i.p.) with *M. eupeus* venom being i.p. injected as a single dose on the first day (10 mg, i.p.). After 30 min of venom injection, cyclosporine was administered daily for 7 days (10, 20, and 30 mg/kg, i.p.).

The body weight was measured every day during the study. Blood sampling was carried out from the heart and centrifuged at 3000 rpm for 10 min to separate supernatant plasma. Serum glutamate-pyruvate transaminase (SGPT), serum glutamic oxaloacetic transaminase (SGOT), malondialdehyde (MDA), nitric oxide (NO), urea, and creatinine concentrations were determined using the enzymatic colorimetric assay (Parsazmoun, Iran). Serum IL-2 concentration was measured using the ELISA kit (Zellbio GmbH Company, Germany). At the end of the procedure, the rats were anesthetized and sacrificed, and tissue samples (liver and kidney) were collected and stored at -80 immediately for the TUNEL test.

3.4. Histopathologic Examination

The liver and kidney were withdrawn for pathologic examination. These organs were fixed in 10% neutral

buffered formalin. The fixed samples were dehydrated in ethanol, cleared in methyl benzoate, and embedded in paraffin wax. Preparation of the sections 5-6- μ in thickness was performed using a microtome, they were stained with hematoxylin and eosin, and observed under a light microscope. The sections were assessed based on the severity of the pathological changes.

3.5. TUNEL POD Assay-Labeling

To detect the apoptosis rate in individual cells, we used the terminal deoxynucleotidyl transferase-mediated dUTP nick end labeling (In Situ Cell Death Detection Kit, POD (11684817910)) method. The procedure was conducted according to the manufacturer's protocol (Roche, Germany). First, the tissues were incubated in xylene (Merck, 108681) for 10 min after paraffin decontamination. Then, the slides were irrigated in 90%, 80%, and 70% alcohols, respectively. Subsequently, the slides were washed with phosphate buffer saline ((PBS, pH 7.4): 137 mM NaCl, 2.7 mM KCl, 1.5 mM KH₂PO₄, 8.1 mM Na₂HPO₄ in distilled water) and incubated for 20 min/RT by a protein kinase. Next, the tissues were incubated with citrate buffer (10 min) to be permeable and were washed with PBS. In the last stage, the samples were incubated by TUNEL stain (50 μ L) and incubated for 1 hat 37°C. The slides were observed by a Zeiss LSM 5 fluorescent microscope. Regarding the positive controls, the sections were incubated with DNase I (3000 U/mL in 50 mM Tris-HCl, pH 7.5, 1 mg/mL BSA) for 10 min at 15 - 25°C to induce DNA strand breaks before the labeling procedure and a known positive control was used as an alternative. Concerning the negative control, the sections were incubated with the label solution only (without terminal transferase) instead of the TUNEL reaction mixture. The apoptotic cells in this tissue were bright spots representing the apoptotic cells labeled during TUNEL staining. The cell's nucleus was stained with propidium iodide (1 mg/ml), after which the apoptotic cells stained with TUNEL (green) were differentiated from normal cells.

3.6. Statistical Analysis

Data were presented as the mean \pm standard deviation. The data analysis was carried out using GraphPad Prism 8.3 software. Initially, the normal distribution of all variables was evaluated with the Kolmogorov-Smirnov test. Then, Two-way analysis of variance (ANOVA) followed by Tukey's test were applied to compare the statistical significance among the experimental groups. The results showed that the Kappa index was above 0.6, which means that the obtained data had the same scores. P values of less than 0.05 were considered significant.

4. Results

4.1. SGPT, SGOT, UREA, CREATININE, NO, MDA, and IL-2 Analysis

4.1.1. SGPT and SGOT

Liver damage was measured by evaluating SGPT and SGOT enzymes. SGPT and SGOT significantly increased in the venom-injected rats (Table 1). Expectedly, cyclosporine therapy reduced the SGPT and SGOT concentrations; cyclosporine 10, 20, 30 mg, respectively, reduced the mentioned enzymes concentration significantly in a dose-dependent manner (Figure 1).

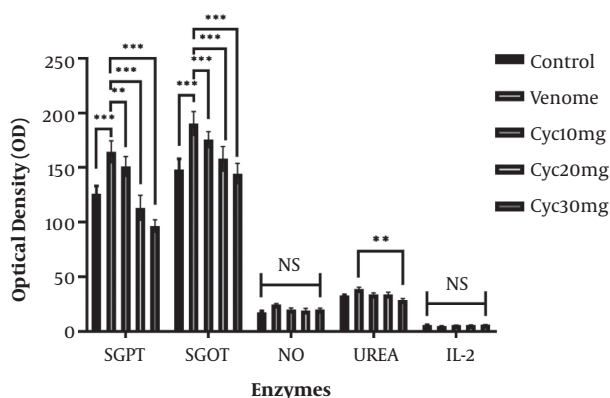


Figure 1. Serum concentrations of serum glutamate-pyruvate transaminase (SGPT), serum glutamic oxaloacetic transaminase (SGOT), Urea, nitric oxide (NO), and interleukin-2 (IL-2) in the control and poisoned rats after therapy with cyclosporine at the doses of 10, 20, and 30 mg. Venom stimulated the secretion and production of all enzymes except for IL-2. Treatment with cyclosporine reduced the concentration of all enzymes in the rat serum. Cyclosporine (30 mg) had significant effects on all factors, except for IL-2 and NO. In the chart, the venom effects were compared with the control and cyclosporine effects were compared with venom to identify the effects of venom and cyclosporine. In the bar chart, C signals cyclosporine. The stars reveal the rate of significance (*P value < 0.05, **0.05 < P value < 0.01, ***P value < 0.01).

4.1.2. Creatinine and Urea

The concentration of these enzymes was analyzed to examine the kidney function. Venom-injected rats showed significantly higher creatinine and urea concentrations in the serum compared with the control group. Cyclosporine therapy reduced the creatinine (Figure 2) and urea (Figure 1) concentration in a dose-dependent manner (Figure 1).

4.1.3. MDA and NO

Treatment with cyclosporine reduced the MDA (Figure 3) and NO (Figure 1) concentration in the rats poisoned with venom. In all experiments, cyclosporine at a dose of 30 mg was more effective than the doses of 10 and 20 mg.

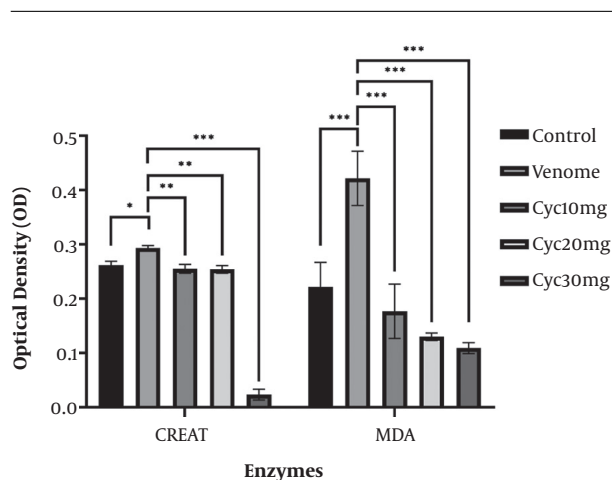


Figure 2. Serum concentrations of creatinine and malondialdehyde (MDA) in control and poisoned rats after therapy with cyclosporine at the doses of 10, 20, and 30 mg. Venom stimulated the secretion and production of both factors. Cyclosporine (30 and 20 mg) had significant effects (***) on these two factors. In the chart, venom effects were compared with control and cyclosporine effects were compared with venom to identify the effects of venom and cyclosporine. In the bar chart, C signals cyclosporine. The stars show the rate of significance (*P value < 0.05, **0.05 < P value < 0.01, ***P value < 0.01).

4.1.4. IL-2

The results of IL-2 cytokine showed that there was an insignificant decrease in the group receiving venom compared with the control group. Note that the cyclosporine at 10, 20, and 30 mg did not have any significant effects on the reduction of the IL-2, as the main cytokine, which stimulates T-cell proliferation (Figure 1).

4.2. Histopathology Study

The liver and kidney in control and experimental groups showed a normal appearance. Histopathological changes observed in the liver and kidney of the rats treated with olive oil represented mild bleeding and moderate degeneration. Histological examination of the liver and kidney sections 6 h after venom injection showed a medium level of edematous severity, bleeding, necrosis, and moderate degeneration (Figure 3). In particular, the liver and kidney sections showed inflammation through lymphocyte infiltration. Meanwhile, the venom caused marked histological degeneration in rats because cyclosporine at different doses could significantly reverse histological damages to the liver and kidney in a dose-dependent manner.

4.3. TUNEL Test

TUNEL test indicates that cyclosporine stimulates the apoptosis rate in the liver and kidney tissues in comparison with their normal counterparts (Figure 4). Expectedly, the results showed significant effects on apoptosis (Figure 5).

Table 1. Serum SGPT, SGOT, NO, UREA, IL-2, CREAT, and MDA Levels in the Control and Experimental Groups

	Control	Venom	Cyc (10 mg)	Cyc (20 mg)	Cyc (30 mg)
SGPT	126.2 ± 7	164.5 ± 10	151 ± 9	113.2 ± 11.4	96.42 ± 5.7
P value ^a		< 0.0001	< 0.0001	< 0.0001	< 0.0001
P value ^b			< 0.0001	< 0.0001	< 0.0001
SGOT	148 ± 10	190.37 ± 11	175.6 ± 7.34	158 ± 11.30	144.57 ± 9.24
P value ^a		< 0.0001	< 0.0001	0.01	0.8
P value ^b			< 0.0001	< 0.0001	< 0.0001
NO	17.4 ± 1.4	24.4 ± 1.17	20.04 ± 1.5	19.23 ± 1.86	20.19 ± 1.18
P value ^a		0.02	0.2	0.2	0.3
P value ^b			0.3	0.1	0.3
UREA	32.9 ± 0.7	38.83 ± 1.6	33.87 ± 1.45	33.6 ± 2.33	28.83 ± 1.32
P value ^a		0.07	0.4	0.4	0.04
P value ^b			0.2	0.1	0.00
IL-2	6.03 ± 0.12	5.1 ± 0.12	5.8 ± 0.18	5.9 ± 0.21	6.2 ± 0.19
P value ^a		0.9	0.9	0.9	0.9
P value ^b			0.9	0.9	0.9
CREAT	0.26 ± 0.007	0.29 ± 0.005	0.25 ± 0.008	0.25 ± 0.007	0.023 ± 0.01
P value ^a		0.090	0.97	0.96	< 0.0001
P value ^b			0.02	0.01	< 0.0001
MDA	0.22 ± 0.045	0.42 ± 0.050	0.17 ± 0.05	0.13 ± 0.007	0.10 ± 0.01
P value ^a		< 0.0001	0.003	< 0.0001	< 0.0001
P value			< 0.0001	< 0.0001	< 0.0001

^aCompared with the control group.

^bCompared with the venom group.

5. Discussion

To the best of our knowledge, this experiment is the first study to evaluate the possible efficacy of cyclosporine in the management of complications caused by *M. eupeus* venom. Also, we evaluated the effect of cyclosporine on oxidative stress, an inflammatory marker, liver function, and kidney performance. We also studied the effect of *M. eupeus* venom on pathological changes of the liver and kidney. The results of this study revealed that cyclosporine treatment improved complications caused by *M. eupeus* venom at least partially through improving liver function and kidney performance, decreasing inflammation, reducing oxidative stress, and increasing apoptosis.

The results of this study showed that SGOT and SGPT levels elevated after venom injection in comparison with cyclosporine administrations. The results of the SGOT and SGPT levels revealed that cyclosporine (30 mg) had the greatest effect on the reduction of liver enzyme concentrations following venom injection. Mirakabadi et al. tested the effect of *Hemiscorpius lepturus* scorpion venom

on liver enzymes and observed that SGOT and SGPT enzymes augmented after venom administration to the experimental animals (20). In another study, Zayerzadeh et al. evaluated the effect of *M. eupeus* scorpion venom on biochemical manifestations in rabbits. They observed that alanine transaminase (ALT, another name of the SGPT) and creatinine significantly elevated following venom injection. They concluded that the liver and kidney were damaged drastically (21). The results of MDA levels indicated that venom could increase MDA remarkably in comparison with other experimental groups. Cyclosporine at the doses of 20 and 30 mg was able to reduce venom inflammation. In a study, Salman and Hammad assessed the effect of scorpion crude venom on biochemical parameters and oxidative stress. They found that MDA, creatinine, and urea elevated significantly (22). Our results demonstrated that all doses of cyclosporine could reduce the venom effect. According to the results of the creatinine level, venom only caused a significant rise in creatinine level compared with the groups receiving cyclosporine at 30 and 20 mg. How-

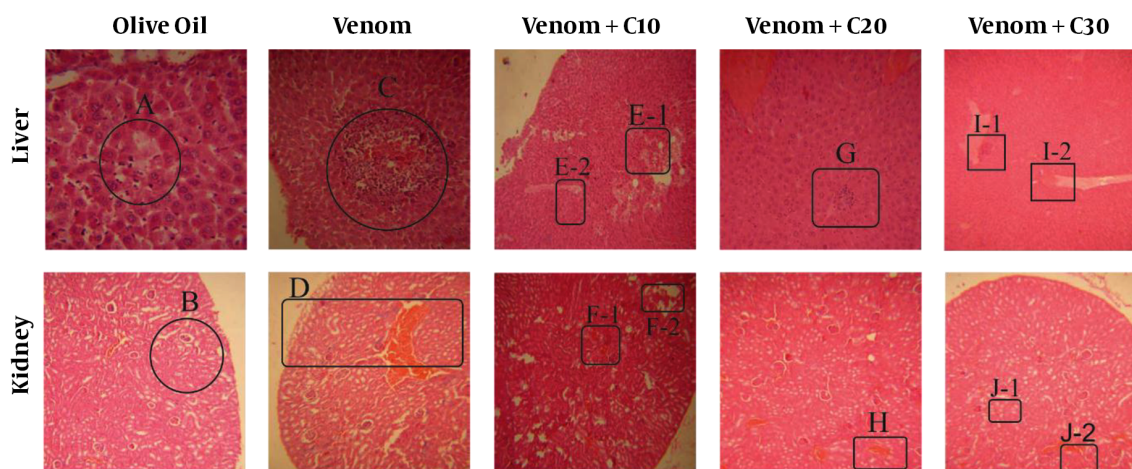


Figure 3. Histopathology explanation of the liver and kidney tissues in control, poisoned, and treated rats, stained with H & E; (A) the degeneration of the liver tissue in the control rats, magnification $\times 40$; (B) Degeneration of the renal tubular with hyperemia, magnification $\times 40$; (C) Infiltration and mild degeneration of the liver parenchyma, magnification $\times 20$; (D) Degeneration of renal tubular with hyperemia, magnification $\times 40$; (E1-2) Necrosis site and mild edema of the liver tissue, magnification $\times 40$; (F1-2) Mild edema, hyperemia in the kidney parenchyma, magnification $\times 100$; (G) Mild degeneration of the liver parenchyma, magnification $\times 200$; (H) Hyperemia and bleeding site, magnification $\times 100$; (I1-2) Hyperemia and bleeding site with mild edema and lymphocytic site in the liver parenchyma, magnification $\times 100$; (J1-2) Hyperemia and bleeding site with a mild edema site in the kidney parenchyma, magnification $\times 100$.

ever, cyclosporine at 30 mg only could reduce the venom effect on the urea level. The urea level after the injection of venom elevated after the administration of cyclosporine (30 mg). Mirakabadi et al. studied the *Odonthobuthus doricae* venom effect on biochemical manifestations in rabbits. They found that the venom significantly increased urea, SGPT, and SGOT levels (23). Also, in another study, El Hidan et al. examined the physiological injuries in mice experimentally envenomed with *Androctonus liouvillei* scorpion venom. They discovered that this venom caused a remarkable elevation in creatinine, as well as SGPT and SGOT enzymes (24).

Venom could elevate NO levels after cyclosporine (20 and 30 mg) administration. Specifically, 20 and 30 mg doses of cyclosporine were able to significantly reduce NO level in the venom-received groups. Petricevich et al. evaluated serum levels of IL-2 cytokine and NO when the experimental mice group received *Titus serrulatus* scorpion venom (25). They found an elevation in NO and IL-1 α , IL-1 β , IL-6, TNF- α , and IFN- γ cytokines after the venom injection. The venom failed to increase IL-2 level compared with the control groups (25). Interestingly, cyclosporine at the doses of 10, 20, and 30 mg did not have significant effects on IL-2 concentration. Kahan et al. observed that cyclosporine coupled with rapamycin decreased IL-2 cytokine levels (26). In many studies, it has been observed that cyclosporine reduces the gene expression of IL-2 and blocks its proliferation (27). However, in this study, we did not find any significant effect on IL-2 concentration.

The results of liver and kidney pathological examination with venom in combination with the three doses of cyclosporine indicated a moderate degeneration, as well as mild bleeding. In this regard, Dehghani et al. studied *H. lepturus* as a common scorpion whose venom effect was evaluated in mice. The hematological parameters, as well as the histological changes in organs, such as kidney, heart, spleen, etc., were examined. They concluded that the venom of *H. lepturus* had a negative effect on all organs (28). Also, Zayerzadeh et al. examined a lethal dose of *M. eupeus* of scorpion venom and evaluated the pathological findings of the lungs and heart. All the rabbits died upon venom administration. Although *M. eupeus* have lethal effects on lung and heart, it seems that the severity of lung tissue damage is independent of the heart tissue damage and the main cause of mortality was severe pulmonary damage (21).

The pathophysiology of the scorpion sting and its causal mechanisms is complex and has not yet fully understood. Hemodynamic changes play a pivotal role in its pathogenesis. The effect of venom on ion channels has been reported to release inflammatory cytokines and vasoactive hormones, resulting in hemodynamic change (29). Various studies have demonstrated that scorpion stings can damage various organs by activating the secretion pathways of cytokines (IL-6, IL-1, TNF- α , leukotrienes, and prostaglandins) (30, 31). In addition, increased levels of cytokines increase oxidative stress and the release of free radicals. Studies have shown that free radicals pro-

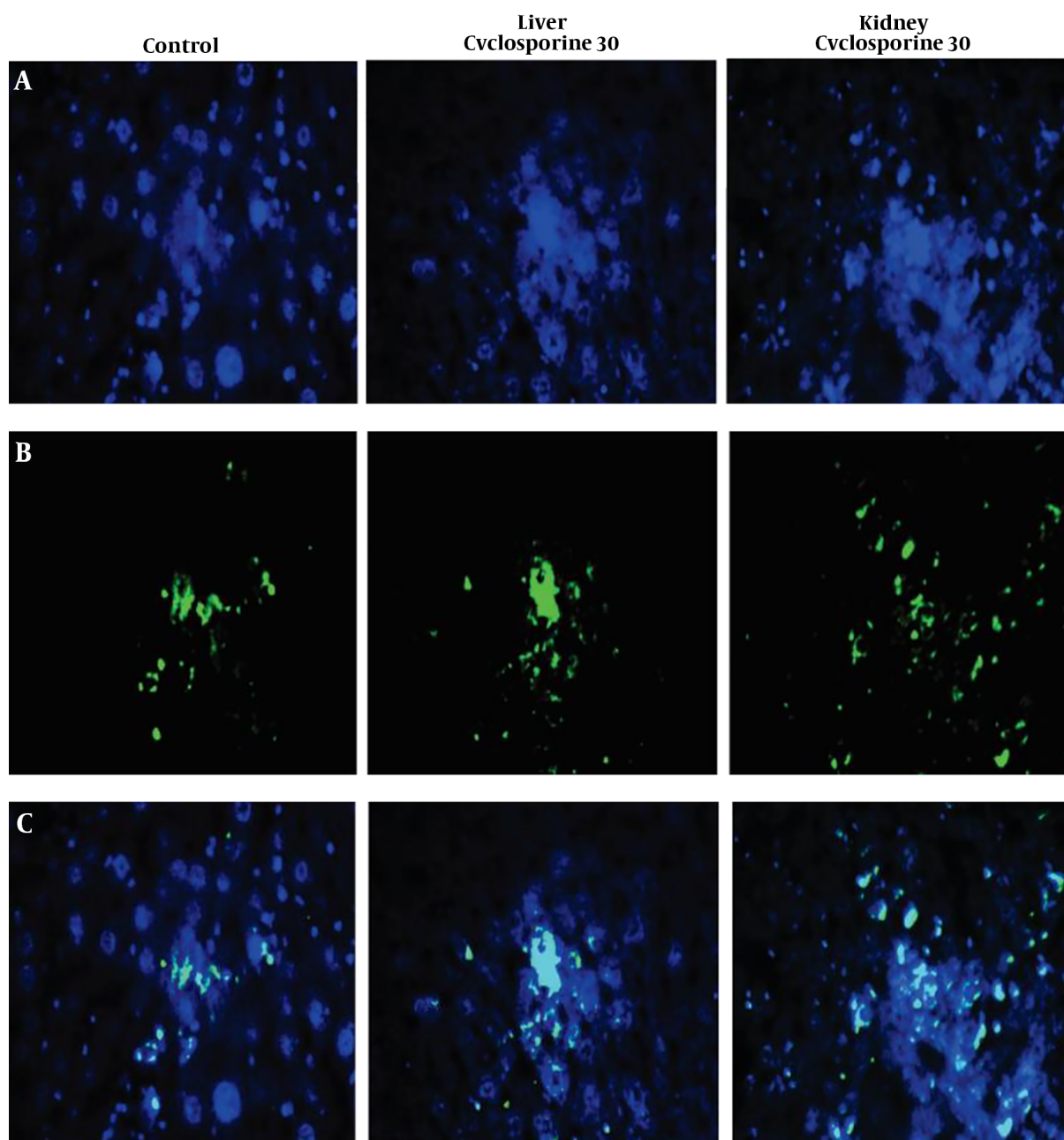


Figure 4. TUNEL microscopic image of the control and treated tissues; (A) Normal Cells stained with propidium iodide, (B) The apoptotic cells stained with TUNEL, (C) Combination of both cells to differentiate apoptotic cells.

duction is associated with the severity of scorpion stings (9). In addition, increased levels of free radicals and NO are connected to increased lipid peroxidation, where the oxygen/nitrogen radicals react with the membrane lipids and alter their function (19). MDA is considered as one of the main products of lipid peroxidation that can worsen

the inflammatory response (32). The increase in oxygen/nitrogen radicals after the scorpion sting also appears to affect the total anti-oxidant capacity, thereby inhibiting catalase activity and reducing glutathione (GSH) (19). Consequently, oxidative stress damages tissues by denaturing proteins, lipid membrane peroxidation, and damage

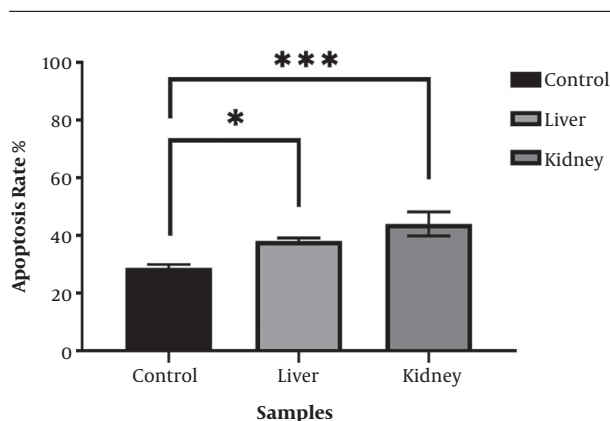


Figure 5. Apoptotic effects of cyclosporine (30 mg) on rats' liver and kidney tissues; cyclosporine had significant effects on cells and stimulated apoptosis in all samples significantly. The stars show the rate of significance (*P value < 0.05, **0.05 < P value < 0.01, ***P value < 0.01).

to DNA (33).

Cyclosporine stimulated the apoptosis rate in the liver and kidney samples. Many studies have shown that cyclosporine at high concentrations has significant effects on apoptosis and stimulates apoptosis via up-regulation of pro-apoptotic genes, such as P-53, Bax, and Bad. On the other hand, it down-regulates the expression of anti-apoptotic genes, such as Bcl-2 (34). It has also been found that cyclosporine stimulates the Fas-L and caspase-3 activity (34, 35). Several other studies have also observed that cyclosporine inhibits the DNA synthesis of tubular epithelial cells and induces their apoptosis (36, 37).

Although cyclosporine was not able to suppress the cytotoxic effects of venom perfectly, all the biochemical molecules examined in this study reduced following cyclosporine administration, and inflammatory responses declined significantly in the body. In this regard, the pathological results of the present study demonstrated that the venom in combination with cyclosporine at the dose of 30 mg was more effective in the development of complications compared with the experimental groups treated with olive oil. Further investigations are required to evaluate complementary agents in conjunction with cyclosporine in order to suppress the venom effect completely.

5.1. Conclusion

The results revealed that the utilization of cyclosporine at a dose of 30 mg is considered as an optimum dose for the recovery of the liver and kidney function. It also exerts pro-apoptosis properties and counteracts the *M. eupeus* venom with high efficiency. Therefore, the results of this study could increase our knowledge about the effectiveness of

anti-inflammatory agents in the treatment and reduction of the complications caused by *M. eupeus* venom.

Acknowledgments

This study was extracted from a Ph.D. thesis by Sara Zangiabadi.

Footnotes

Authors' Contribution: Study concept and design: Sara Zangiabadi, Shahrokh Navidpour and Gholamhassan Vaezi; analysis and interpretation of data: Sara Zangiabadi and Hossein Zolfagharian.; drafting of the manuscript: Gholamhassan Vaezi; critical revision of the manuscript for important intellectual content: Sara Zangiabadi and Gholamhassan Vaezi; statistical analysis: Shahrokh Navidpour.

Conflict of Interests: The author declares no potential conflicts of interest with respect to the research, authorship, and/or publication of this article.

Ethical Approval: This study was approved by the Research Ethics Committee of the Islamic Azad University, Damghan Branch, Damghan, Iran (RVSRI.REC.980003).

Funding/Support: The present study was funded by the vice-chancellor for research of Islamic Azad University, Damghan Branch, Damghan, Iran.

References

1. Prendini L, Wheeler WC. Scorpion higher phylogeny and classification, taxonomic anarchy, and standards for peer review in online publishing. *Cladistics*. 2005;**21**(5):446-94.
2. Petricevich VL. Scorpion venom and the inflammatory response. *Mediators of inflammation*. 2010;**2010**.
3. Zayerzadeh E, Koohi MK, Zare Mirakabadi A, Purkabireh M, Kassaaian SE, Rabbani SH, et al. Cardiopulmonary complications induced by Iranian *Mesobuthus eupeus* scorpion venom in anesthetized rabbits. *Journal of Venomous Animals and Toxins including Tropical Diseases*. 2010;**16**(1):46-59.
4. Laraba-Djebari F, Adi-Bessalem S, Hammoudi-Triki D. Scorpion venoms: pathogenesis and biotherapies. *Gopalakrishnakone P, Possani LD, Schwartz EF, de la Vega RC R, editors. Scorpion Venoms. Dordrecht: Springer Netherlands*. 2015:63-85.
5. Adi-Bessalem S, Hammoudi-Triki D, Laraba-Djebari F. Scorpion venom interactions with the immune system. *Scorpion Venoms. Dordrecht: Springer Netherlands*. 2015:87-107.
6. Khemili D, Laraba-Djebari F, Hammoudi-Triki D. Involvement of Toll-like Receptor 4 in Neutrophil-Mediated Inflammation, Oxidative Stress and Tissue Damage Induced by Scorpion Venom. *Inflammation*. 2020;**43**(1):155-67.
7. Chair-Yousfi I, Laraba-Djebari F, Hammoudi-Triki D. *Androctonus australis hector* venom contributes to the interaction between neuropeptides and mast cells in pulmonary hyperresponsiveness. *International immunopharmacology*. 2015;**25**(1):19-29.

8. Saidani C, Hammoudi-Triki D, Laraba-Djebari F, Taub M. In vitro studies with renal proximal tubule cells show direct cytotoxicity of *Androctonus australis hector* scorpion venom triggered by oxidative stress, caspase activation and apoptosis. *Toxicon*. 2016;**120**:29–37.
9. Saidani C, Béchohra L, Laraba-Djebari F, Hammoudi-Triki D. Kidney inflammation and tissue injury induced by scorpion venom: comparison with a nephrotoxic model. *Toxin Reviews*. 2019;**38**(3):240–7.
10. Chippaux J-P, Goyffon M. Epidemiology of scorpionism: a global appraisal. *Acta tropica*. 2008;**107**(2):71–9.
11. Angsanakul J, Sitprija V. Scorpion venoms, kidney and potassium. *Toxicon*. 2013;**73**:81–7.
12. Yadav S, Pawar G, Kulkarni P, Ferris C, Amiji M. CNS Delivery and Anti-Inflammatory Effects of Intranasally Administered Cyclosporine-A in Cationic Nanoformulations. *Journal of Pharmacology and Experimental Therapeutics*. 2019;**370**(3):843–54.
13. Liddicoat AM, Lavelle EC. Modulation of innate immunity by cyclosporine A. *Biochemical pharmacology*. 2019.
14. Pino-Lagos K, Michea P, Sauma D, Alba A, Morales J, Bono MR, et al. Cyclosporin A-treated dendritic cells may affect the outcome of organ transplantation by decreasing CD4+ CD25+ regulatory T cell proliferation. *Biological research*. 2010;**43**(3):333–7.
15. Singh K, Argáez C. Cyclosporine for Moderate to Severe Plaque Psoriasis in Adults: A Review of Clinical Effectiveness and Safety. *Canadian Agency for Drugs and Technologies in Health*. 2018.
16. Archer TM, Stokes JV, Kummari E, Fellman C, Thomason J, Haraschak J, et al. In vivo effects of aspirin and cyclosporine on regulatory T cells and T-cell cytokine production in healthy dogs. *Veterinary immunology and immunopathology*. 2018;**197**:63–8.
17. Fellman CL, Archer TM, Stokes JV, Wills RW, Lunsford KV, Mackin AJ. Effects of oral cyclosporine on canine T-cell expression of IL-2 and IFN-gamma across a 12-h dosing interval. *Journal of veterinary pharmacology and therapeutics*. 2016;**39**(3):237–44.
18. Tveden-Nyborg P, Bergmann TK, Lykkesfeldt J. Basic & clinical pharmacology & toxicology policy for experimental and clinical studies. *Basic & clinical pharmacology & toxicology*. 2018;**123**(3):233–5.
19. Lamraoui A, Adi-Bessalem S, Laraba-Djebari F. Immunopathologic effects of scorpion venom on hepato-renal tissues: Involvement of lipid derived inflammatory mediators. *Experimental and molecular pathology*. 2015;**99**(2):286–96.
20. Mirakabadi A, Zolfagharian H, Hedayat A, Jalali A. Clinical and biochemical manifestation produced by scorpion (*Hemiscorpius lepturus*) venom in experimental animals. *Journal of Venomous Animals and Toxins including Tropical Diseases*. 2007;**13**(4):758–65.
21. Zayerzadeh E, Zare MA, Koohi MK. Biochemical and histopathological study of *Mesobuthus eupeus* scorpion venom in the experimental rabbits. *Archives of Razi Institute*. 2011.
22. Salman MM, Hammad S. Oxidative stress and some biochemical alterations due to scorpion (*Leiurus quinquestriatus*) crude venom in rats. *Biomedicine & Pharmacotherapy*. 2017;**91**:1017–21.
23. Mirakabadi AZ, Jalali A, Jahromi AE, Vatanpur H, Akbary A. Biochemical changes and manifestations of envenomation produced by *Odonthobuthus doriae* venom in rabbits. *Journal of venomous animals and toxins including tropical diseases*. 2006;**12**(1):67–77.
24. El Hidan MA, Touloun O, El Hiba O, Boumezzough A. Pathophysiological and neurobehavioral injuries in mice experimentally envenomed with *Androctonus liouvillei* (Pallary, 1928) scorpion venom. *Experimental and Toxicologic Pathology*. 2016;**68**(2-3):133–41.
25. Petricevich VL, Peña CF. The dynamics of cytokine and nitric oxide secretion in mice injected with *Tityus serrulatus* scorpion venom. *Mediators of Inflammation*. 2002;**11**(3):173–80.
26. Kahan BD, Gibbons SHEENA, Tejpal N, Stepkowski SM, Chou T. Synergistic interactions of cyclosporine and rapamycin to inhibit immune performances of normal human peripheral blood lymphocytes in vitro. *Transplantation*. 1991;**51**(1):232–9.
27. Kang HG, Zhang D, Degauque N, Mariat C, Alexopoulos S, Zheng XX. Effects of cyclosporine on transplant tolerance: the role of IL-2. *American journal of transplantation*. 2007;**7**(8):1907–16.
28. Dehghani R, Fathi B. Scorpion sting in Iran: a review. *Toxicon*. 2012;**60**(5):919–33.
29. Sitprija V, Sitprija S. Renal effects and injury induced by animal toxins. *Toxicon*. 2012;**60**(5):943–53.
30. Zoccal KF, Paula-Silva FWG, da Silva Bitencourt C, Sorgi CA, Bordon KDCF, Arantes EC, et al. PPAR- γ activation by *Tityus serrulatus* venom regulates lipid body formation and lipid mediator production. *Toxicology*. 2015;**93**:90–7.
31. Costal-Oliveira F, Guerra-Duarte C, Castro KLP, Tintaya B, Bonilla C, Silva W, et al. Serological, biochemical and enzymatic alterations in rodents after experimental envenomation with *Hadruroides lunatus* scorpion venom. *Toxicon*. 2015;**103**:129–34.
32. Niedernhofer LJ, Daniels JS, Rouzer CA, Greene RE, Marnett LJ. Malondialdehyde, a product of lipid peroxidation, is mutagenic in human cells. *Journal of Biological Chemistry*. 2003;**278**(33):31426–33.
33. Dousset E, Carrega L, Steinberg JG, Clot-Faybesse O, Jouirou B, Sauze N, et al. Evidence that free radical generation occurs during scorpion envenomation. *Comparative biochemistry and physiology part c: toxicology & pharmacology*. 2005;**140**(2):221–6.
34. Shihab FS, Andoh TF, Tanner AM, Yi H, Bennett WM. Expression of apoptosis regulatory genes in chronic cyclosporine nephrotoxicity favors apoptosis. *Kidney international*. 1999;**56**(6):2147–59.
35. Rao SR, Sundararajan S, Subbarayan R, Girija DM. Cyclosporine-A induces endoplasmic reticulum stress and influences pro-apoptotic factors in human gingival fibroblasts. *Molecular and cellular biochemistry*. 2017;**429**(1-2):179–85.
36. Wu Q, Wang X, Nepovimova E, Wang Y, Yang H, Kuca K. Mechanism of cyclosporine A nephrotoxicity: Oxidative stress, autophagy, and signaling. *Food and chemical toxicology*. 2018;**118**:889–907.
37. Kim SI, Song HY, Hwang JH, Chong DL, Lee HY, Han DS, et al. Cyclosporine nephrotoxicity: the mechanisms of cell injury by cyclosporine A in renal proximal tubular cells. *Transplantation proceedings*. 2000. p.1621–2.