



Apatinib for Treatment of Locally Advanced Rectal Angiosarcoma: A Case Report

Engeng Chen¹, Zhiyao Xu², Gaoyang Cao¹ and Li Chen^{1,*}

¹Department of Colorectal Surgery, School of Medicine, Sir Run Run Shaw Hospital, Zhejiang University, Hangzhou, China

²Department of Pathology, School of Medicine, Sir Run Run Shaw Hospital, Zhejiang University, Hangzhou, China

*Corresponding author: Department of Colorectal Surgery, School of Medicine, Sir Run Run Shaw Hospital, Zhejiang University, Hangzhou, China. Tel: +86-57186006355, Email: 3415021@zju.edu.cn

Received 2020 February 23; Revised 2020 May 10; Accepted 2020 June 14.

Abstract

Introduction: Primary colorectal angiosarcoma is a highly rare malignant tumor. There is no standard treatment method for this disease. No treatment of rectal angiosarcoma with apatinib has been reported so far.

Case Presentation: In the current study, an 87-year-old male presented with the symptoms of frequent defecation for more than one month in Hangzhou, China, in 2018. The patient was initially diagnosed with a rectal stromal tumor. The patient underwent ultrasound-guided transrectal mass puncture in the next treatment. However, immunohistochemical examinations confirmed the initial diagnosis of rectal angiosarcoma. The patient had advanced age and rectal angiosarcoma with metastasis; he had no surgical indications, and we tried to use apatinib 250 mg/d treatment to control the progression of the lesion. Then, he received apatinib, a novel tyrosine kinase inhibitor of vascular endothelial growth factor receptor-2 (VEGFR-2). The patient has been stable to apatinib with a dose of 250 mg daily by now.

Conclusions: Apatinib may play an important role in the treatment of unresectable angiosarcoma.

Keywords: Case Report, Apatinib, Rectal Angiosarcoma

1. Introduction

Angiosarcoma is a special malignant tumor derived from vascular endothelial cells (1, 2). Approximately 50% of angiosarcoma cases occur in the head and neck (3). These tumors have high rates of local recurrence and metastasis because of their intrinsic biologic properties. They are often misdiagnosed, leading to a poor prognosis and a high mortality rate. Malignant vascular tumors are clinically aggressive, difficult to treat, and have a reported five-year survival rate of around 20 - 35% (2). More than 50% of patients develop metastatic disease, with the lung being the primary organ involved.

Surgery is the first choice for the treatment of gastrointestinal angiosarcoma, but complete surgical resection is generally impossible because of its invasive and multifocal nature. Chemotherapy and/or radiotherapy can be an important part of the treatment plan and can be performed before or after surgery. Doxorubicin is the option for chemotherapy of angiosarcoma, but some centers use a combination of Mesna, doxorubicin, and ifosfamide (MAI). Liposome doxorubicin has also been used. Paclitaxel and docetaxel have shown to be effective against an-

giosarcoma of the head, neck, and scalp. However, gastrointestinal angiosarcoma is not sensitive to radiotherapy and chemotherapy, so the prognosis is very poor. Kimberley et al. found that complete surgical resection is the only factor related to the prognosis of gastrointestinal angiosarcoma.

Primary colorectal angiosarcoma is a highly rare malignant tumor. Fewer than 50 cases of colorectal angiosarcoma have been previously reported (4, 5). Because of the scarcity of rectal angiosarcoma, the five-year survival rate may not be clearly calculated. Due to the limited effect of conventional cytotoxic chemotherapy, soft tissue sarcoma, including angiosarcoma, is still a hot field of drug research and development (6). As a small molecule inhibitor of vascular endothelial growth factor receptor 2 (VEGFR-2) tyrosine kinase, apatinib can inhibit tumor angiogenesis and is suitable for patients with advanced gastric adenocarcinoma or gastroesophageal junction adenocarcinoma who have progressed or relapsed after at least two kinds of systematic chemotherapy. However, a case of rectal angiosarcoma treated with apatinib is yet to be reported. Because of rare cases of rectal angiosarcoma, poor prognosis, and the

lack of effective treatment methods, the treatment experience is not perfect at present. Therefore, we report a case of rectal angiosarcoma treated with apatinib at our center to provide a reference for improving the treatment of this kind of rare disease.

2. Case Presentation

An 87-year-old Chinese male was admitted to the Sir Run Run Shaw Hospital, School of Medicine, Zhejiang University (Hangzhou, China), with a change in defecation habits without hematochezia for more than one month on June 30, 2018. The detailed characteristics of the patient are listed in Table 1. The patient was suffering from mild hypertension and bronchitis for many years. Colonoscopy showed a rectal mass 5 - 8 cm away from the anal margin, and the pathology revealed hyperplasia and dilatation of the rectal mucosal gland in Hangzhou First People's Hospital. The patient came to our hospital for further diagnosis and treatment. A soft extramural mass of the rectum was identified upon a digital rectal examination. Transrectal sonography detected a rectal heterogeneous hypoechoic mass located in the anterior wall, 5 - 8 cm away from the anal margin. The circumference was 11.39 cm, the area was 2.46 cm², and the height was 0.71 cm, with abundant blood flow signals. Magnetic resonance imaging (MRI) and computed tomography (CT) revealed a mass located in the right posterior wall of the rectum, mainly growing out of the lumen and invading the right seminal vesicle gland, the right posterior wall of the bladder, and the right pelvic wall. The size of the mass was about 4.62 cm, with multiple metastatic pelvic lymph nodes. The mass was considered to be a malignant stromal tumor (Figure 1A). The indices of tumor markers, including cancer antigen (CA)-125, CA19-9, and carcinoembryonic antigen, were within normal limits.

Table 1. Characteristics of the Patient in this Study

	Characteristics
Age	87
Gender	Male
Basic disease	Mild hypertension and bronchitis
Pathology diagnosis	Rectal angiosarcoma
Treatment	Apatinib 250 mg/d
Adverse reactions	Mild skin adverse reactions

The patient underwent a diagnostic ultrasound-guided transrectal mass puncture. Immunohistochemically, tumor cells were positive for cluster of differentiation (CD)34, CD31, and ERG protein, but negative for CD117,

pan-cytokeratin, S100 protein, and delay of germination 1 (DOG-1) (Figure 2). Immunohistochemistry indicated a diagnosis of malignant spindle cell tumors. Finally, the clinical impression and results of the immunohistochemical examination established a final diagnosis of angiosarcoma. Considering the multiple pelvic lymph node metastases associated with patient's tumors, it was impossible to resect the tumors radically. In addition, the patient was too old and weak to tolerate intravenous chemotherapy. Considering the patient's age and basic condition, after multi-disciplinary consultation, we decided that the patient should be treated with oral apatinib. Thus, he received apatinib, a novel tyrosine kinase inhibitor of VEGFR-2. The patient was in follow-ups every three months. After nine months of treatment, the size of the tumor was 4.84 cm, which was similar to before (Figure 1B), and the overall lesion evaluation showed stable disease (SD) according to the response evaluation criteria in solid tumors (version 1.1). The patient only had mild skin adverse reactions.

3. Discussion

Angiosarcoma is one of the rarest soft tissue tumors, comprising less than 1% of all soft tissue sarcomas. It generally occurs on the face and scalp, but rarely in the gastrointestinal tract (7). Primary colorectal angiosarcoma is especially rare, accounting for less than 0.001% of all colorectal cancers (1). The pathogenesis of angiosarcoma is still unclear.

Colorectal angiosarcoma tumors are elevated in appearance under colonoscopy and have irregular ulcerations on the surface and are prone to bleeding. The tumors are mostly covered by normal mucosa, suggesting that they are not epithelial malignant tumors (1, 8). Clinical manifestation is similar to other colorectal cancers, usually presenting with anemia, abdominal pain, abdominal mass, gastrointestinal tract bleeding, and bowel obstruction (1, 9). In our case, the patient was first diagnosed due to a change in defecation habits. The MRI and CT examinations have great values in the diagnosis of colorectal angiosarcoma. But, PET-CT may be useful to detect metastases and recurrence.

Histologic diagnosis can be difficult, with variable features. In poorly differentiated areas, malignant endothelial cells can form continuous sheets, usually with an epithelioid morphology and areas of hemorrhage and necrosis, which can make it difficult to differentiate them from anaplastic carcinoma (10, 11). Although immunohistochemical examinations are helpful, there is no consistently reliable test for angiosarcoma. It is positive for some or all of the endothelial markers like CD31, CD34, and VEGF

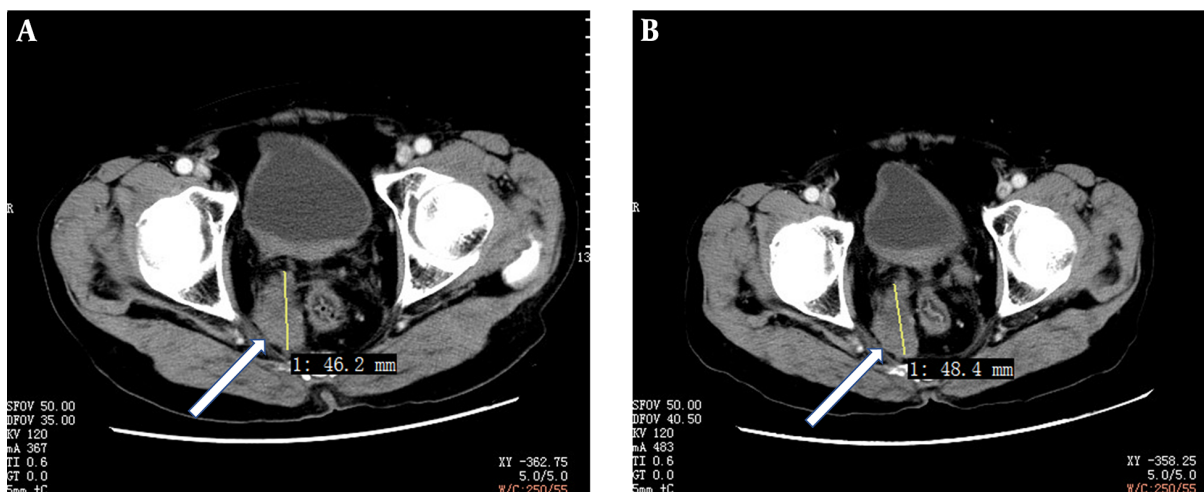


Figure 1. The CT images of rectal angiosarcoma. A, before treatment; B, nine months after treatment with apatinib; red lines indicate the size and borders of the mass.

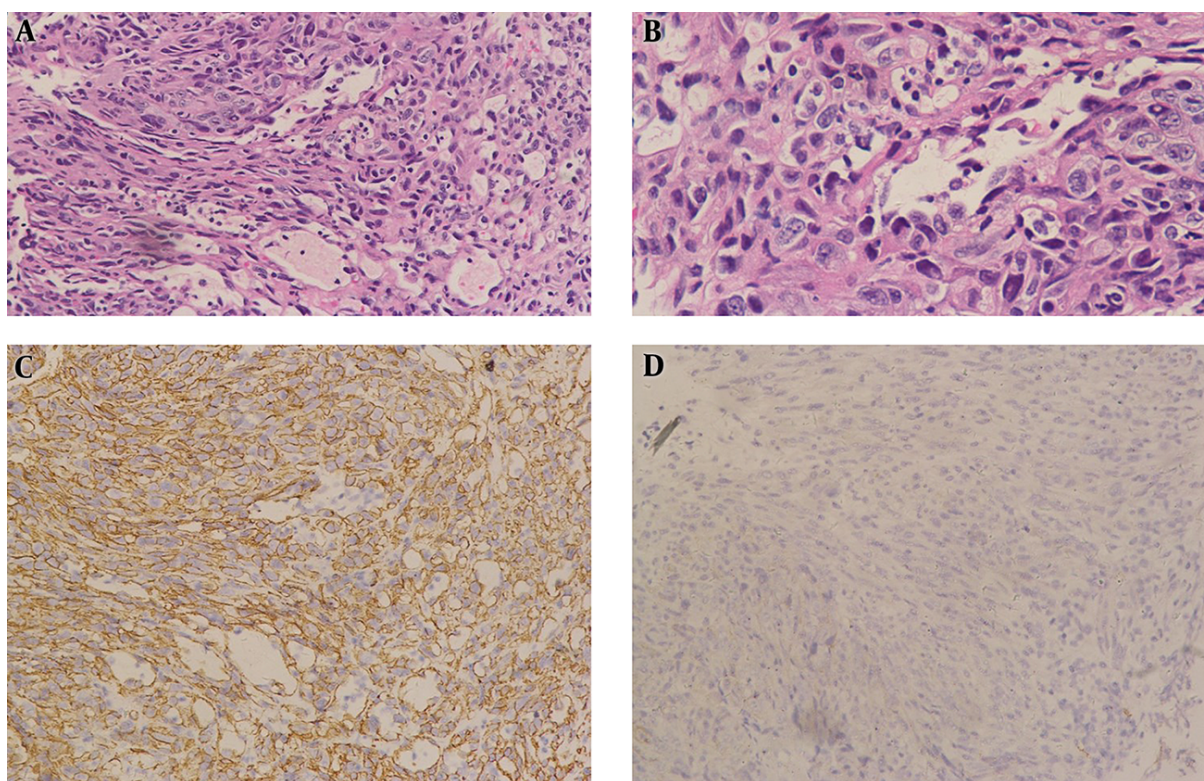


Figure 2. Histological features and immunohistochemical results of rectal angiosarcoma. A, The morphological examination (hematoxylin and eosin staining; magnification, 200×); B, the morphological examination (hematoxylin and eosin staining; magnification, 400×); C, the tumor cells were demonstrated marked positivity for CD34 (immunostaining; magnification, 200×); but D, negative for CD117 (immunostaining; magnification, 200×). CD, cluster of differentiation.

(10, 12). However, tumor dedifferentiation can lead to a loss of these markers. The differential diagnosis of angiosarcomas mainly depends on immunohistochemistry. They are

as follows. Leiomyosarcoma: Microscopically, the tumor cells are large, the atypia is obvious, and myogenic markers such as SMA and actin are positive. Gastrointestinal stro-

mal tumors: Cells are spindle or epithelioid, and the diagnostic feature is CD117-positive, with high sensitivity and specificity. Epithelioid sarcoma: Sometimes, it appears as pseudo-hemangioma, but CD34 and CD31 are negative (1, 8). In our case, tumor cells were positive for CD34, CD31, and ERG protein, but negative for CD117, pan-cytokeratin, S100 protein, and DOG-1.

Angiosarcoma is highly invasive and can rapidly progress to metastasis. The prognosis of colorectal angiosarcoma tumors is poor. Compared to tumors growing in the head, neck, and extremities, colorectal angiosarcoma, with only rare cases have long-term survival. The common sites of metastases are the bone, lung, and liver (2, 13). Brown et al. (1), in a review of colorectal angiosarcoma, found that age > 60 years and tumor size \geq 5 cm had a poor prognosis. Previous studies have shown that prognostic factors for angiosarcoma include the mitotic rate and tumor site, which is similar to gastrointestinal stromal tumors (GISTs) (14).

Because of the rarity of colorectal angiosarcoma, most treatment decisions are currently based on the treatment of angiosarcoma in other parts of the body. At present, appropriate surgery is still the most effective treatment. For stage I angiosarcomas, the National Comprehensive Cancer Network (NCCN) recommends surgery to obtain adequate oncologic margins. For stage II and stage IIIA and IIIB disease that can be resected with acceptable functional outcomes, the NCCN also recommends preoperative radiation therapy (15). Angiosarcomas are generally not sensitive to radiotherapy and chemotherapy. There are several studies on the use of adriamycin, epirubicin, paclitaxel, docetaxel, and other drugs to treat angiosarcoma (13, 16). Multiple randomized studies using adriamycin-based chemotherapy failed to show a survival benefit for neoadjuvant chemotherapy. However, a meta-analysis suggested improved local control and disease-free survival with chemotherapy, but without any survival advantage (17). Because of the lack of large-scale clinical trials, long-term benefits are not clear.

Tumor growth is inseparable from the abundant blood supply. At the same time, tumor growth promotes angiogenesis. Therefore, anti-angiogenesis is of great significance in cancer treatment. Ravi et al. (18) reported an exceptional response to treatment with pazopanib in a patient with angiosarcoma that harbored the amplification of VEGFR and had not responded to sorafenib. These authors suggested that a subset of patients with angiosarcoma with genomic alterations in vascular signaling genes may respond well to pazopanib. Apatinib is a small molecule tyrosine kinase inhibitor of VEGFR-2, which can bind to it and specifically inhibit its activation (19, 20). By inhibiting tumor angiogenesis and exerting anti-tumor ef-

fects, it has been applied in various solid tumors and has achieved good results. Apatinib is currently mainly used in the treatment of advanced gastric cancer, non-small cell lung cancer, and advanced liver cancer (20-22). Angiosarcoma has a high expression of VEGFR, which is considered to be an effective target for apatinib. A retrospective analysis of apatinib treatment in patients with advanced bone and soft tissue sarcomas who failed chemotherapy showed significant disease control and survival benefits (23). A retrospective analysis of 31 patients with apatinib use for bone and soft tissue sarcoma showed an ORR of 33.3%, clinical benefit rate (CBR) of up to 75.0%, and PFS of 4.25 months, while OS was 9.43 months and most of the adverse reactions were grade I or II (24). All these studies have shown that apatinib has high efficacy and safety in the treatment of soft tissue sarcoma.

In this case, the patient had advanced age and rectal angiosarcoma with metastasis; he had no surgical indications, and we tried to use apatinib 250 mg/d treatment to control the progression of the lesion. In our case, the choice of apatinib was mainly due to the following reasons. First, pharmacodynamic studies show that apatinib can block the signal transduction of VEGF and its receptor by inhibiting VEGFR-2 tyrosine kinase activity. Simply put, tumors are treated by inhibiting tumor angiogenesis. Concerning the mechanism of action of apatinib on tumor cells, it is speculated that it is effective for angiosarcoma. Second, there is no standard program for the treatment of primary rectal angiosarcoma. There are many reports to confirm the feasibility of apatinib in the treatment of advanced sarcoma, and it has a good clinical application prospect. Lastly, as a highly effective and low-toxic anti-tumor angiogenesis drug, apatinib is convenient for oral administration and is easily accepted by patients. In our case, the patient was on treatment with apatinib with a dose of 250 mg daily for nine months. The overall lesion evaluation was SD, and the patient only has mild skin adverse reactions. Compared to the rapid progression of angiosarcoma in the past, apatinib treatment was effective in this patient.

Any research has its advantages and disadvantages, and our research is no exception. In terms of disadvantages, first of all, there was only one case in our study, and there was insufficient evidence to promote this treatment. Second, the patient was an 87-year-old man whose survival time was affected by the natural lifespan, and he did not have the conditions for long-term follow-up to some extent. In terms of advantages, first of all, the treatment plan of this study was the most suitable individual treatment plan for patients after a multi-disciplinary discussion in the whole hospital and full informed consent. Second, this case reports the rare rectal angiosarcoma using apatinib

as a treatment regimen, which can provide some reference for clinical work.

The present study aimed to increase awareness among clinicians. Colorectal angiosarcoma is a highly rare malignant tumor. Apatinib may play an important role in the treatment of unresectable angiosarcoma. Long-term efficacy needs further follow-ups and large-scale research in the future.

Footnotes

Authors' Contribution: LC and EGC designed the study, analyzed, and interpreted the data, and wrote the manuscript. ZYX and GYC provided patients' samples and clinical data. LC conceptualized and designed the study, and revised the manuscript. All authors have vouched for the data analysis, approved the final version, and agreed to publish the manuscript.

Conflict of Interests: The authors declare that they have no competing interests.

Ethical Approval: This study was approved by the Ethics Committee of Sir Run Run Shaw Hospital, Zhejiang University.

Funding/Support: Nothing to declare.

Informed Consent: The consent for publication of the manuscript and the related images and individual data were obtained from the patient.

References

- Brown CJ, Falck VG, MacLean A. Angiosarcoma of the colon and rectum: report of a case and review of the literature. *Dis Colon Rectum*. 2004;47(12):2202-7. doi: 10.1007/s10350-004-0698-5. [PubMed: 15657674].
- Buehler D, Rice SR, Moody JS, Rush P, Hafez GR, Attia S, et al. Angiosarcoma outcomes and prognostic factors: a 25-year single institution experience. *Am J Clin Oncol*. 2014;37(5):473-9. doi: 10.1097/COC.0b013e31827e4e7b. [PubMed: 23428947]. [PubMed Central: PMC3664266].
- Yang L, Liu L, Han B, Han W, Zhao M. Apatinib treatment for KIT- and KDR-amplified angiosarcoma: a case report. *BMC Cancer*. 2018;18(1):618. doi: 10.1186/s12885-018-4523-2. [PubMed: 29855279]. [PubMed Central: PMC5984462].
- Lo YM, Gillett MB, Vina M, Collin J, Fleming KA. Hemangiosarcoma of the rectum after chronic anorectal ulceration. *J Clin Gastroenterol*. 1989;11(1):77-81. doi: 10.1097/00004836-198902000-00020. [PubMed: 2921494].
- Hinterseher I, Pistorius S, Zietz C, Bergert H. Epithelioid heman-giosarcoma of the rectum. *Int J Colorectal Dis*. 2005;20(4):385-7. doi: 10.1007/s00384-004-0673-6. [PubMed: 15959792].
- Maki RG, D'Adamo DR, Keohan ML, Saulle M, Schuetze SM, Undevia SD, et al. Phase II study of sorafenib in patients with metastatic or recurrent sarcomas. *J Clin Oncol*. 2009;27(19):3133-40. doi: 10.1200/jco.2008.20.4495. [PubMed: 19451436]. [PubMed Central: PMC2716936].
- Aljabab AS, Nason RW, Kazi R, Pathak KA. Head and neck soft tissue sarcoma. *Indian journal of surgical oncology*. 2011;2(4):286-90. doi: 10.1007/s13193-012-0127-5. [PubMed: 23204783].
- Taxy JB, Battifora H. Angiosarcoma of the gastrointestinal tract. A report of three cases. *Cancer*. 1988;62(1):210-6. doi: 10.1002/1097-0142(19880701)62:1<210::aid-cnrcr2820620132>3.0.co;2-8. [PubMed: 3383117].
- Allison KH, Yoder BJ, Bronner MP, Goldblum JR, Rubin BP. An-giosarcoma involving the gastrointestinal tract: a series of pri-mary and metastatic cases. *Am J Surg Pathol*. 2004;28(3):298-307. doi: 10.1097/00000478-200403000-00002. [PubMed: 15104292].
- DiSario JA, Burt RW, Kendrick ML, McWhorter WP. Colorectal cancers of rare histologic types compared with adenocarcinomas. *Dis Colon Rectum*. 1994;37(12):1277-80. eng. doi: 10.1007/bf02257796. [PubMed: 7995158].
- Young RJ, Brown NJ, Reed MW, Hughes D, Woll PJ. Angiosarcoma. *Lancet Oncol*. 2010;11(10):983-91. doi: 10.1016/s1470-2045(10)70023-1. [PubMed: 20537949].
- Delvaux V, Scirot R, Neuville B, Moerman P, Peeters M, Filez L, et al. Mul-tifocal epithelioid angiosarcoma of the small intestine. *Virchows Arch*. 2000;437(1):90-4. doi: 10.1007/s004280000183. [PubMed: 10963385].
- Singla S, Papavasiliou P, Powers B, Gaughan J, von Mehren M, Watson JC, et al. Challenges in the treatment of angiosarcoma: a single institution experience. *Am J Surg*. 2014;208(2):254-9. doi: 10.1016/j.amjsurg.2014.01.007. [PubMed: 2481931].
- Naka N, Ohsawa M, Tomita Y, Kanno H, Uchida A, Myoui A, et al. Prognostic factors in angiosarcoma: a multivariate analysis of 55 cases. *J Surg Oncol*. 1996;61(3):170-6. doi: 10.1002/(sici)1096-9098(199603)61:3<170::Aid-jso2>3.0.Co;2-8. [PubMed: 8637202].
- Mehren MV, Randall R, Benjamin RS, Boles S, Jillian L. Scavone. Soft Tissue Sarcoma, Version 2.2018, NCCN Clinical Practice Guidelines in Oncology. *Journal of the National Comprehensive Cancer Network Jcnccn*. 2018;16(5):536.
- Mark RJ, Poen JC, Tran LM, Fu YS, Juillard GF. Angiosarcoma. A report of 67 patients and a review of the literature. *Cancer*. 1996;77(11):2400-6. doi: 10.1002/(SICI)1097-0142(19960601)77:11<2400::AID-CNCR32>3.0.CO;2-Z. [PubMed: 8635113].
- Budd GT. Management of angiosarcoma. *Curr Oncol Rep*. 2002;4(6):515-9. doi: 10.1007/s11912-002-0066-3. [PubMed: 12354365].
- Ravi V, Sanford EM, Wang WL, Ross JS, Ramesh N, Futreal A, et al. Anti-tumor Response of VEGFR2- and VEGFR3-Amplified Angiosarcoma to Pazopanib. *J Natl Compr Canc Netw*. 2016;14(5):499-502. [PubMed: 27160228].
- Zhang H. Apatinib for molecular targeted therapy in tumor. *Drug Des Devel Ther*. 2015;9:6075-81. doi: 10.2147/DDDT.S97235. [PubMed: 26622168]. [PubMed Central: PMC4654530].
- Liu S, Su Lingfei, Mu Xuri, Shi Yubo, Zhang Aifeng, Ge Xing-ping. Apatinib inhibits macrophage-mediated epithelial-mesen-chymal transition in lung cancer. *RSC Advances*. 2018;8(38):21451-9. doi: 10.1039/C8RA01231H.
- Roviello G, Ravelli A, Polom K, Petrioli R, Marano L, Marrelli D, et al. Apatinib: A novel receptor tyrosine kinase inhibitor for the treatment of gastric cancer. *Cancer Lett*. 2016;372(2):187-91. doi: 10.1016/j.canlet.2016.01.014. [PubMed: 26797419].
- Kou P, Zhang Y, Shao W, Zhu H, Zhang J, Wang H, et al. Significant efficacy and well safety of apatinib in an advanced liver cancer pa-tient: a case report and literature review. *Oncotarget*. 2017;8(12):20510-5. doi: 10.18632/oncotarget.14724. [PubMed: 28103584]. [PubMed Central: PMC5386780].
- Li F, Liao Z, Zhao J, Zhao G, Li X, Du X, et al. Efficacy and safety of Apatinib in stage IV sarcomas: experience of a major sarcoma center in China. *Oncotarget*. 2017;8(38):64471-80. doi: 10.18632/oncotar-get.16293. [PubMed: 28969086]. [PubMed Central: PMC5610018].
- Zhu B, Li J, Xie Q, Diao L, Gai L, Yang W. Efficacy and safety of apatinib monotherapy in advanced bone and soft tissue sarcoma: An observational study. *Cancer Biol Ther*. 2018;19(3):198-204. doi: 10.1080/15384047.2017.1416275. [PubMed: 29261005]. [PubMed Central: PMC5790336].