



DOI: 10.32768/abc.202184342-349



Dermatofibrosarcoma Protuberans and Adjuvant Radiotherapy: A Case Report with Uncertain Surgical Margins in The Breast

Alaettin Arslan^{*a}, Saliha Karagoz Eren^b, Serdal Sadet Ozcan^c, Ebru Akay^c, Mustafa Ozdemir^d

a Department of Radiation Oncology, Kayseri City Hospital, Kayseri, Turkey

b Department General Surgery, Kayseri City Hospital, Kayseri, Turkey

c Department of Pathology, Kayseri City Hospital, Kayseri, Turkey

d Department of Radiology, Kayseri City Hospital, Kayseri, Turkey

ARTICLE INFO

Received:

23 May 2021

Revised:

03 July 2021

Accepted:

03 July 2021

Keywords:

Dermatofibrosarcoma protuberans, uncertain surgical margins, adjuvant radiotherapy

ABSTRACT

Background: Dermatofibrosarcoma Protuberans (DFSP) is a rare, locally aggressive superficial soft tissue tumor that can occur in many parts of the body. Surgical resection with a wide margin of safety is the main treatment modality of this rare tumor of the breast. According to the postoperative pathology report, the patient can be followed up or adjuvant radiotherapy (RT) can be added.

Case presentation: A 22-year-old woman presented with a mass filling the lower inner quadrant of her right breast. Tru-cut biopsy revealed a mesenchymal tumor, but excision was recommended for definitive diagnosis. A right breast quadrantectomy was performed. The result came as DFSP. Tumor diameter was 10x9x6.5 cm and the tumor was positive in most of the surgical margins. The patient underwent re-resection and a residual tumor with a diameter of 0.2 cm was detected at a distance of 3.3 cm from the surgical margin. Although the surgical margins were negative, the distance of the posterior surgical margin, in particular, could not be assured. Because of the uncertainty of surgical margins, 60 Gy RT was planned.

Conclusion: The localization of DFSP in the breast is extremely rare and surgery is the primary treatment. RT should be added as an adjuvant when safe surgical margins cannot be obtained.

Copyright © 2021. This is an open-access article distributed under the terms of the [Creative Commons Attribution-Non-Commercial 4.0](https://creativecommons.org/licenses/by-nc/4.0/) International License which permits copy and redistribution of the material in any medium or format or adapt, remix, transform, and build upon the material for any purpose, except for commercial purposes.

INTRODUCTION

Dermatofibrosarcoma Protuberans (DFSP) is a rare soft tissue tumor. It may occur in any region, but is mostly seen in the lower neck, upper chest and shoulder girdle regions.¹ The incidence of breast involvement is very low.² Rare cases of the male breast have also been reported.³ Most studies have shown that

both sexes are affected equally. It is a low-to-moderate grade superficial tumor originating mainly from the dermis. As in other soft tissue tumors, surgical resection is the primary and only potentially curative treatment in DFSP. The local recurrence rate varies between 1.6% and 50% depending on the type of surgery used.⁴ Extremely low local recurrence rates were achieved with Mohs surgery with cure results of up to 98.5%.⁵ Mohs surgery is internationally recognized as the preferred treatment for DFSP. In the National Comprehensive Cancer Network (NCCN) guidelines, Mohs surgery is listed first and wide local excision with a margin of 2-4 cm is recommended.^{6,7} Local recurrence usually occurs within three years,

* Address for correspondence:

Alaettin Arslan, MD

Address: Department of Radiation Oncology, Kayseri City Hospital, Kayseri, Turkey

Tel: +903523157700

Email: alaettin.arslan@gmail.com

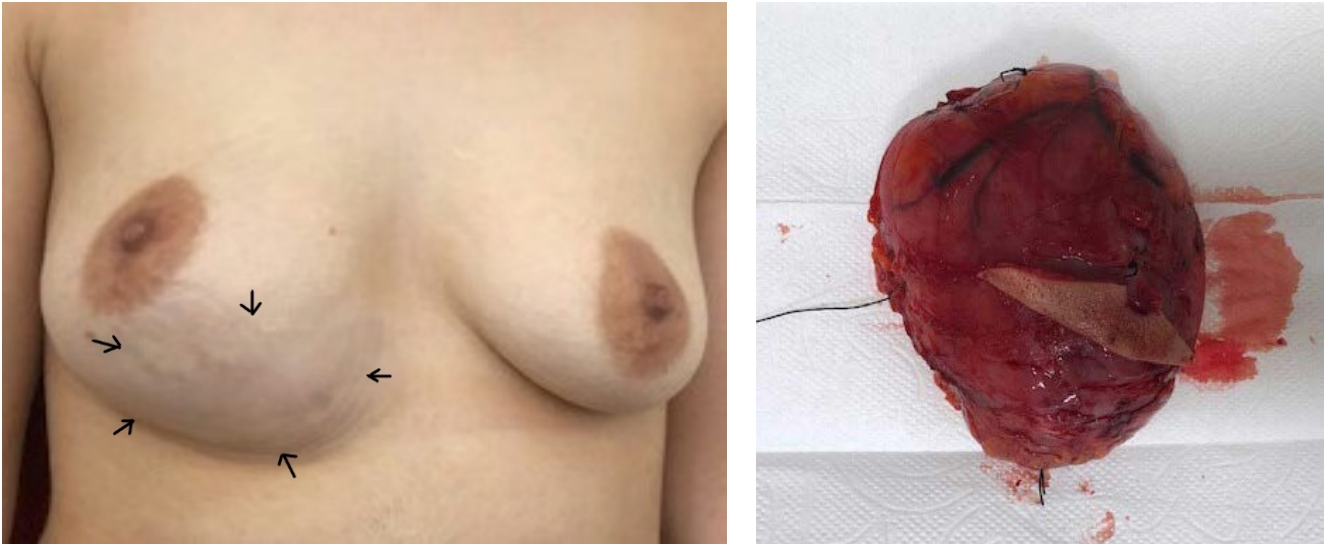


Figure 1. a) Preoperative appearance. On physical examination, the mass image in the lower inner quadrant of the right breast, indicated by arrows. b) Postoperative tumor appearance. Tumor diameter was 10x9x6.5 cm.

depending on the status of surgical margins and the degree of tumor.⁸ Although it is a locally aggressive tumor, distant metastasis is rarely seen and usually develops as a result of local recurrence. Adjuvant radiotherapy (RT) is still controversial. In the case of a positive surgical margin or macroscopic residue, RT between 50 and 66 Gy is recommended.⁶ The approach differs in patients whose surgical margins are negative. The main reason for this is that DFSP requires wide local excision. However, the addition of adjuvant RT to large local excision has been reported to increase survival.^{9, 10}

In this study, we present the methods of distinguishing a case diagnosed with DFSP from other similar pathologies and the principles of surgery and RT in its treatment.

CASE PRESENTATION

A 22-year-old woman presented with a mass filling the lower inner quadrant of her right breast (Figure 1a). In breast ultrasonography (USG), an encapsulated, well-circumscribed, oval-shaped mass measuring 7.5x3 cm was detected. On Doppler USG, a hypoechoic appearance was observed with significant bleeding. MRI examination did not reveal any malignancy. Tru-cut biopsy revealed a mesenchymal tumor (juvenile fibroadenoma or phyllodes tumor), but excision was recommended for definitive diagnosis. A right breast quadrantectomy was performed. The result came as DFSP. Tumor diameter was 10x9x6.5 cm (Figure 1b). In the hematoxylin-eosin (H&E) sections, spindle cell proliferation without capsule, starting from the middle of the dermis, was observed. Skin appendages were observed within the spindle neoplasm (Figure 2). In immunohistochemical studies

(IHC), tumor cells showed diffuse positive staining with vimentin and CD34, supporting DFSP (Figure 3). Ki 67 proliferation index was 15%. In order to differentiate this tumor from other mesenchymal neoplasms, CD31, ALK, H-Caldesmon, SMA, CD117 and STAT 6 negative were found (Figure 4). ER, PR, desmin, S100, bcl2, pankeratin negativity helped to differentiate the tumor from the metaplastic carcinoma and melanoma (Figure 5). Honey-comb like infiltration of tumor cells into adipose tissue, preservation of skin appendages, and in immunohistochemical studies, CD34 positivity, ER, PR negativity, absence of pankeratin and epithelial component in any area are helpful in distinguishing the tumor from phyllodes tumor and supporting DFSP. Tumor was positive in most of the surgical margins. In this case, the patient consulted with RT and re-resection was recommended. The patient underwent re-resection and a residual tumor with a diameter of 0.2 cm was detected. The safe surgical margins were not assured regarding pathology report after re-resection. The presence of diffuse fibrocystic changes and fibroadenoma in the surrounding breast tissue as well as the tumor in the re-resection material caused difficulty in determining the tumor margins. The pathology was reevaluated and the surgical margin was found to be 3.3 cm. The surgeon was also interviewed and the distance of surgical margins was accepted as 'indeterminate'. In surgical exploration, it was observed that the posterior surgical margin rested on the chest wall and the surgical margin could not be 3.3 cm at this distance. The posterior surgical margin was found not to be more than 1-1.5 cm. PET-CT was performed and several LNs were detected in the right axillary fossa. There was no metastasis in tru-cut axillary LN biopsy. Adjuvant

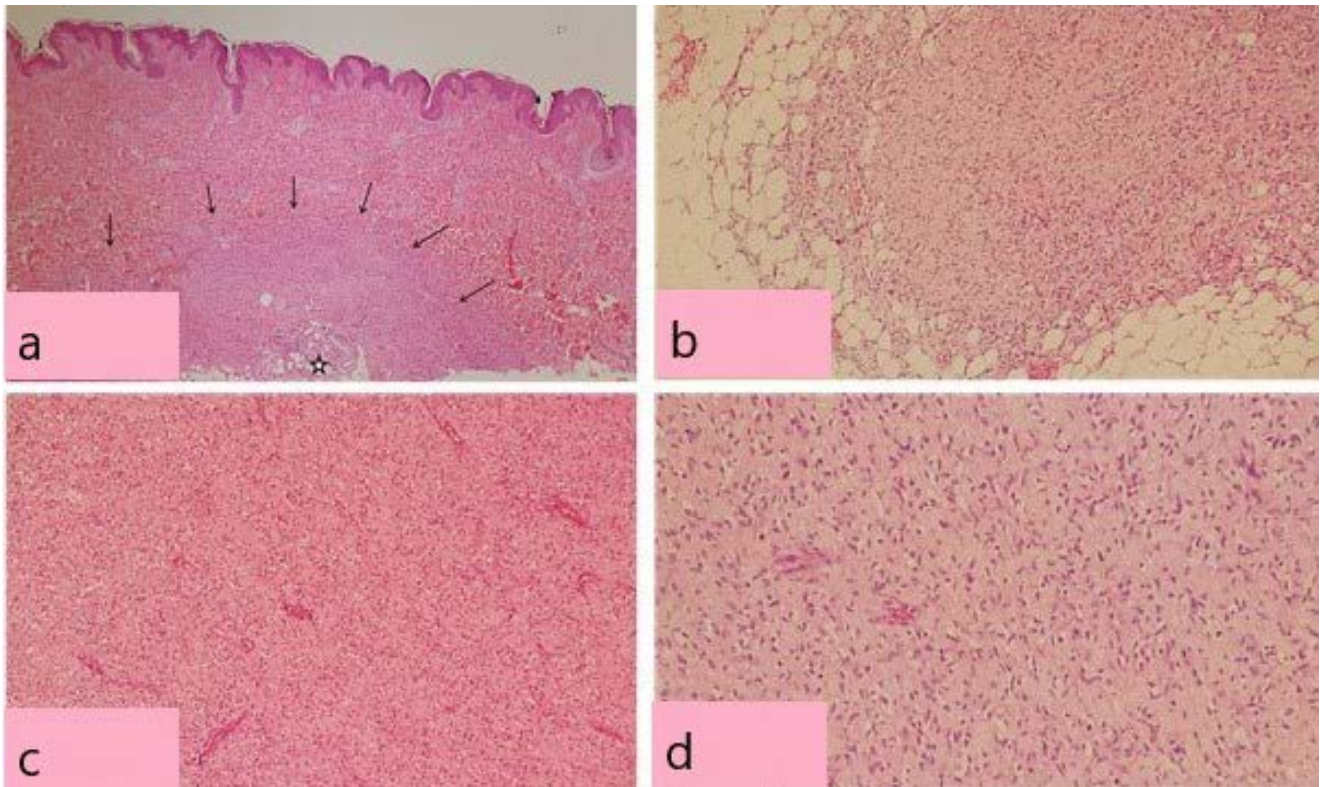


Figure 2. Hematoxylin-eosin (H&E) sections.

- HEX40. Multi-layered flat epithelial cover at the top, capsule-free spindle cell proliferation (arrow) starting from the middle of the dermis and proceeding deeper. One of the features of the lesion is the presence of preserved adnexal structures (asterisk).
- HEX100. Picture of tumoral cells infiltrating between the fat cells in the honeycomb style, whose borders cannot be clearly separated.
- HEX100. Tumor tissue, which is composed of spindle cells and does not contain epithelial components, is observed.
- HEX200. Close-up view of spindle cells of the tumor.

radiotherapy was considered to reduce the risk of local recurrence due to the uncertainty of surgical margins and 60 Gy was planned.

CT was taken for RT planning. The patient was initially operated on with a preliminary diagnosis of phyllodes tumor. Therefore, no clips were placed in the operation. Gross tumor volume (GTV) was contoured with reference to the incision scar. The recommended 60 Gy was given in two phases. Clinic target volume (CTV) 50 was formed by giving a 3 cm margin to the GTV and CTV 60 was formed by giving a 2 cm margin to the GTV. Natural barriers and critical organs were removed from CTV. Planning target volume (PTV) 50 and 60 were determined by a 0.5 cm margin for respiratory movements and set-up errors (Figure 6). The remaining right breast, left breast, both lungs, spinal cord, and liver were contoured after the operation to identify critical organ doses. Intensity-modulated RT (IMRT) technique was used with a 4-fields plan. A 0.5 cm bolus was used to increase the skin dose. The dose homogeneity was targeted to be between 95% and 107% in PTV (Figure 7). Because of

the uncertainty of surgical margins, 60 Gy RT was planned. On the RT planning, it was determined in the dose-volume histogram (DVH) where the organs at risk (OARs) dose limits were not exceeded (Figure 8). The doses received by OARs were found as follows: Right breast Dmean 20 Gy, left breast Dmean 1.5 Gy, heart Dmean 0.53 Gy, right lung (Dmean 1.7 Gy, V10 3.17%, and V20 1.7%), liver Dmean 7.48 Gy, and spinal cord Dmax 1.28 Gy.

Our patient has come to the controls regularly after the treatment. No pathology was found in the breast MRI taken at the last visit, and follow-up continues in the 24th month without the disease.

DISCUSSION

Treatment of DFSP requires a multidisciplinary approach. Radiological examinations are of great importance in the diagnosis stage. Ultrasonography and mammography are important tools for differentiating DFSP from primary breast lesion.¹¹ MRI may help define the depth of infiltration of the tumor.¹² The necessary surgical operation should be

performed with wide safety limits as described in the literature.^{3, 6, 9, 10, 13} In case of insufficient surgical margins or residues, re-resection should be performed if the anatomical region makes it possible.^{3, 9} There

are studies in the literature where 60 Gy RT was applied despite negative margin.^{14, 15} After wound healing, RT should be applied if it is considered.¹⁰

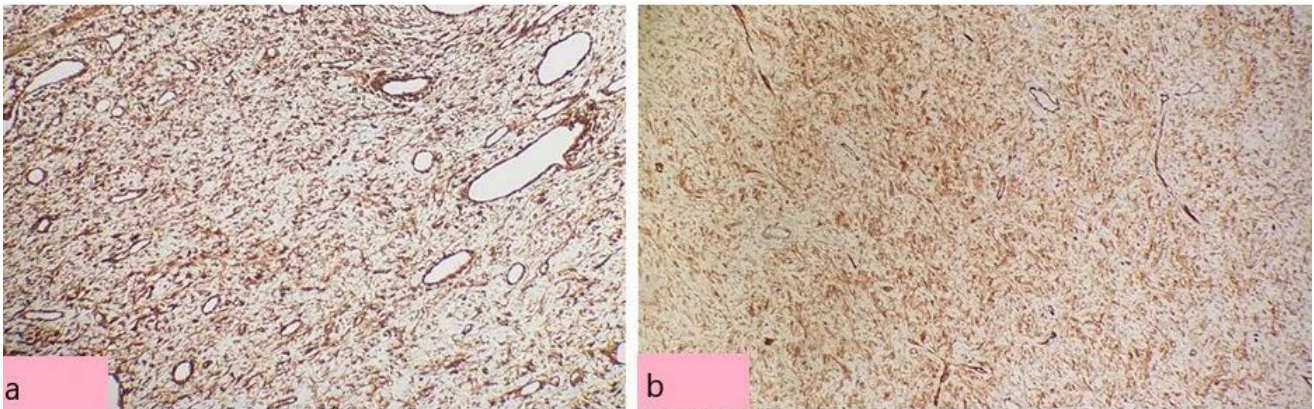


Figure 3. Staining with Vimentin and CD34. Diffuse positive staining was achieved in tumor cells with a) Vimentin (x100), b) CD34 (x40).

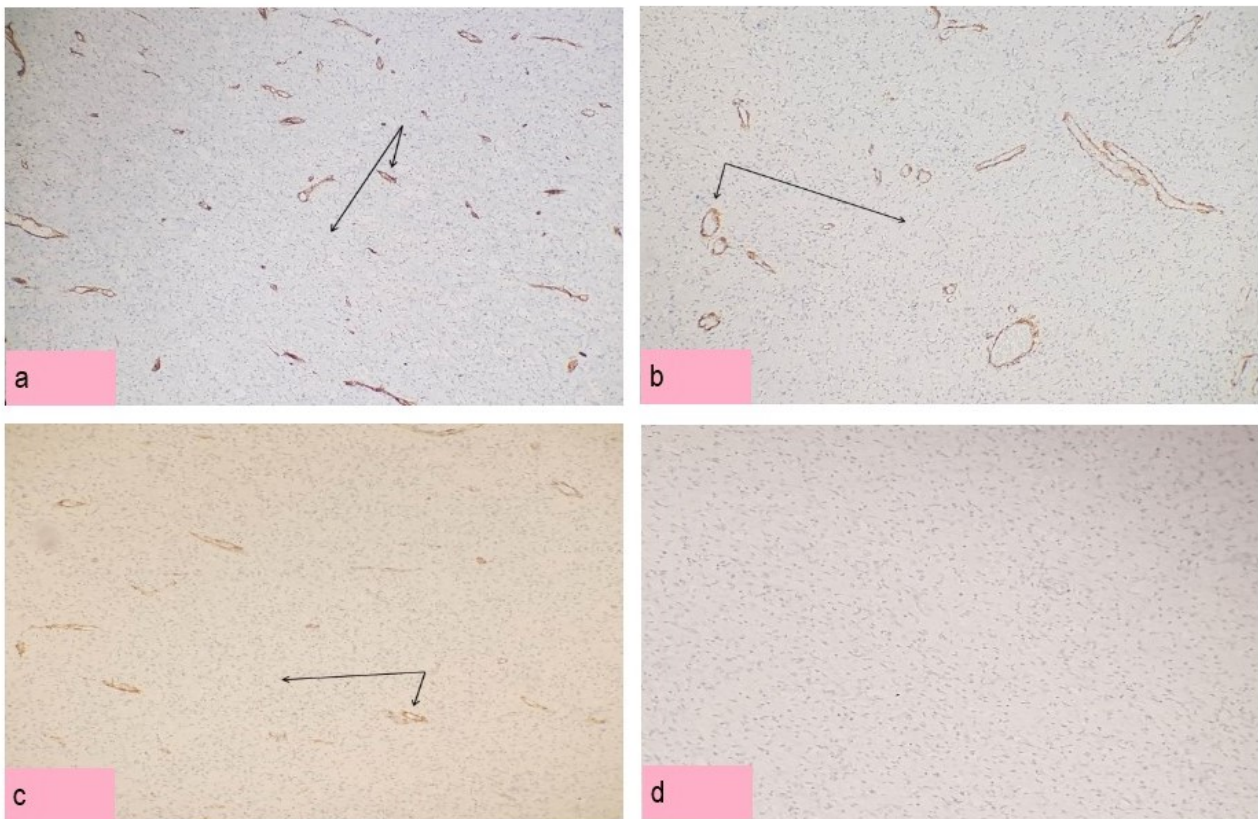


Figure 4. Staining used to distinguish it from other mesenchymal neoplasms.

- CD31x40. While positive staining was observed in the vessel walls (short arrow) with CD31, negative staining (long arrow) was obtained in tumor cells.
- SMAx40. While positive staining was observed in the vessel walls (short arrow) with SMA, negative staining (long arrow) was obtained in tumor cells.
- H-Caldesmonx40. While positive staining was observed in the vessel walls (short arrow) with H-caldesmon, negative staining (long arrow) was obtained in tumor cells.
- Cd117x40. Negative staining was obtained in tumor cells with CD117.

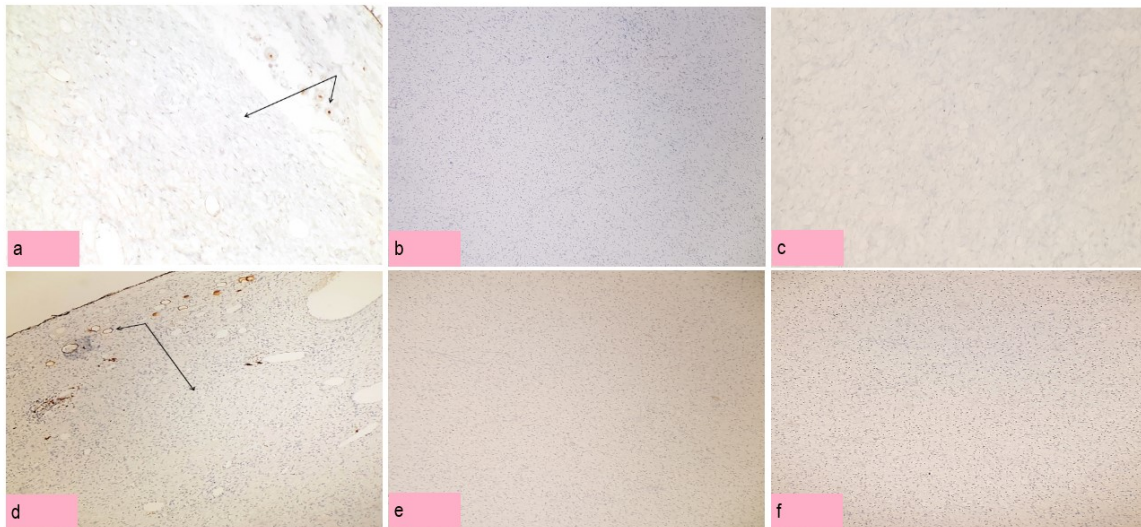


Figure 5. Staining used to distinguish it from the metastatic carcinoma and melanoma.

- a) ERx40. While positive staining was observed in several glandular epithelium trapped in the lesion periphery with estrogen (short arrow), negative staining (long arrow) was obtained in tumor cells.
- b) PRx40. Negative staining was obtained in tumor cells with progesterone.
- c) Desminx40. Negative staining was achieved in tumor cells with Desmin.
- d) S100x40. While positive staining was observed in several adiposides stuck with S100 (short arrow), negative staining (long arrow) was obtained in tumor cells.
- e) Bcl2x40. Negative staining was achieved in tumor cells with Bcl2.
- f) Pankeratinx40. Negative staining was obtained in tumor cells with pankeratin.

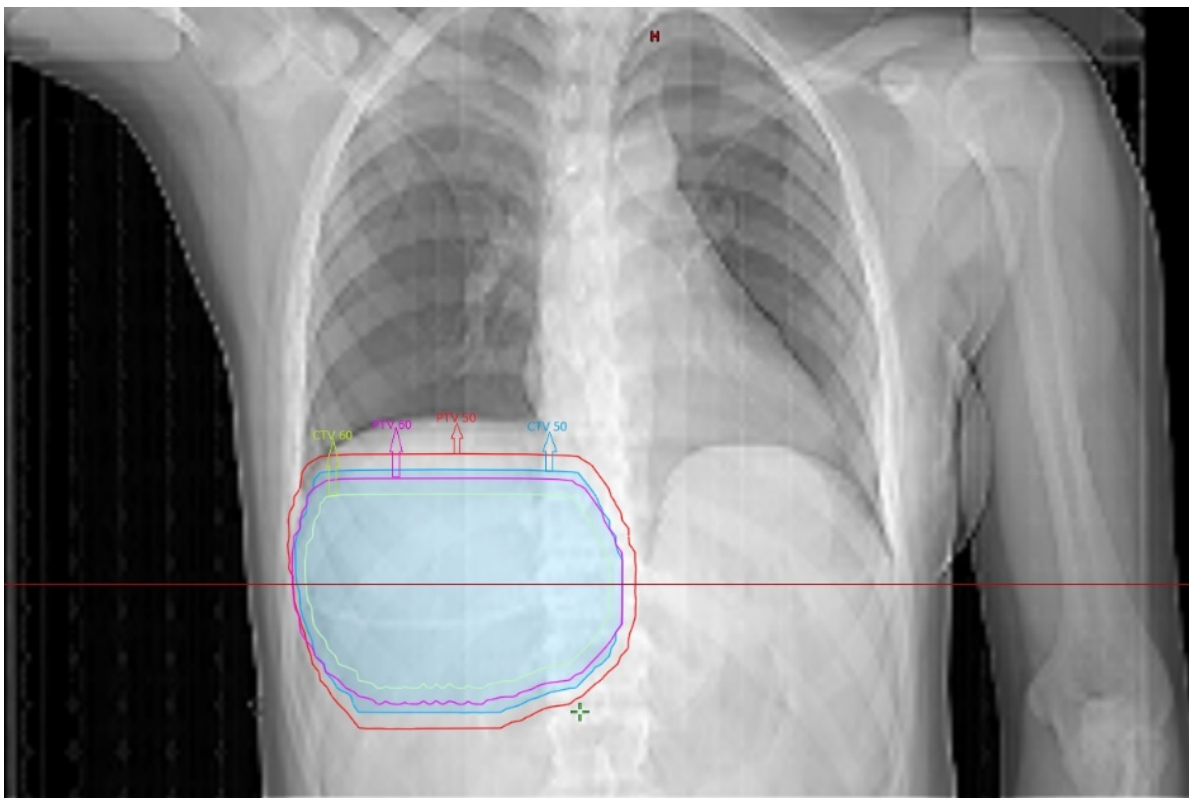


Fig. 6. Two-dimensional view of CTV₅₀₋₆₀ and PTV₅₀₋₆₀. For the PTV 50-60, CTV 50-60 is given a 0.5 cm safety margin. CTV: Clinic target volume, PTV: Planning target volume.

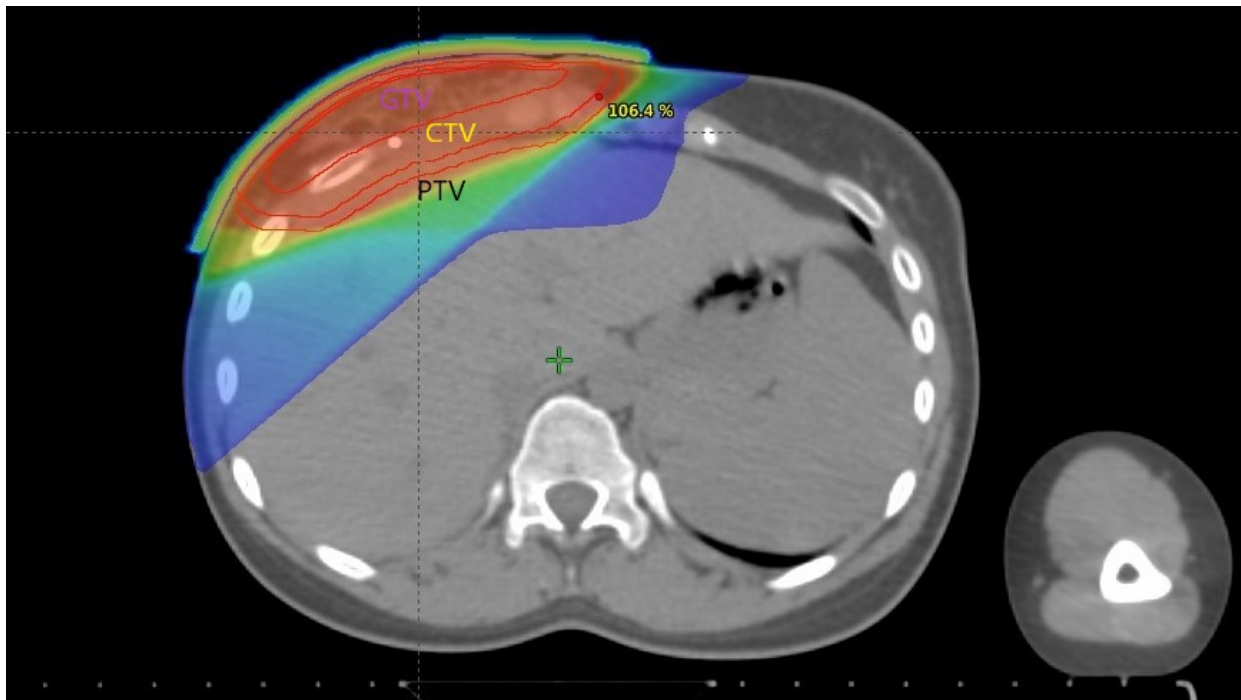


Figure 7. PTV dose distribution.

The dose homogeneity was targeted to be between 95% and 107% in PTV.

GTV: Gross tumor volume (tumor bed), CTV: Clinic target volume, PTV: Planning target volume.

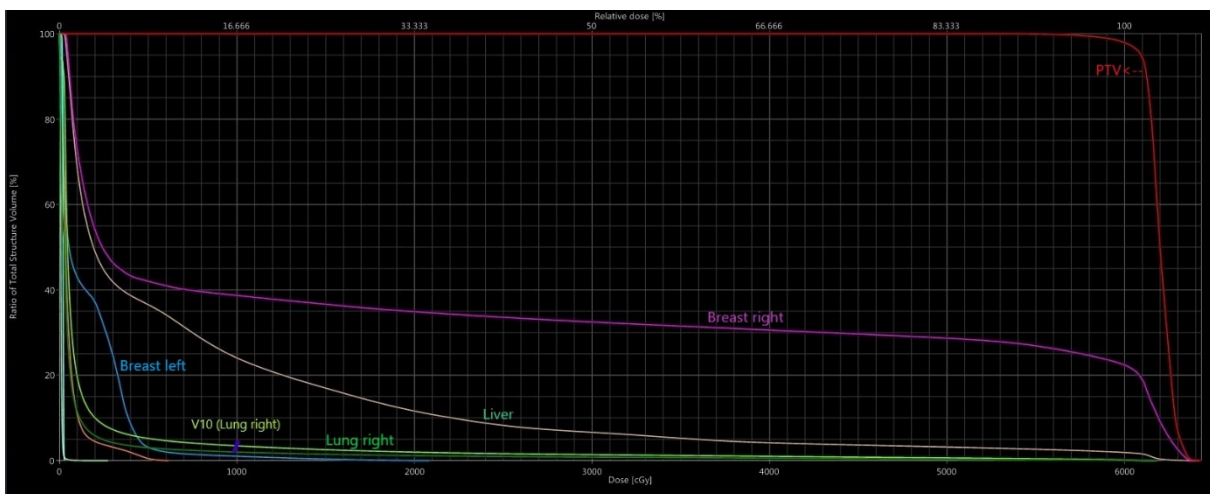


Fig. 8. Dose-volume histogram and V10 right lung volume. The graph shows the curves of PTV 60 and OARs. In addition, the volume of the right lung receiving 10 Gy dose was marked on the curve (3,17%). Of the unmarked curves, the turquoise-colored curve shows the left lung, the orange-colored curve shows the heart, the dark green-colored curve shows the total lung.

Research has been done on DFSP located in different parts of the body. In the study of Zhou *et al.*, 80 DFSP patients were evaluated retrospectively.⁷ The rate of local recurrence was significantly lower in patients who underwent wide local excision (>3 cm) than the local excision (less than 3 cm) group. In addition, no recurrence was observed in 10 patients who underwent Mohs surgery. In a retrospective study of 14 patients by Chan *et al.*, all patients underwent extensive local excision with a 3 cm safety margin and then all patients received adjuvant RT (45-50 Gy) after wound healing.¹⁶ After a mean follow-up of 30 months (18-68 months), no

recurrence was observed. This study demonstrates that the addition of RT to wide local excision has the effect of reducing local recurrence. Castle *et al.* in a study of 53 patients, patients underwent surgery followed by RT. Seven patients were treated with preoperative RT (50-50.4 Gy) and 46 patients with postoperative RT (60-66 Gy). Of the 46 patients receiving postoperative radiation, 3 had gross disease, 14 positive margins, 26 negative margins, and 3 uncertain margin status. Five-year and 10-year overall survival (OS) was 98%, while disease-free survival (DFS) was 98% and 93%, respectively. They concluded that DFSP is a disease with excellent local



control after conservative surgery and RT. They also emphasized that adjuvant RT should be considered when it causes significant morbidity for patients with large or recurrent tumors or for interventions at large surgical margins.¹⁴

Breast localized DFSP studies are much rarer. When PubMed is scanned, approximately 60 studies are published and almost all of them are case-based studies. Yihua Wang *et al.* studied 6 patients diagnosed with DFSP located in the breast. Five of the patients were women. Wide local excision was performed in 5 patients and mastectomy was performed in 1 patient. Tumor diameters in all patients ranged from 1-3 cm. The patients were operated on with a margin of 2-4 cm and postoperative RT was applied to 2 patients.¹⁷ In the case presented by Salim Al-Rahbi *et al.*, firstly, an excisional biopsy was performed and wide local excision was performed after positive surgical margins. Although negative surgical margins were obtained, postoperative RT was applied to the case.¹⁸ In a case report by Amr Muhammed *et al.*, DFSP located in the lower quadrant of the right breast was operated on with wide local excision, but the margin of safety remained less than 1.5 cm. Therefore, postoperative 60 Gy RT was applied to the patient. CTV was created by giving a 3 cm margin to the tumor bed, and PTV was created by giving a 1 cm margin to the CTV.¹⁹

Although the cases of DFSP in the breast are limited, the first priority issue is the removal of the tumor with wide local excision, as understood from the published cases. Although different information has been presented, surgical margins of 2-4 cm should be obtained. Adjuvant RT should be administered according to adverse risk factors that will reduce local control, such as tumor diameter Ki 67 value, and positive or near surgical margins after surgery. In fact,

Chen *et al* reported that adjuvant RT should be applied regardless of surgical margins in a general DFSP meta-analysis study involving 167 patients.¹⁶ Adjuvant RT was reported to provide 98% and 93% local control for 5 and 10 years, respectively.¹⁴

Based on the literature, we decided to use adjuvant RT: The size of the initial tumor, the surgical margin of approximately 3 cm despite the second operation, suspicion of the posterior surgical margin and because the patient was young. 60 Gy was preferred as the RT dose based on the studies. Our decision was reasonable as the anatomic location of the tumor was not suitable for a larger (>4 cm surgical margin) resection. Our patient fully complied with RT treatment. She continues her regular controls and no recurrence or metastasis has been observed.

CONCLUSION

In conclusion, DFSP is a rare but important disease in terms of both surgery and follow up, due to high local recurrence. Therefore, operation with wide safety margins should be the first choice and safe surgical margins should be obtained. Adjuvant RT should be decided by considering pathology, age of the patient and re-resection problems according to the location of the tumor.

ETHICAL CONSIDERATIONS

Written informed consent was obtained from the patient who participated in this study to present the images and documents in this journal.

FINANCIAL DISCLOSURE

The authors declare that this study has received no financial support.

CONFLICTS OF INTEREST

The authors have no conflicts of interest to declare.

REFERENCES

1. Weiss SW, Goldblum JR. Enzinger and Weiss's soft tissue tumors. Mosby-Elsevier. 2008:303-24.
2. Prabhu VV, Shivani A, Kulkarni S, Pawar VR. Dermatofibrosarcoma protuberans: male breast. Med J Dr DY Patil Univ. 2014;7(1):85.
3. Cottier O, Fiche M, Meuwly JY, Delaloye JF. Dermatofibrosarcoma presenting as a nodule in the breast of a 75-year-old woman: a case report. J Med Case Rep. 2011;5:503.
4. Guillou L, Folpe A. Bone and Soft tissue Pathology; in the Series: Foundations in Diagnostic Pathology. JR Goldblum editor. 2010:79-83.
5. Snow SN, Gordon EM, Larson PO, Bagheri MM, Bentz ML, et al. Dermatofibrosarcoma protuberans: a report on 29 patients treated by Mohs micrographic surgery with long-term follow-up and review of the literature. Cancer. 2004;101(1):28-38.
6. Garcia C, Clark RE, Buchanan M. Dermatofibrosarcoma protuberans. Int J Dermatol. 1996;35(12):867-71.
7. Zhou X, Sun D, Liu Y, Sun Q, Yuan Z, et al. Dermatofibrosarcoma protuberans: our 10-year experience on 80 patients. J Dermatolog Treat. 2020;31(6):554-8.



8. Ruiz-Tovar J, Fernandez Guarino M, Reguero Callejas ME, Aguilera Velardo A, Arano Bermejo J, et al. Dermatofibrosarcoma protuberans: review of 20-years experience. *Clin Transl Oncol*. 2006;8(8):606-10.
9. Kimmel Z, Ratner D, Kim JY, Wayne JD, Rademaker AW, et al. Peripheral excision margins for dermatofibrosarcoma protuberans: a meta-analysis of spatial data. *Ann Surg Oncol*. 2007;14(7):2113-20.
10. Chan T-C, Wu C-J, Jeng S-F. Dermatofibrosarcoma protuberans: A 10-year experience. *Formos J Surg*. 2015;48(1):10-6.
11. Park TH, Seo SW, Kim JK, Chang CH. Reconstructive challenge of dermatofibrosarcoma protuberans in the female breast. *World J Surg Oncol*. 2011;9:1.
12. Swan MC, Banwell PE, Hollowood K, Goodacre TE. Late recurrence of dermatofibrosarcoma protuberans in the female breast: a case report. *Br J Plast Surg*. 2005;58(1):84-7.
13. Mirza TI, Akhtar K, Abbas HB, Sameena M, Tahir F, et al. Dermatofibrosarcoma Protuberans Male Breast: A Case report. *Oman Med J*. 2011;26(5):e023.
14. Castle KO, Guadagnolo BA, Tsai CJ, Feig BW, Zagars GK. Dermatofibrosarcoma protuberans: long-term outcomes of 53 patients treated with conservative surgery and radiation therapy. *Int J Radiat Oncol Biol Phys*. 2013;86(3):585-90.
15. Williams N, Morris CG, Kirwan JM, Dagan R, Mendenhall WM. Radiotherapy for dermatofibrosarcoma protuberans. *Am J Clin Oncol*. 2014;37(5):430-2.
16. Chen YT, Tu WT, Lee WR, Huang YC. The efficacy of adjuvant radiotherapy in dermatofibrosarcoma protuberans: a systemic review and meta-analysis. *J Eur Acad Dermatol Venereol*. 2016;30(7):1107-14.
17. Wang Y, Wang Y, Chen R, Tang Z, Liu S. A Rare Malignant Disease, Dermatofibrosarcoma Protuberans of the Breast: A Retrospective Analysis and Review of Literature. *Biomed Res Int*. 2020;2020:8852182.
18. Al-Rahbi S, Al-Lawati T, Al-Kharusi S, Thomas S, Al-Harrasi K. Dermatofibrosarcoma Protuberans: A Rare Malignancy of the Breast. *Oman Med J*. 2015;30(5):378-81.
19. Muhammed A, Elnakib E, Nady M. Dermatofibrosarcoma of The Breast - Case Report and Review of Literature. *Eur J Breast Health*. 2018;14(4):234-7.

How to Cite This Article

Arslan A, Karagoz Eren E, Ozcan SS, Akay E, Ozdemir M. Dermatofibrosarcoma Protuberans and Adjuvant Radiotherapy: A Case Report with Uncertain Surgical Margins in The Breast. *Arch Breast Cancer*. 2021; 16(4):342-349.

Available from: <https://www.archbreastcancer.com/index.php/abc/article/view/424>