

Successful Anaesthetic Management Of Meckel-Gruber Syndrome: A Case Report

Vamshi Krishna¹, Nishith Govil^{1*}, Vijay Adabala¹, Jitender Chaturvedi²

¹Department of Anesthesiology, All India Institute of Medical Sciences Rishikesh, Rishikesh, India.

²Department of Neurosurgery, All India Institute of Medical Sciences Rishikesh, Rishikesh, India.

ARTICLE INFO

Article history:

Received 06 April 2020

Revised 27 April 2020

Accepted 12 May 2020

Keywords:

Meckel Gruber syndrome;

Encephalocele;

Airway;

ABSTRACT

Meckel Gruber syndrome (MGS) is one of the rare autosomal recessive inherited disorder affecting several organ systems of the body. It is specifically characterised by occipital encephalocele, bilateral polycystic kidney, post axial polydactyly making the airway management difficult.

We would like to share successful management of a case of Meckel Gruber syndrome with giant occipital-cervical encephalocele posted for excision. Difficult airway cart was kept ready prior to intubation. This includes laryngeal mask airway of appropriate size, high frequency jet ventilation, fibre-optic bronchoscope, a cricothyroid cannula and preparations for tracheostomy.

Anaesthesia to paediatric age group poses many challenges to anaesthesiologist and that for congenital anomalies add to it. Working knowledge of these kind of syndromes and specific considerations for the same should be kept in mind when assessing a case of occipital encephalocele leading to more effective and appropriate management of cases.

© 2020 Tehran University of Medical Sciences. All rights reserved.

Meckel Gruber syndrome (MGS) is one of the rare autosomal recessive inherited disorder affecting several organ systems of the body. It is specifically characterised by occipital encephalocele, bilateral polycystic kidney, post axial polydactyly [1] making the airway management difficult [2]. Although a rare syndrome worldwide its incidence was reported to be high in gujarati Indians [1].

Anaesthesia to paediatric age group poses many challenges to anesthesiologist and that for congenital anomalies adds to it. Usually airway of children differs from airway of adult in terms of large head, small oral cavity etc. In addition to this if there is occipital mass like encephalocele proper position of the head during airway manipulation becomes much more difficult. When the herniating sac is bigger than the head size or occipito-frontal circumference it is termed as giant encephalocele. We share a successful management of a case with Meckel Gruber syndrome with giant occipito-cervical encephalocele posted for excision.

Case Report

A one and half year old girl of weight 7.5kg brought to neurosurgery department of our institute with history of swelling at back of her head since birth which was gradually increasing in size [Figure 1]. On examination she was conscious and playful, moving all limbs equally without any paucity. She had cleft palate, micrognathia with low set ears, short & webbed neck and polydactyly of right hand. Ultrasound abdomen revealed microcysts in both kidneys. Her head circumference was 46cm with anterior fontanel closed. Size of the swelling was 50cm x 36cm, larger than her head circumference. Imaging of head and neck revealed bony defect not only in infra-torcular region of the occipital bone but also in the posterior elements of the atlas, axis, 3rd and 4th cervical vertebrae [Figure 2]. Rest of blood investigations were normal. Written informed consent was taken with risk of

The authors declare no conflicts of interest.

*Corresponding author.

E-mail address: nishithgovil@rediffmail.com

© 2020 Tehran University of Medical Sciences. All rights reserved.

postoperative mechanical ventilation explained to both surgeons and relatives.

Figure 1- Preop before excision

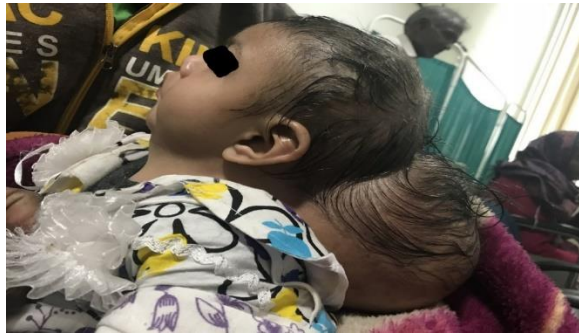
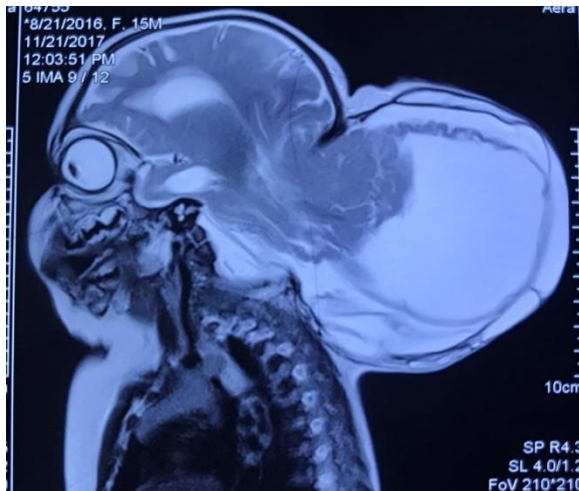

Figure 2- Occipital encephalocele involving posterior elements of the atlas, axis, 3rd and 4th cervical vertebrae.



Baby posted for excision of encephalocele sac under general anaesthesia. Operation theatre was kept warm and emergency airway cart was kept ready. Baseline parameters of baby recorded in lateral position were within normal limits. Baby received injection glycopyrrolate 0.05 mg and injection fentanyl 15 mcg intra venously and induced with sevoflurane. Only epiglottis was visualised during direct laryngoscopy in lateral position (Cormack Lehane grade 3) [9]. Due to non-availability of paediatric size fiber-optic bronchoscope we passed 1.5 size AMBU LMATM in lateral position, ventilated the baby and confirmed its correct position by capnography. To secure definitive airway, uncuffed 4.5 mm endotracheal tube was blindly inserted through AMBU LMA in trachea and confirmed its correct placement by capnography and bilateral auscultation of chest [Figure 3]. Intraoperatively baby placed in prone position and maintained with nitrous oxide, oxygen, sevoflurane and atracurium. Peri operative period was uneventful and post extubation baby shifted to post anaesthesia care unit for further

observation. Her body weight was 5 kg in immediate post-op period suggesting the contribution of sac to be 2.5 kg in her presenting weight. Baby got discharged from hospital after 17 days with follow up advised.

Figure 3- Equipment used for intubation



Discussion

Johann Friedrich Meckel in 1822 first described the syndrome MGS simply termed Meckel syndrome. Due to the involvement of several organ systems Meckel observed death in the pediatric age group [3]. Out of all the organ systems involved the major diagnostic criteria of MGS include at least 2 of these 3 classic manifestations such as cystic renal dysplasia, occipital encephalocele or other anomalies of central nervous system and polydactyly (found in 100%, 90% and 83.3% respectively) [4].

Varying presentations and the multi organ involvement makes this syndrome difficult for diagnosis and management of the case. Many infants die within hours of birth or if survive have poor quality of life. The cause of death could be due to organ dysfunctions like non-functional kidneys, liver and pulmonary hypoplasia. Ultrasound screening perinatally can be used to diagnose these disorders in the early trimesters. MGS can be

diagnosed as early as 14 weeks of gestation by ultrasound by characteristic findings of occipital encephalocele, polycystic kidneys and postaxial polydactyly [5].

Major anaesthetic challenge in management of occipital meningoencephalocele is securing the airway [6]. Because of the mandibular micrognathism and anatomical abnormalities of the larynx, tongue, and cervical vertebrae these patients usually present with difficult airway. Therefore, an alternative airway management plan should be ready prior to commencement of the procedure. Difficult airway cart should be kept ready prior to intubation. This should include laryngeal mask airway of appropriate size, high frequency jet ventilation, fibre-optic bronchoscope, a cricothyroid cannula and preparations for tracheostomy [7-8].

Specific attention has to be given to blood loss, maintenance of body temperature, position of head in prone position and its associated complications and endotracheal tube position [6]. Working knowledge of these kind of disorders should be kept in mind when assessing a case of occipital encephalocele which helps in effective and appropriate management of cases perioperatively.

References

- [1] Parelkar SV, Kapadins PS, Sanghvi BV, Joshi DM, Mundada D, Oak SN. Meckel-Gruber syndrome: A rare and lethal anomaly with review of literature. *J Pediatr Neurosci.* 2013;8(2):154-7.
- [2] Motoyama E, Davis P (1990) Clinical management of special surgical problems; anesthesia for general, urologic, and plastic surgery. In: *Smith's anesthesia for infants and children.* 5th edn. Mosby, St. Louis, p607.
- [3] Meckel JR. Beschreibung zweier durch sehr ahnliche Bildungsabweichung entseller Geschwister. *Dtsch Arch Phiol.* 1898; 7:99.
- [4] Paavola P, Salonen R, Weissenbach J, Peltonen L. The locus for Meckel syndrome with multiple congenital anomalies maps to chromosome 17q21-q24. *Nat Genet.* 1995; 11(2):213.
- [5] de Silva MV, Senanayaka H, Siriwardana KD. Meckel Gruber syndrome: occurrence in non-consanguineous marriages. *Ceylon Med J.* 2004; 49(1):30-1.
- [6] Creighton RE, Relton JES, Meridy HW. Anaesthesia for occipital encephalocele. *Can Anaesth Soc J.* 1974; 21(4): 403-6.
- [7] Newfield P, Hamid RKA. Anaesthesia for paediatric neurosurgery. In: Cottrell JE, Smith DS (editors): *Anaesthesia and Neurosurgery.* 4th ed., Mosby, 2001: 519-20.
- [8] American Society of Anesthesiologists Task Force on Management of the Difficult Airway. Practice guidelines for management of the difficult airway: an updated report by the American Society of Anesthesiologists Task Force on Management of the Difficult Airway. *Anesthesiology.* 2013; 98(5):1269-77.
- [9] Mahajan C, Rath GP, Bithal PK, Mahapatra AK. Perioperative management of children with giant encephalocele: a clinical report of 29 cases. *J Neurosurg Anesthesiol.* 2017; 29 (3):322-9.