

Clinical Value of Low Dose CT- Scan in Pediatric Chest Diseases: Adequacy Assessment

*Ali Alamdaran¹, Dana Mohammad amin², Jahanbakhsh Hashemi³, Negar Morovatdar⁴, Seyed Javad Sayedi⁵

¹Surgical Oncology Research Center, Mashhad University of Medical Sciences, Mashhad, Iran.

²Radiology Resident, Department of Radiology, Mashhad University of Medical Sciences, Mashhad, Iran.

³Department of Radiology, Faculty of Medicine, Mashhad University of Medical Sciences, Mashhad, Iran.

⁴Clinical Research Unit, Faculty of Medicine, Mashhad University of Medical Sciences, Mashhad, Iran.

⁵Department of Pediatrics, Sheikh Pediatrics Hospital, Mashhad University of Medical Sciences, Mashhad, Iran.

Abstract

Background

Radiation dose about 400 times that of standard thoracic computed tomography (CT) in comparison with chest X- ray resulting in different approaches to decrease radiation dose have been established in the last few years to prevent possible side effects especially in children, such as low dose protocols. The aim of this study was assessment of clinical value of low dose CT in pediatric chest diseases.

Materials and Methods

This prospective study was conducted from 2017 to 2019 in the radiology departments of Dr. Sheikh Children's hospital and Imam Reza Hospital, Mashhad, Iran. The low dose CT scans were conducted at 90 kVp and 30 mAs (for 0-6 years age group) in 27 cases or 50 mAs (for 6-12 years age group) in 17 cases. Eventually, the radiologic findings were compared with the confirmed diagnosis by pediatric pulmonologist based on clinical, laboratory and imaging findings. Data were analyzed and Kappa agreement coefficient test was performed to determine agreement between the low dose CT findings and the final diagnosis.

Results

Forty-four children were enrolled in this study. 72.7% (32 cases) of all patients had chronic cough as the most common initial symptom, and hyperactive airway disease (10 patients, 22.7%), and persistent bacterial bronchitis (9 patients, 20.5%) were the most frequent chest diseases. There was perfect agreement between the CT- scan findings and final diagnosis ($k=1$, $p<0.001$).

Conclusion

The current study revealed that diagnostic findings of the low dose CT- scan was adaptive with clinical needs for the final diagnosis.

Key Words: Chest, Children, Clinical Value, Low dose CT- scan.

*Please cite this article as: Alamdaran A, Mohammad amin D, Hashemi J, Morovatdar N, Sayedi SJ. Clinical Value of Low Dose CT- Scan in Pediatric Chest Diseases: Adequacy Assessment. Int J Pediatr 2020; 8(2): 10845-851. DOI: [10.22038/ijp.2019.14011](https://doi.org/10.22038/ijp.2019.14011)

*Corresponding Author:

Ali Alamdaran, Surgical Oncology Research Center, Mashhad University of Medical Sciences, Mashhad, Iran.

Email: simpore93@gmail.com

Received date: Mar.12, 2019; Accepted date: Dec.22, 2019

1- INTRODUCTION

Thoracic pathologies in children may appear in different locations of the thorax including the mediastinum, lung parenchyma, chest wall or pleura and they include a wide range from reversible simple hazard to malignant tumors (1). CT is frequently considered a modality of choice after chest X-ray (CXR), which is the most common imaging performed in detecting pediatric chest diseases, fails in solving more complicated cases (2-6). However, it is well established that ionizing radiation forced by CT imaging may increase the risk of cancers such as leukemia and brain cancer particularly in children. Keeping in mind the value of CT in detecting pediatric chest diseases, the risk/benefit ratio should always be estimated (7, 8). Fortunately today, thoracic ultrasound examination is presented as a diagnostic and completely valuable modality in lung opacities, that can be used for the differentiation of pediatric thoracic opacities instead CT-scan and even US had higher sensitivity than CT-scan for mass nature determination (9, 10). Despite this, using CT in pediatrics has increased globally over the past few years (7, 8).

Since thorax is considered highly sensitive to ionizing radiation, dose adjustment with the best possible quality is required in CT imaging (11). Radiation dose adjustment still remains a significant challenge to be tackled regarding the pediatric patients (12). In line with the aforementioned dilemma, various strategies have been presented to reduce the ionizing radiation caused by CT in pediatric patients as they are more prone to radiation, due to their longer life expectancy following radiation and also sensitive body structure (12). The radiation dose about 400 times that of standard thoracic computed tomography (CT) in comparison with chest X-ray resulting in different approaches to decrease radiation dose have been

established in the last few years to prevent possible side effects especially in children, such as low dose protocols. Different approaches have been introduced recently in order to decrease the radiation dose without significant loss of information such as automatic adjustment of tube current, reduced tube voltage (Kilovoltage peak [kVp], and the tube current exposure time product value [(mAs)]), noise reduction filters, gantry rotation time (the exposure time), slice thickness (collimation), the scan length and a higher pitch (13-15). The purpose of this study was to determine whether low-dose chest CT with 90 kVp and 30 or 50 mAs could be diagnostic in pediatric chest diseases based on clinical needs.

2- MATERIALS AND METHODS

2-1. Study design and population

The current prospective study was conducted from 2017 to 2019 in the radiology department of Dr. Sheikh Children's hospital, which is a tertiary center in Mashhad Medical University of Sciences, Mashhad, Iran. A total of 44 pediatric patients were admitted for the low dose CT imaging in this period and all of them were enrolled in this study.

2-2. Methods

Because of the high weight difference, the patients were divided to two groups: 0-6 years old, and 6-12 years old. The imaging findings of low dose CT studies were reviewed by our pediatric radiologist who had no previous knowledge regarding the final diagnosis and the final diagnosis was confirmed by pediatric pulmonologist based on clinical, laboratory and imaging findings. Eventually, we recorded the demographic characteristics including age, sex, low dose CT-scan and clinical findings and the final diagnosis.

2-3. Laboratory measurements

CT scanner machine was Neuviz 16, Neusoft Medical Systems, China.

2-4. Intervention

CT scans were conducted at 90 kVp (instead 120 kVp), 30 mAs (for 0-6 year's age group), and 50 mAs (for 6-12 years old age group) instead of auto (22-309) (Figure.1).

2-5. Ethical consideration

This study was carried out after obtaining confirmation from the Mashhad Medical University's Ethics Committee with ID-code: 960462.

2-6. Inclusion and exclusion criteria

As this study is clinical needs based research, numerous pediatric thoracic opacities were assigned with thoracic ultrasound examination as a diagnostic value valuable in lung opacities. Then, low dose CT imaging was mainly performed based the indications other than lung opacities, such as hyperinflation, suspicious for bronchiectasis, etc. Children without existing or available imaging reports were excluded.

2-7. Data Analyses

The results of low dose CT- scan, clinical findings and final diagnosis were compared. Data on demographic and clinical features of the patients were analyzed using SPSS software version 23.0. To describe the data, descriptive

statistical methods including central indicators, dispersion and frequency distribution were used. We used Kapa agreement coefficient test to determine if there was agreement between the low dose CT- scan reports and the final diagnosis.

3- RESULT

Among 44 children who participated in the current study, 27 (61.4%) were male and 17 (38.6%) were female. The mean age of the boys and girls were 59.59 ± 46.2 and 63.35 ± 43.8 months. Two age groups of patients were 0-6 years with 27 (61.4%) cases, and 6-12 years with 17 (38.6%) cases. According to the clinical findings, 32 patients (72.7%) were admitted with chronic cough, 7 patients (15.9%) with chronic cough and fever, 3 patients (6.8%) with chronic cough and dyspnea, and 2 patients (4.5%) with chronic cough, dyspnea and fever as initial symptoms. There is no significant relation between age with clinical symptoms of children ($p=0.818$). Final diagnosis of the participants is demonstrated in **Table.1**. The hyper reactive airway disease (22.7%), and persistent bacterial bronchitis (20.5%) were the most common final diagnoses. We used Kappa agreement coefficient test to determine if there was agreement between the low dose CT- scan diagnostic report and the final diagnosis. There was perfect agreement between the radiology report and final diagnosis ($k=1$ and $p<0.001$).

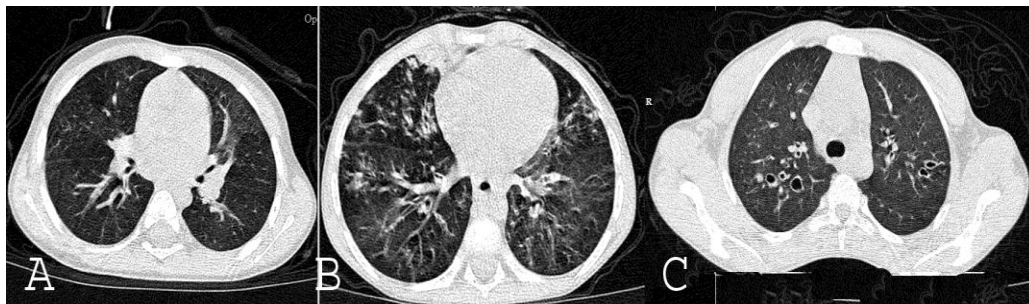


Fig. 1: Low dose CT images (KVp=90, mAs=30 & 50) in three children with diagnostic patterns. A) Image of a 3 month-old boy with HRAD presenting as generalized geographic pattern of air trapping. B) Image of 5 year old boy with HRAD having geographic pattern and tree in bud. C) Bilateral Bronchiectasis in 16 yearold boy with Cystic Fibrosis.

Table-1: Distribution of the final diagnosis of patients with low dose chest CT.

Parameters	Frequency	%
HRAD	10	22.7
PBB	9	20.4
Pneumonia	6	13.6
HP	4	9.1
Bronchiectasis	4	9.1
Chronic Bronchitis	2	4.5
SCLD	2	4.5
BPP	1	2.3
PAP	1	2.3
Pulmonary Hypoplasia	1	2.3
Pansinusitis + Chronic Bronchitis	1	2.3
Pleural Effusion + Pneumonia	1	2.3
HRAD + Sinusitis	1	2.3
FBA + Pneumonia	1	2.3
Total	44	100.0

PBB: persistent bacterial bronchitis; HRAD: hyperreactive airway disease; HP: hypersensitivity pneumonitis; BPP: bacteremic pneumococcal pneumonia; SCLD: sickle cell chronic lung disease; PAP: pulmonary alveolar proteinosis; FBA: foreign body aspiration.

4- DISCUSSION

CXR is usually known as the first imaging modality performed to diagnose chest diseases, while CT is considered as the complementary technique in equivocal conditions (16). However, CT has pitfalls which limit its utilization in pediatrics including the high costs, difficulty in availability and the risk of exposure to ionizing radiation. With increasing use of CT, considering radiation dose is crucial, as well as using innovative technologies that can decrease the risk of ionizing radiation. A study performed by Brenner et al. demonstrated that the risk of cancer due to radiation was higher in children compared with adults (17). As a substitution, thoracic ultrasound examination was proposed in the lung opacities. It can be used as a valuable modality for the differentiation of pediatric thoracic opacities with higher sensitivity than CT- scan for mass nature determination (9, 10). The aim of this study was to investigate the role of low dose CT- scan in detecting pediatric chest disease. Based on the findings of the current study, final diagnoses predicted

from the low dose chest CT were similar to the confirmed diagnoses by clinical workups. Our results suggest that the low dose CT- scan is an adequate diagnostic modality for pediatric chest diseases and it is as reliable as the confirmed diagnosis by clinical procedures. This study showed that reducing the radiation dose by providing useful information for clinical diagnosis is possible, leading to improved patient safety. Various strategies have been recommended to decrease the dose of radiation while maintaining the quality of images. In a study conducted by Colagrande et al., it was emphasized that reducing radiation dose is possible using the existing CT settings with the highest advantages by being aware of the dose needed for each patient, replacing CT with other techniques if possible and lowering the frequency of using CT in children (18). According to Nelson, through kVp, mAs, pitch, and procedures like current modulation and iterative reconstruction we are able to decrease the radiation dose (19). A study by Lambert et al. reported ultra-low dose chest CT in three cases. The aforementioned study proved that radiation

dose may be decreased by more than one order of magnitude, using the full arsenal of the CT scanner. The most significant step in lowering the radiation dose from CT scans in children hinges on the pediatricians, who should thoroughly request imaging modalities that are justified by their anticipated risk/benefit ratio (20). There are various researches on decreasing radiation dose for particular abnormal findings including pulmonary nodules (21, 22), emphysema severity (23-25), and bronchiectasis (26). Based on the studies conducted in patients with cancer using low dose CT, it was shown that diagnosis of chest problems using low dose CT was comparable to standard CT.

It was further reported that diagnostic value of low dose CT was evaluated in a broader range of goals (27-29). Takahashi et al. depicted no significant difference in the diagnostic efficacy regarding lung changes between 250 mAs and 50 mAs images (30). Mayo et al reported that 20 mAs images may also be satisfactory for understanding the chest images (31). Another study by Mayo et al. revealed a significant difference in precision of thoracic findings in 40 mAs and 100 mAs images, compared with conventional tube current images (32). This study is clinical needs based research; the numerous pediatric thoracic opacities were assigned with thoracic ultrasound examination as a diagnostic value in lung opacities. Ultrasound can be used as an appropriate imaging modality for the differentiation of pediatric thoracic opacities instead of CT-scan and even US had higher sensitivity than CT- scan for mass nature determination based our previous research (9, 10). One of the limitations of this study was sampling method. Other limitations of this study were the sample number and the fact that the results of the current study may not be obtained in case control study and due to ethical consideration, and not being a standard

CT- scan the imaging modalities were performed in each participant. Further studies with a larger sample size are recommended.

5- CONCLUSION

The current study revealed that diagnostic findings of the low dose CT-scan were comparable with clinical needs for the final diagnosis. To reduce of the radiation dose to as low as reasonably achievable, we suggest that the imaging workup of pediatric pulmonary diseases include CXR, ultrasound (for thoracic opacities) and low dose CT- scan (if necessary) are enough for clinical needs and can be used instead of CXR, and standard CT- scan protocol which results in the child being exposed to a large amount of radiation.

6- CONFLICT OF INTEREST: None.

7- REFERENCES

1. Ablin DS, Azouz EM, Jain KA. Large intrathoracic tumors in children: imaging findings. *AJR Am J Roentgenol.* 1995; 165(4):925-34.
2. Mettler FA Jr, Wiest PW, Locken JA, Kelsey CA. CT scanning: patterns of use and dose. *J RadiolProt* 2000; 20:353-59
3. Kirks DR, Griscom NT. *Practical pediatric imaging: diagnostic radiology of infants and children: 3rd ed.* Philadelphia, PA: Lippincott Williams & Wilkins; 1998.
4. Kim OH, Kim WS, Kim MJ, Jung JY, Suh JH. US in the diagnosis of pediatric chest diseases. *Radiographics.* 2000; 20(3):653-71.
5. Beer M, Ammann B. Radiological diagnostics of pediatric lungs. *Radiologe.* 2015; 55(7):554-60.
6. Partrick DA, Bensard DD, Teitelbaum DH, Geiger JD, Strouse P, Harned RK. Successful thoracoscopic lung biopsy in children utilizing preoperative CT-guided localization. *J Pediatr Surg.* 2002; 37(7):970-3; discussion -3.

7. Pearce MS, Salotti JA, Little MP, McHugh K, Lee C, Kim KP, et al. Radiation exposure from CTscans in childhood and subsequent risk of leukaemia and brain tumours: a retrospective cohort study. *Lancet*. 2012; 380:499-505.
8. Brody AS, Frush DP, Huda W, Brent RL. Radiation risk to children from computed tomography. *Pediatrics*. 2007; 120:677-82.
9. Lamah A, Seyedi SJ, Farrokh D, Lavasani S, Alamdaran SA. Diagnostic Value of Ultrasound in Detecting Causes of Pediatric Chest X-Ray Opacity. *Turk Thorac J*. 2019; 20(3): 175-81. doi: 10.5152/TurkThoracJ.2018.18087
10. Alamdaran SA, Estilae S, Farrokh D, Morovatdar N. Thoracic Mass Nature Determination; What Modality Is Better in Pediatric Age? *Int J Pediatr* 2019; 7(8): 9921-28. DOI: 10.22038/ijp.2019.39305.3349
11. Gunn ML, Kohr JR. State of the art: technologies for computed tomography dose reduction. *Emerg Radiol* 2010; 17:209-18.
12. Brenner DJ, Hall EJ. Computed tomography - an increasing source of radiation exposure. *N Engl J Med*. 2007; 357:2277-84.
13. Heyer CM, Mohr PS, Lemburg SP, Peters SA, Nicolas V. Image quality and radiation exposure at pulmonary CT angiography with 100- or 120-kVp protocol: prospective randomized study. *Radiology*. 2007; 245(2):577-83.
14. Kalra MK, Maher MM, Sahani DV, Blake MA, Hahn PF, Avinash GB. et al. Low dose CT of the abdomen: evaluation of image improvement with use of noise reduction filters pilot study. *Radiology*. 2003; 228(1):251-6. Epub 2003 May 8.
15. Diel J, Perlmutter S, Venkataramanan N, Mueller R, Lane MJ, Katz DS. Unenhanced helical CT using increased pitch for suspected renal colic: an effective technique for radiation dose reduction? *J Comput Assist Tomogr*. 2000; 24 (5):795-801.
16. Wytenbach R, Vock P, Tschäppeler H. Cross-sectional imaging with CT and/or MRI of pediatric chest tumors. *European Radiology*. 1998; 8(6):1040-6.
17. Brenner DJ, Elliston CD, Hall EJ, Berdon WE. Estimated risks of radiation-induced fatal cancer from pediatric CT. *American journal of roentgenology*. 2001; 176(2):289-96.
18. Colagrande S, Origgi D, Zatelli G, Giovagnoni A, Salerno S. CT exposure in adult and paediatric patients: a review of the mechanisms of damage, relative dose and consequent possible risks. *Radiol Med*. 2014; 119:803-810.
19. Nelson TR. Practical strategies to reduce pediatric CT radiation dose. *J Am Coll Radiol*. 2014; 11:292-299.
20. Lambert L, Banerjee R, Votruba J, El-Lababidi N, Zeman J. Ultra-low-dose CT Imaging of the Thorax: Decreasing the Radiation Dose by One Order of Magnitude. *Indian J Pediatr*. 2016; 83(12-13):1479-81.
21. Karabulut N, Toru M, Gelebek V, Gulsun M, Ariyurek OM. Comparison of low-dose and standard-dose helical CT in the evaluation of pulmonary nodules. *Eur. Radiol*. 2002; 12(11):2764-69.
22. Funama Y, Awai K, Liu D. Detection of nodules showing ground-glass opacity in the lungs at low-dose multi-detector computed tomography: phantom and clinical study. *J Comput Assist Tomogr*. 2009; 33(1):49-53.
23. Bastarrika G, Wisnivesky JP, Pueyo JC. Low-dose volumetric computed tomography for quantification of emphysema in asymptomatic smokers participating in an early lung cancer detection trial. *J Thorac Imaging*. 2009; 24(3):206-211.
24. Zaporozhan J, Ley S, Weinheimer O. Multi-detector CT of the chest: influence of dose onto quantitative evaluation of severe emphysema a simulation study. *J Comput Assist Tomogr*. 2006; 30:460-68.
25. Zompatori M, Fasano L, Mazzoli M. Spiral CT evaluation of pulmonary emphysema using a low-dose technique. *Radiol. Med*. 2002; 104:13-24.
26. Yi CA, Lee KS, Kim TS, Han D, Sung YM, Kim S. Multidetector CT of bronchiectasis: effect of radiation dose on

27. image quality. *AJR Am. J. Roentgenol.* 2003;181:501-5.
28. Chiu CH, Chern MS, Wu MH. Usefulness of low-dose spiral CT of the chest in regular follow-up of postoperative non-small cell lung cancer patients: preliminary report. *J. Thorac. Cardiovasc. Surg.* 2003;125:1300-5.
29. Dinkel H.P., Sonnenschein M., Hoppe H., Vock P. Low-dose multislice CT of the thorax in follow-up of malignant lymphoma and extrapulmonary primary tumors. *Eur. Radiol.* 2003;13:1241-49.
30. Yamada T, Ono S, Tsuboi M. Low-dose CT of the thorax in cancer follow-up. *Eur J Radiol.* 2004;51:169-74.
31. Takahashi M., Maguire W.M., Ashtari M. Low-dose spiral computed tomography of the thorax: comparison with the standard-dose technique. *Invest. Radiol.* 1998;33:68-73.
32. Mayo JR, Hartman TE, Lee KS, Primack SL, Vedal S, Muller NL. CT of the chest: minimal tube current required for good image quality with the least radiation dose. *AJR Am. J. Roentgenol.* 1995;164:603-7.
33. Mayo JR, Kim KI, MacDonald SL. Reduced radiation dose helical chest CT: effect on reader evaluation of structures and lung findings. *Radiology.* 2004;232(3):749-56.