

## Unusual Presentation of Splenogonadal Fusion in a 7-Month-Old Male Infant

Hamidreza Ghorbani<sup>1</sup>, Sina Alimohammadi<sup>2</sup>, Shirin Taraz Jamshidi<sup>3</sup>, \*Amin Mirsani<sup>1</sup>

<sup>1</sup>Kidney Transplantation Complications Research Center, Mashhad University of Medical Sciences, Mashhad, Iran. <sup>2</sup>Student Research Committee, Mashhad University of Medical Sciences, Mashhad, Iran.

<sup>3</sup>Department of Pathology, Imam Reza Hospital, Mashhad University of Medical Sciences, Mashhad, Iran.

### Abstract

**Introduction:** Splenogonadal fusion is a rare congenital anomaly characterized with anomalous fusion of the spleen and the gonad or mesonephric derivatives. Herein, we report the case of a 7-month-old boy with unusual presentation of splenogonadal fusion.

**Case Presentation:** A 7-month-old boy was brought to the Urology Clinic, Imam Reza Hospital, Mashhad, Iran, by his parents complaining of a painless palpable scrotal mass with a sudden increase in the size after a respiratory infection. The patient underwent surgery with a suspicion of testicular malignant tumors. However, pathologic study revealed a benign mass with splenic origin.

**Conclusion:** Preoperative diagnosis of splenogonadal fusion is almost impossible and most cases undergo an unnecessary orchiectomy, especially when the clinical presentation resembles a primary testicular neoplasm. Although surgery is necessary to remove the benign splenic tissue as well, proper knowledge and consideration along with appropriate imaging studies and histopathological examination contribute in avoiding an unnecessary orchiectomy.

**Key Words:** Infant, Iran, Splenogonadal fusion, Testicular neoplasm, Orchiectomy.

\*Please cite this article as Ghorbani H, Alimohammadi s, Taraz Jamshidi Sh, Mirsani A. Unusual Presentation of Splenogonadal Fusion in a 7-Month-Old Male Infant. Int J Pediatr 2020; 8(2): 10905-910. DOI: **10.22038/ijp.2019.41498.3499**

---

### \*Corresponding Author:

Amin Mirsani, M.D, Kidney Transplantation Complications Research Center, Mashhad University of Medical Sciences, Mashhad, Iran.

Email: mirsania941@mums.ac.ir

Received date: Nov.20, 2019; Accepted date: Jan.12, 2020

## 1- INTRODUCTION

Splenogonadal fusion is a rare congenital abnormality in which there is an anomalous connection between the spleen and the gonad or mesonephric derivatives. Although the exact cause of this condition is yet to be known, it is assumed that a developmental defect with abnormal migration of spleen cells that occurs during the 5<sup>th</sup>-8<sup>th</sup> week of gestation might be the cause (1). The discovery of this anomaly dates back to the late 19<sup>th</sup> century, when Eugen Bostroem first defined the term in a report in 1883 in Germany. Later it was characterized by a detailed description by Pommer in 1889 in Germany.

After more than half a century, Putschar and Manion in their review of 30 cases that was published in 1956, categorized splenogonadal fusion into two distinct and well-described types of continuous and discontinuous. In the continuous type, fibrotic tissue or a splenic cord connects the ectopic gonad to the spleen. However, in the discontinuous type, there is no connection between the ectopic spleen and the abdominal spleen (2, 3). Many cases have been reported since the anomaly was first described, with the latest ones being reported from the United States, France, and Iraq (4-6). Herein, we report the case of a 7-month-old boy with splenogonadal fusion presenting with a painless palpable scrotal mass and a sudden increase in the size.

## 2- CASE REPORTS

A 7-month-old male infant with no past medical history was brought to the Urology Clinic, Imam Reza Hospital, Mashhad, Iran, for a painless palpable mass in his left hemiscrotum. The parents gave a history of a small palpable mass in the left testis since the neonatal period. They referred to the clinic for a sudden increase in the size of the scrotal mass after a period of upper respiratory tract infection (URTI). The patient had no

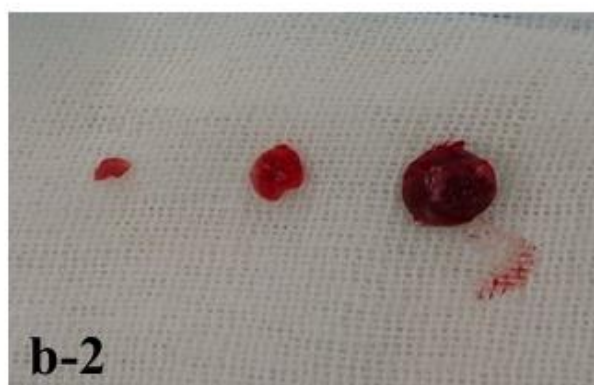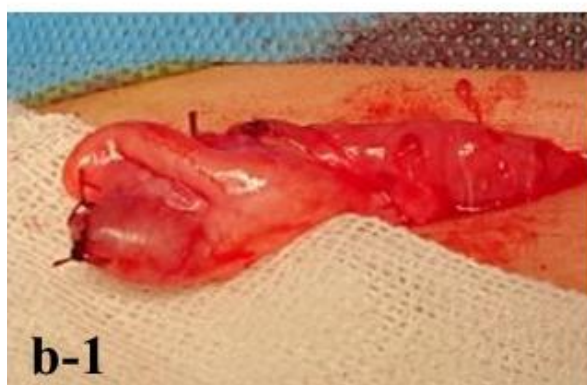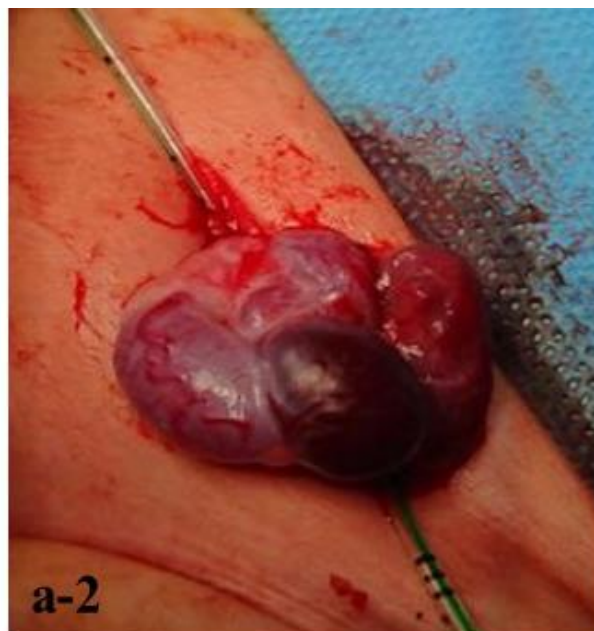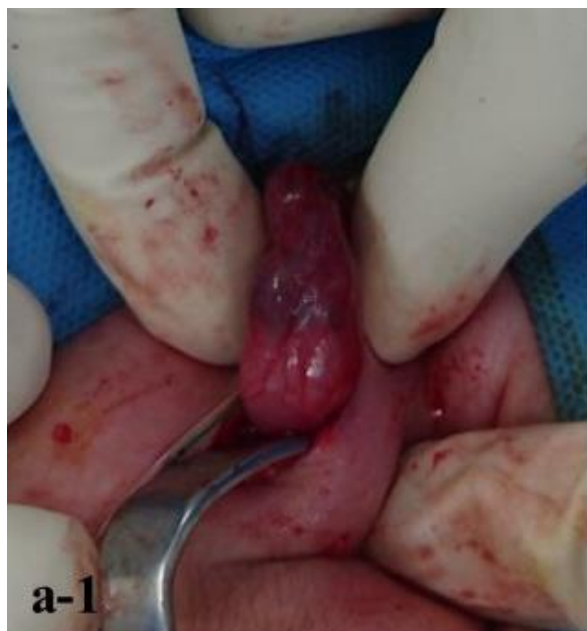history of other risk factors including cryptorchidism and had negative family history of testicular cancers. Surgical history was negative and his developmental status was normal for his age. On physical examination, both testes were descended into the scrotum. We found a hard mass that was totally attached to the upper pole of the left testis. There were no signs of hydrocele, inguinal and supraclavicular lymphadenopathy, or scrotal inflammation. Routine blood tests were normal. Tumor marker assays showed a high serum alpha-fetoprotein concentration (30.2 ng/ml) that can be considered normal for this age, while serum levels of his human chorionic gonadotropin (hCG), and lactate dehydrogenase (LDH) were within normal limits. Scrotal ultrasound showed two side-by-side homogeneous oval foci in the left side scrotum, sized 7\*12cm and 6\*11cm.

Both masses were capsular and brought up the differential diagnoses of testicular tumors and polyorchidism. Left testis was delivered under general anesthesia using left inguinal incision and temporary clamping of the cord in the proximal part. A firm mass with well-defined margins appeared on the upper pole of left testis with a firm adhesion to the testis, which was excised completely.

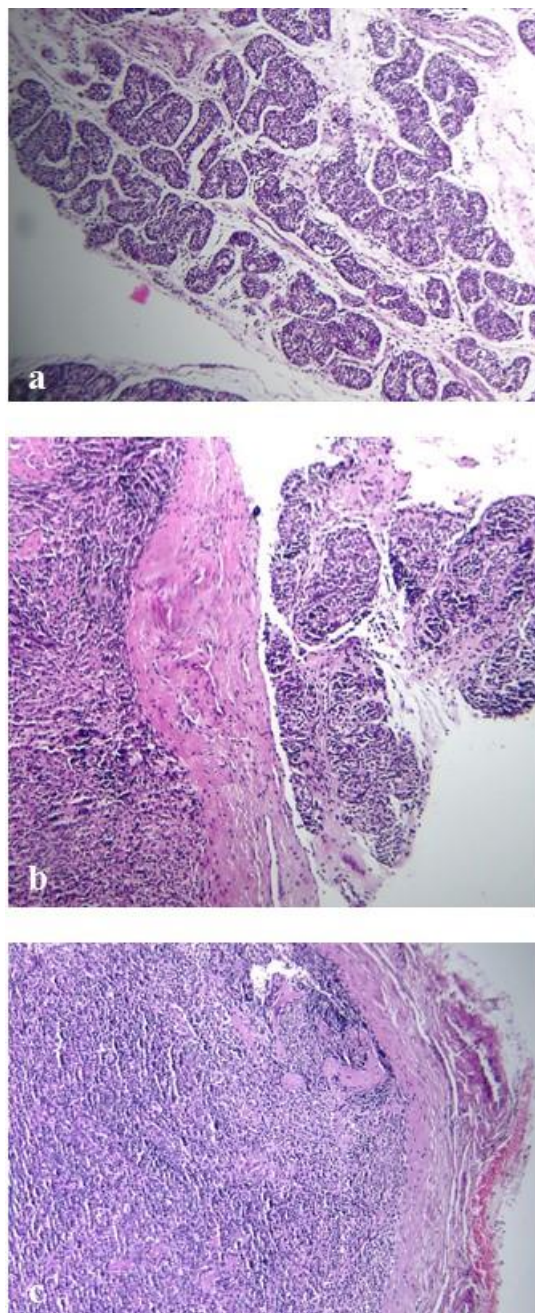
A histological section from the margins of the mass was sent for frozen section study, which turned out to be compatible with lymphoproliferative tumors, most probably lymphoma. We therefore decided to preserve the testis. Clamp was removed, tunica albuginea was repaired, and the left testis was pulled down into the scrotum (**Figure.1**). The patient was discharged one day after the operation in good condition. Further histopathological examination of the operative specimen by an expert pathologist revealed neither a benign nor a malignant tumor and confirmed the presence of regular splenic tissue in the suspected mass, which

comprised a white pulp with germinal

centers of lymphoid follicles (**Figure.2**).



**Fig.1:** (a-1) The left testis presenting with a mass on the superior pole, delivered via an inguinal section; (a-2) The left testis with the mass, before excision (partial orchiectomy); (b-1) The remaining left testis after excision of the mass (partial orchiectomy); (b-2) The excised mass with the excised surgical margin.



**Fig.2:** Histopathologic view of the excised mass: (a) Immature seminiferous tubules of testis; (b) Splenogonadal fusion site; (c) Normal splenic tissue.

### 3- DISCUSSION

Splenogonadal fusion is a rare congenital anomaly, mostly diagnosed in adolescents and young adults. Around 200 cases of splenogonadal fusion have been reported since its first description by Bostroem in 1883 (3). In 82% of the reported cases, the age of presentation has been less than 30 years and half of the

cases occurred in patients below 10 years (3). However, our case was a 7-month-old infant. Splenogonadal fusion usually presents as a left testicular swelling, a scrotal mass, or cryptorchidism (7). This condition does not exclusively occur in male patients. It is commonly underdiagnosed in female patients because ovaries are less exposed to physical examination (8). Association with

malignancy has been rarely reported but there is a possibility of testicular cancer in cases that splenogonadal fusion is associated with cryptorchidism (9). The continuous type of splenogonadal fusion can be accompanied by other terminal limb deformities, a condition that is called splenogonadal fusion limb defect syndrome. This syndrome includes a variety of defects such as cleft palate, micrognathia, bifid uvula, mandibular hypoplasia, diaphragmatic hernia, cryptorchidism, inguinal hernia, anal atresia and cardiac defects (10).

The discontinuous form may present as a testicular mass with distinct ultrasound features including a partly hyperechoic mass with multiple hypoechoic nodules and apparent vascularity (11). Single photon emission computed tomography (SPECT) with Technetium  $^{99m}$ Tc sulfur colloid for spleen detection could be used to clarify the diagnosis (12). Splenogonadal fusion is mostly an incidental finding detected during surgical repair of inguinal hernia or orchidopexy. Clinical diagnosis of splenogonadal fusion is usually beyond the bounds of possibility and it is mostly diagnosed through histopathologic examination (3, 7, 9).

In our patient, neither cryptorchidism nor hernia, which are predominantly associated with splenogonadal fusion, was seen. Our case, unlike the typical presentation of splenogonadal fusion that is asymptomatic, had a palpable testicular mass with a sudden increase in size after a URTI. The coincidence of this sudden enlargement of the testicular mass with the presence of a URTI might be due to the immunologic activities of the splenic tissue, causing an immune reaction in response to the viral or bacterial respiratory infection. Ferrón et al. had reported a somehow similar presentation of splenogonadal fusion in a 2-year-old boy who presented with a history of an asymptomatic scrotal mass that led to an

increase in scrotal size over a 2-month period, during which the patient had a viral URTI (11). Due to the lack of proper knowledge about preoperative diagnosis of splenogonadal fusion, most cases undergo an unnecessary orchiectomy, especially when the clinical presentation resembles a primary testicular neoplasm (13).

#### 4- CONCLUSION

Although surgery is necessary despite the benign nature of splenogonadal fusion, appropriate imaging studies, and histopathological examination contribute in preventing an unnecessary orchiectomy. This study provides useful insights into the presentation of splenogonadal fusion and helps surgeons to consider it as a possible differential diagnosis with benign nature when facing a testicular mass in infants and children to make better decisions.

**5- CONFLICT OF INTEREST:** None.

#### 6- REFERENCES

1. Barthold J, Hagerty J. Etiology, Diagnosis, and Management of the Undescended Testis. In: Campbell-Walsh Urology. Wein A, Kavoussi L, Partin A, Peters C editors. 11<sup>th</sup>ed. Elsevier; 2016; Vol4 part XV p.148.3443.
2. Lin CS, Lazarowicz JL, Allan RW, MacLennan GT. Splenogonadal fusion. J Urol. 2010; 184(1):332-3.
3. Khairat AB, Ismail AM. Splenogonadal fusion: case presentation and literature review. J Pediatr Surg. 2005; 40: 1357–60.
4. Chen CJ, Kavoussi N, Jacobs MA. Splenogonadal fusion: A rare finding during routine orchiopexy. Urology Case Reports. 2019 May 7:100904.
5. Karpathiou G, Chauleur C, Mehdi A, Peoc'h M. Splenic tissue in the ovary: splenosis, accessory spleen or spleno-gonadal fusion? Pathology-Research and Practice. 2019 Jul 17:152546.
6. Hassan MA, Gatea HK, Thura K, Fahad AO. Splenogonadal fusion presenting as a

scrotal mass. *Journal of Pediatric Surgery Case Reports*. 2019; 43: 5-7.

7. Varga I, Babala J, Kachlik D. Anatomic variations of the spleen: current state of terminology, classification, and embryological background. *Surg Radiol Anat*. 2018; 40(1):21-29.

8. Bhatt S, Rubens DJ, Dogra VS. Sonography of benign intrascrotal lesions. *Ultrasound Q*. 2006; 22:121-36.

9. Lopes RI, de Medeiros MT, Arap MA, Cocuzza M, Srougi M, Hallak J. Splenogonadal fusion and testicular cancer: case report and review of the literature. *Einstein (São Paulo)*. 2012; 10: 92-5.

10. McPherson F, Frias JL, Spicer D, Opitz JM, Gilbert-Barness EF. Splenogonadal fusion-limb defect “syndrome” and associated malformations. *Am J Med Genet*. 2003; 120A: 518-22.

11. Ferron SA, Arce JD. Discontinuous splenogonadal fusion: new sonographic findings. *Pediatr Radiol* 2013; 43: 1652-55.

12. Steinmetz AP, Rappaport A, Nikolov G, Priel IE, Chamovitz DL, Dolev E. Splenogonadal fusion diagnosed by spleen scintigraphy. *J Nucl Med*. 1997; 38: 1153-55.

13. Mann JA, Ritchie E. Splenogonadal fusion: A case of two lesions. *Urol Case Rep*. 2019; 24: 100878.