

Ultrasound Guided Hydrostatic Treatment of Meconium Ileus; another Indication for Ultrasound Based Approach to Bowel Obstruction

*Seyed Ali Alamdaran¹, Ahmad Mohammadipour², Ali Azadmand², Reza Shojaeian², Halime sadat Arabi Moghadam¹

¹MD, Department of Radiology, Faculty of Medicine, Mashhad University of Medical Sciences, Mashhad, Iran.

²MD, Department of Pediatric Surgery, Faculty of Medicine, Mashhad University of Medical Sciences, Mashhad, Iran.

Dear Editor-in-Chief,

The inspissated meconium pellets are a cause or effect of ileocolic obstructions. The present study aimed at explaining our experience of ultrasound-based approach for differentiation and treatment of the inspissated meconium pellets. This study was conducted at Mashhad University of Medical Sciences, Mashhad, Iran, from 2017-2020. Twenty-four neonates (less than 8 days) with inspissated meconium pellets were examined using ultrasound. Moreover, in cases with non-complicated inspissated meconium pellets, ultrasound-guided contrast enema was performed for confirmation of the diagnosis or probable treatment. In ultrasound, the inspissated meconium pellets were observed as uniform hypo- to hyper-echoic tubular or beaded intra-luminal material in ileocolic loops or recto-sigmoid area. These pellets were in five states: simple meconium ileus, localized or generalized meconium, small bowel, meconium plug syndrome, and Hirschsprung's disease.

During contrast enema in non-complicated meconium ileus, moving and floating of inspissated meconium pellets was observed during ultrasound scanning, while this issue was not observed in small bowel atresia. The success rates of the hypertonic contrast enema in patients with simple meconium ileus were 80%. The inspissated meconium pellets have an ultrasound appearance. They are mainly observed in patients with simple and complicated meconium obstructions and bowel atresia. Except in complicated meconium obstructions, the ultrasound-guided contrast enema was performed for their differentiation and probable treatment.

Key Words: Meconium ileus, Treatment, Ultrasound.

*Please cite this article as: Alamdaran SA, Mohammadipour A, Azadmand A, Shojaeian R, Arabi Moghadam HS. Ultrasound Guided Hydrostatic Treatment of Meconium Ileus; another Indication for Ultrasound Based Approach to Bowel Obstruction. Int J Pediatr 2020; 8(8): 11737-742. DOI: [10.22038/ijp.2020.46731.3791](https://doi.org/10.22038/ijp.2020.46731.3791)

*Corresponding Author:

Seyed Ali Alamdaran (MD, MSc) Department of Radiology, Faculty of Medicine, Mashhad University of Medical Sciences, Mashhad, Iran.

Email: Alamdarana@mums.ac.ir

Received date: Feb.23, 2020; Accepted date: Apr. 22, 2020

We have continued the study entitled "Ultrasound-guided Hydrostatic (Hydro-colonic) Treatment of Meconium Ileus: A Preliminary Report" by Alamdaran et al. (1). We updated the mentioned study and added some commentary to it. Hypertrophic Pyloric Stenosis (HPS), malrotation, bowel atresia, and masses are the common causes of bowel obstruction, that have known specific ultrasound findings; Thick muscle, displacement mesenteric vessels in malrotation, whirlpool sign in volvulus and micro-colon associated with empty collapsed small bowel in Right Lower Quadrant (RLQ) in bowel atresia were observed in HPS. The inspissated meconium pellets are another cause or effect of ileocolic obstructions. In meconium ileus, they stick in the terminal ileum and meconium plug syndrome or small left colon syndrome, therefore, they obstruct the descending colon. These both are treated medically using the hyperosmolar gastrografin contrast enema (2).

If inspissation would be complicated by bowel perforation and meconium peritonitis, they need a surgical approach (3, 4). Afterward, differentiation of those from one another and other surgical causes such as bowel atresia is important. The present study aimed at presenting sonographic results of meconium obstructions and diagnostic pitfalls. Moreover, the ultrasound-guided approach for differentiation and treatment of the inspissated meconium pellets were explained. This cross-sectional study was performed at Mashhad University of Medical Sciences from 2017-2020 in Dr. Sheikh and Akbar pediatric hospitals. All neonates (2-8 days) with non-passage of meconium were examined using the ultrasound to observe the causes of

intestinal obstruction. The anorectal malformations were excluded from the study. Twenty-five neonates were found with inspissated meconium pellets. In cases with the signs of non-complicated inspissated meconium pellets, ultrasound-guided contrast enema was performed for confirmation of the diagnosis or probable treatment. Plain abdominal x-ray after ultrasound-guided contrast enema was carried out to ensure the achievement of the contrast media to dilate the proximal loop.

The Meconium Pellets and the Causes

In ultrasound, the inspissated meconium pellets were observed as uniform hypo-until hyper-echoic tubular or beaded intraluminal material in ileocolic loops or recto-sigmoid area. Sometimes, punctate echogenic foci are observed in the central or peripheral section of meconium pellets (**Figure.1**). The transverse diameter of loops containing meconium is equal (<1 cm). The involved loops vary from 2-3 to numerous. The sonographic soap bubble sign was observed as floating air bubbles in viscous fluids of the proximal dilated loops and no air was observed in small involved loops containing inspissated meconium. These pellets were observed in five states: simple meconium ileus (10 cases), localized or generalized meconium peritonitis (7 cases), small bowel atresia (Ileal with 3 cases and jejunal with 2 cases), meconium plug syndrome (2 cases), and Hirschsprung's disease (1case). Consequently, the meconium pellets were also observed in small bowel atresia cases according to the results of the ultrasound examination and it can lead to misdiagnosis and probable complications. This finding may be due to late-atresia in pregnancy or after meconium formation.

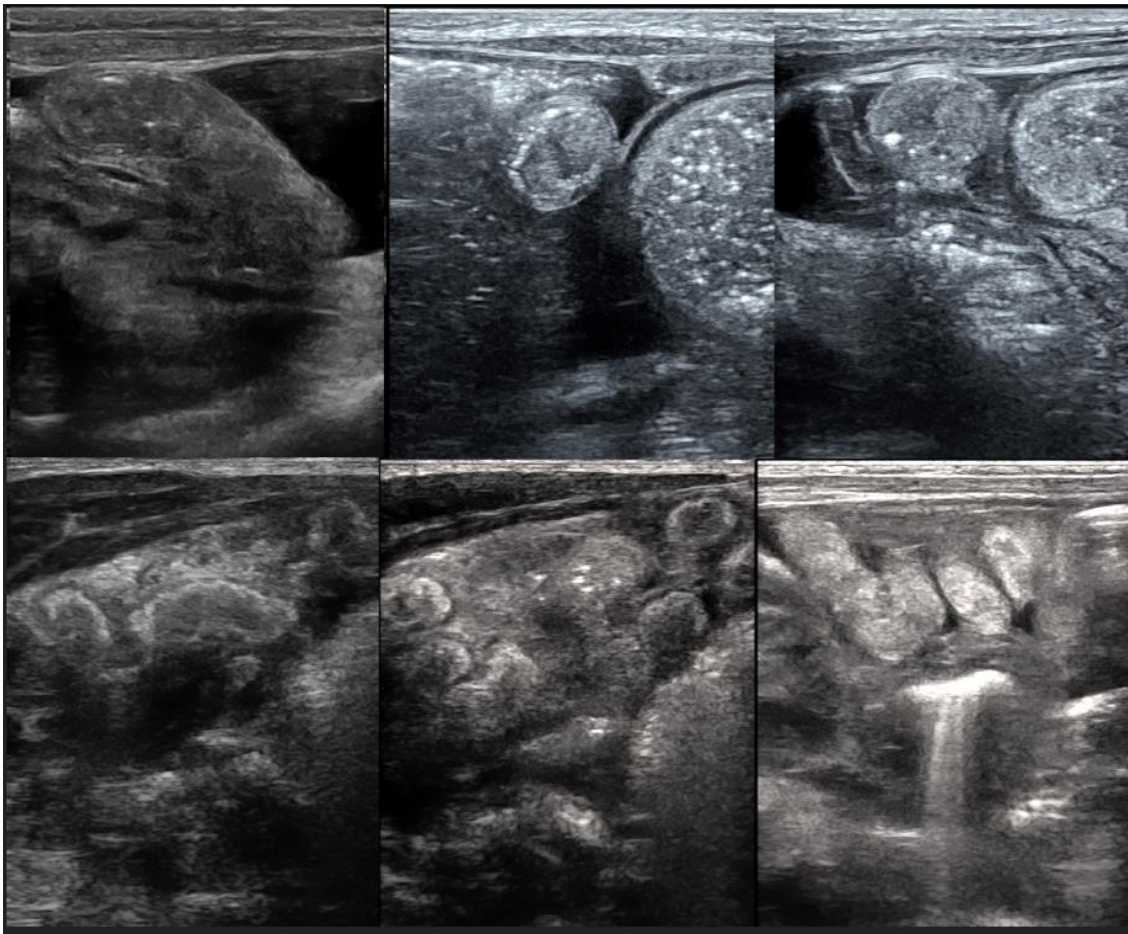


Fig.1: The inspissated meconium pellets in ileocolic loops as uniform hypo- to hyper-echoic tubular or beaded intra-luminal material are associated with punctate echogenic foci in some meconium pellets.

Differentiation of Various Causes of Meconium Pellets using the Ultrasound:

Diagnosis of the localized or generalized meconium peritonitis using the ultrasound is straightforward. In addition to inspissated meconium pellets in *RLQ*, the free peritoneal fluid with tumefactive debris was observed in generalized meconium peritonitis (**Figure.2A**). Visualization inspissated meconium pellets in *RLQ* associated with a dirty collection with the well-circumscribed and occasionally calcified wall was observed in localized meconium peritonitis (**Figure. 2B, 2C**). Retention of inspissated meconium in the recto-sigmoid and occasionally left colon is matched with meconium plug syndrome and Hirschsprung's disease. Occasionally,

meconium content in recto-sigmoid was observed in complicated meconium ileus cases (**Figure.3**). Visualization of inspissated meconium pellets in *RLQ* and ileocolic loops are suggested simple meconium ileus or small bowel atresia and differentiation of them using the simple ultrasound examination is impossible now. The radiographic and sonographic "soap bubble" signs were observed in both of these two cases and so that there is no distinction between them in this regard. It is worth noting that in most bowel atresia cases, sonographic findings are diagnostic; the usual appearance of them is as dilated proximal loops associated with the number of collapsed empty small bowel in *RLQ* (3, 4). The diagnostic problem arises when inspissated meconium pellets are present in cases of intestinal atresia.

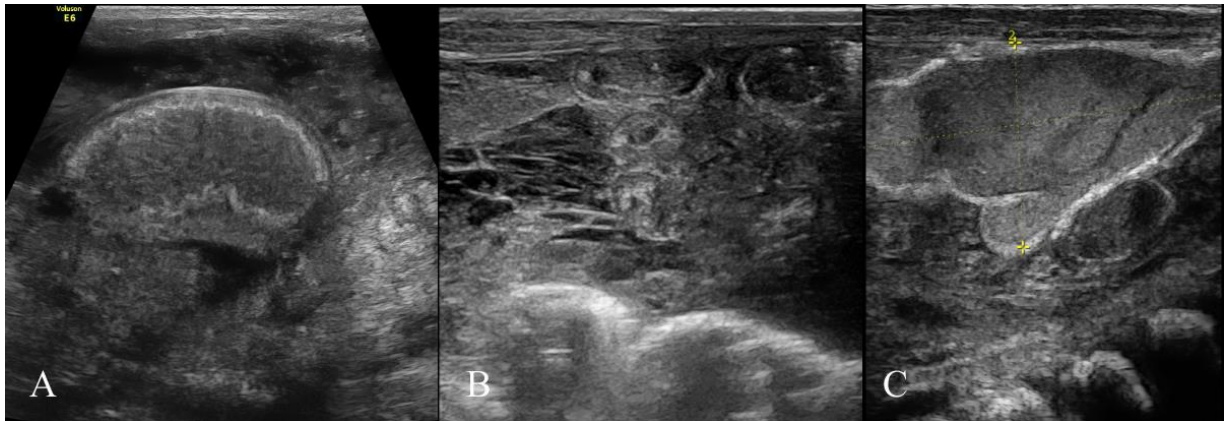


Fig.2: Three cases with localized or generalized meconium peritonitis participated in the study including A) inspissated meconium pellets in the small bowel and free peritoneal fluid with tumefactive debris in meconium peritonitis B) meconium pellets in small bowel associated with septation and organization in the peritoneal cavity in a case with old meconium peritonitis. C) A collection with a well-circumscribed calcified wall in localized meconium peritonitis.

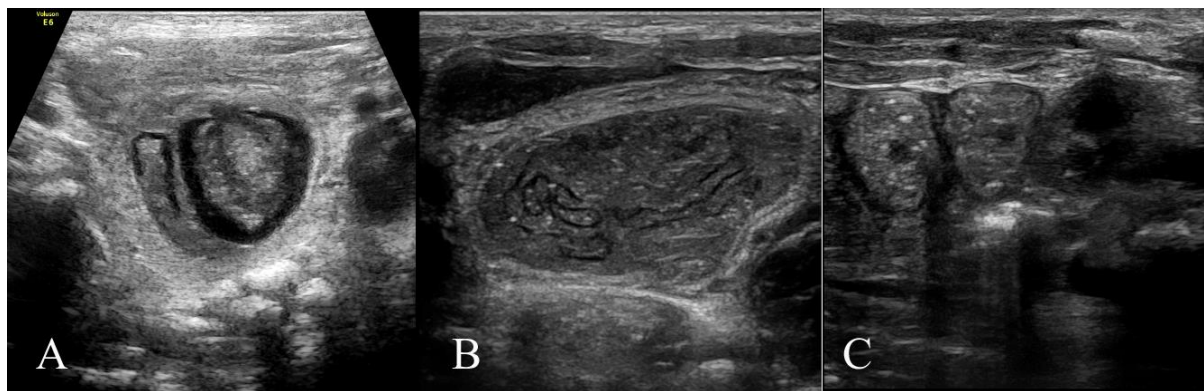


Fig.3: Retention of meconium in the left colon in small left colon syndrome (A) and recto-sigmoid area Hirschsprung's disease (B and C).

Ultrasound-Guided Contrast Enema

Except in patients with localized or generalized meconium peritonitis, ultrasound-guided contrast enema was performed for confirmation of the diagnosis or probably treatment of medical cases with inspissated meconium pellets. During contrast enema, displacement and floating of inspissated meconium pellets were observed in cases with simple meconium ileus (**Figure. 4**), while there this issue was not observed in small bowel

atresia. Afterward, if the meconium pellets do not move to the proximal part of bowels during treatment with appropriate pressure (in all stages of the enema contrast, the syringe piston moves at low pressure), there is a possibility of small bowel atresia and no further effort should be made to reduction. The success rate of the hypertonic contrast enema in patients with simple meconium ileus was 80%, which was the highest reported success rate among the literature (5).

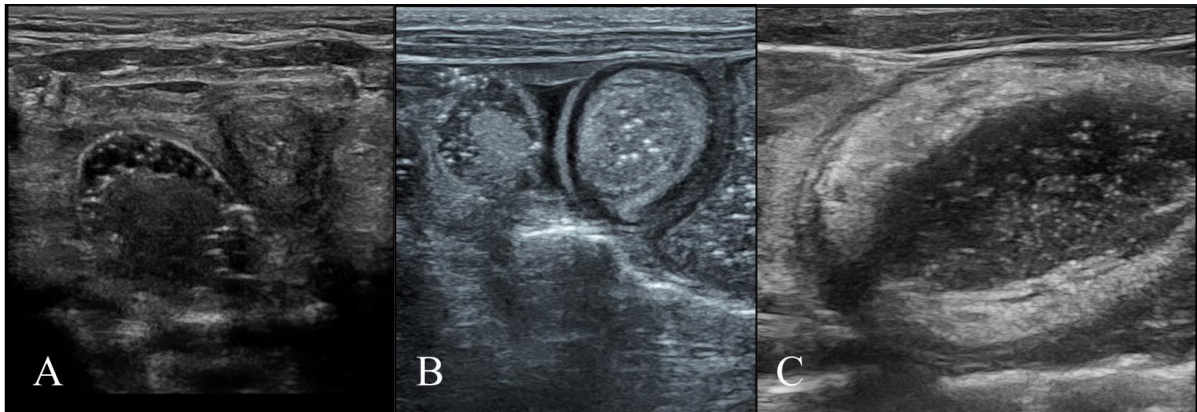


Fig.4: Floating of inspissated meconium pellets during contrast enema and reaching of contrast media to the center of dilated proximal loop in simple meconium ileus case.

In addition, the obstruction was relieved in three cases of meconium plug syndrome and Hirschsprung's disease. Stone-like the consistency of meconium in one patient and misdiagnosis of successful treatment in another were the causes of un-success.

Then, we suggest the usage of the plain abdominal x-ray after ultrasound-guided contrast enema, which could be a reliable method to reach the contrast media to dilate the proximal loop (**Figure. 5**).

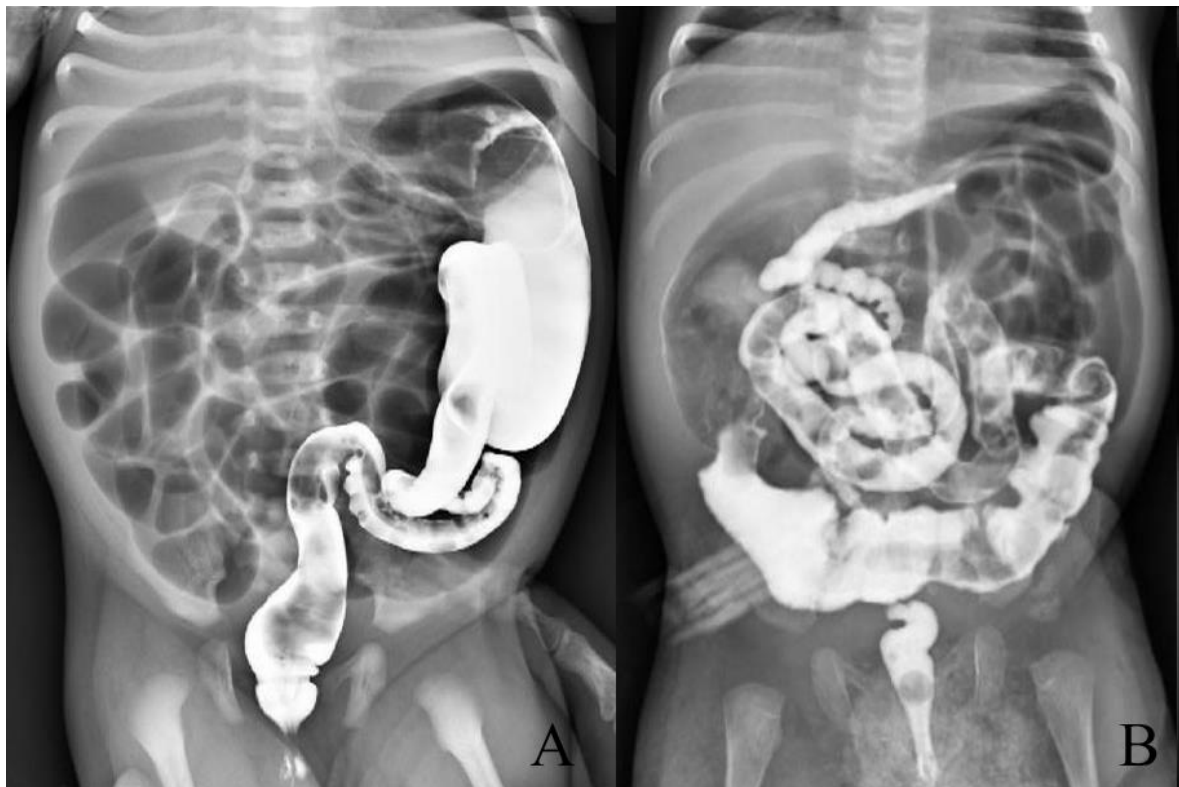


Fig. 5. The plain abdominal X-ray after ultrasound-guided contrast enema show to reach the contrast media to dilated proximal loop; A) meconium pellets in small left colon syndrome. B) Narrow unused colon and terminal ileum contain meconium pellets in meconium ileus and reaching of contrast media to proximal dilated loop.

We emphasize that visualization of inspissated meconium pellets in ileocolic area was observed in both simple meconium ileus and small bowel atresia. The treatment in one patient with bowel atresia (it had been wrongly diagnosed as simple meconium ileus) led to colonic perforation. Lack of consideration of this point and traumatization due to rectal tube led to perforation as complication of this technique. Usage of Foley catheter with deflated balloon and application of manometry during contrast enema can lead to adequate determination of pressure for treatment and prevention from complication. Although hypertonic reduction was successful in two 7- and 8 days old neonate with meconium ileus, but over time and increased abdominal distention, the risk of bowel necrosis was increased. Therefore, the iteration of this non-respond to therapy needs after 48h is suggested for further research.

CONCLUSION

In addition to specific ultrasound patterns of some causes of bowel obstruction such as whirlpool sign in volvulus, HPS, and intussusception, the inspissated meconium pellets as another cause of ileocolic obstructions have an ultrasound characteristic and appearance. They could be observed in patients with simple and complicated meconium obstructions, bowel atresia, meconium plug syndrome, and Hirschsprung's disease. The distinction between various causes of meconium pellets using ultrasound is often straightforward. In cases with the signs of non-complicated inspissated meconium pellets, ultrasound-guided contrast enema could be carried out to observe their differentiation and probable treatment. The success rate of the hypertonic contrast enema in patients with simple meconium ileus was 80%.

CONFLICT OF INTEREST: None.

ACKNOWLEDGMENTS

The authors wish to thank the staff of radiology, surgery and NICU departments of Akbar and Dr. Sheikh hospitals. This study was supported in part by granting Dr. Alamdaran from the deputy for research of Mashhad University of Medical Sciences.

REFERENCES

1. Alamdaran SA, Mohamadipour A, Joodi M, Shojaeen R, Khademi Gh, Jafari SA, et al. Ultrasound-guided Hydrostatic (Hydrocolonic) Treatment of Meconium Ileus: A Preliminary Report. *Int J Pediatr* 2018; 6(8): 8111-18
2. Burke MS, Ragi JM, Karamanoukian HL, Kotter M, Brisseau GF, Borowitz DS, et al. New strategies in nonoperative management of meconium ileus. *J Pediatr Surg.* 2002; 37(5):760-4.
3. Alamdaran SA, Davoudi Y, Ahmadi S, Khademi GR, Ataee A. Is Meconium Obstruction Distinguishable from Intestinal Obstruction through Ultrasound? *Iranian Journal of Neonatology.* 2019; 10(1). DOI: 10.22038/ijn.2018.30639.1420.
4. Neal MR, Seibert JJ, Vanderzalm T, Wagner CW. Neonatal ultrasonography to distinguish between meconium ileus and ileal atresia. *J Ultrasound Med.* 1997; 16(4):263-6.
5. Karimi A1, Gorter RR, Sleeboom C, Kneepkens CM, Heij HA. Issues in the management of simple and complex meconium ileus. *PediatrSurg Int.* 2011 Sep; 27(9): 963-68.