



# Primary Spontaneous Pneumothorax: Open Thoracotomy vs. Video-assisted Thoracoscopic Surgery: A Single-center Retrospective Cohort Study

Saadat Mehrabi<sup>1</sup>, MD;  Mohammad Behgam Shadmehr<sup>2</sup>, MD;  Cambyz Irajie<sup>3</sup>, MD, PhD, MPH; Mohammad Javad Yavari Barhaghtalab<sup>1</sup>, MD, MPH 

<sup>1</sup>Department of General Surgery, Shahid Beheshti Hospital, Yasuj University of Medical Sciences, Yasuj, Iran;

<sup>2</sup>Department of Thoracic Surgery, Tracheal Diseases Research Center, Massih Daneshvari Hospital, Shahid Beheshti University of Medical Sciences, Tehran, Iran;

<sup>3</sup>Department of Medical Biotechnology, School of Advanced Medical Sciences and Technologies, Shiraz University of Medical Sciences, Shiraz, Iran

## Correspondence:

Mohammad Behgam Shadmehr, MD; Department of Thoracic Surgery, Tracheal Diseases Research Center, Massih Daneshvari Hospital, Shahid Bahonar Ave., Darabad, Postal code: 19569-44413, Tehran, Iran

Tel: +98 21 88885343

Fax: +98 21 26105387

Email: mbshadmehr@sbmu.ac.ir

Mohammad Javad Yavari Barhaghtalab, MD, MPH;

Department of General Surgery, Shahid Beheshti Hospital, Yasuj University of Medical Sciences, Shahid Montazeri St., Postal code: 75917-94857, Yasuj, Iran

Tel: +98 74 33221813

Fax: +98 74 332218111

Email: mj.yavari.barhaghtalab@yums.ac.ir

Received: 09 June 2021

Revised: 19 October 2021

Accepted: 06 November 2021

## What's Known

- According to the new improvements in the management of spontaneous pneumothorax, video-assisted thoracoscopic surgery (VATS) is safer, more effective, and less invasive. However, the conventional technique is the open thoracotomy method with bullectomy and pleurectomy.

## What's New

- VATS could be the primary treatment option in the surgical treatment of primary spontaneous pneumothorax when compared to open thoracotomy, due to the shorter length of surgery as well as the length of hospital stay and decreased complications such as air leakage and recurrence.

## Abstract

**Background:** Primary spontaneous pneumothorax (PSP) is a spontaneous pneumothorax without underlying lung disease. The main goals of this study were to compare the outcomes of video-assisted thoracoscopic surgery (VATS) and open thoracotomy in patients with PSP.

**Methods:** The current study is a retrospective cohort study of patients who were admitted to the emergency department or general surgery ward at Dr. Masih Daneshvari Hospital (Tehran, Iran) with the diagnosis of PSP and underwent surgery by open or VATS approach from 2006 to 2012. The groups were compared in terms of the length of operation, the length of hospitalization, recurrence, and postoperative complications. Data were analyzed using SPSS version 18.0, and Student's *t* test, analysis of variance (ANOVA), Chi square, and Fisher's exact test were employed. P values less than 0.05 were considered statistically significant.

**Results:** PSP was diagnosed in 90 patients who underwent surgery. Open thoracotomy and VATS procedures were performed in 65 (72.2%) and 25 (27.8%) patients, respectively. VATS was converted to open in seven cases (7.7%). Recurrent pneumothorax was the most common surgical indication for PSP. There was no significant difference between the two groups in terms of mean age, sex, smoking, side of the involved lung, previous pneumothorax history, mean length of hospitalization for recurrence, post-operation bleeding, and failure of lung expansion. However, the length of surgery ( $P=0.011$ ) and air leakage ( $P=0.048$ ) significantly differed between the two groups.

**Conclusion:** When compared to open thoracotomy, VATS could be the primary treatment option in the surgical treatment of PSP due to the shorter length of surgery and decreased complications such as air leakage.

Please cite this article as: Mehrabi S, Shadmehr MB, Irajie C, Yavari Barhaghtalab MJ. Primary Spontaneous Pneumothorax: Open Thoracotomy vs. Video-assisted Thoracoscopic Surgery: A Single-center Retrospective Cohort Study. Iran J Med Sci. 2023;48(1):49-56. doi: 10.30476/ijms.2022.91422.2260.

**Keywords** • Pneumothorax • Thoracotomy • Surgery • Video-assisted

## Introduction

Primary and secondary spontaneous pneumothorax is caused by the intrinsic abnormalities of the lung and can occur without any prior trauma history or the apparent precipitating factors.<sup>1</sup> Primary spontaneous pneumothorax (PSP) occurs when there is no

underlying lung disease (normal lung), whereas secondary spontaneous pneumothorax (SSP) occurs when there is underlying lung disease such as emphysema (rupture of a bleb or bulla), cystic fibrosis, and acquired immunodeficiency syndrome (AIDS), metastatic cancer (especially sarcoma), asthma, lung abscess, occasionally lung cancer, and Catamenial pneumothorax.<sup>1,2</sup> The most common cause is apical subpleural bleb rupture. These blebs are commonly seen in tall thin and young male smokers. However, the causes are still unknown.<sup>1,2</sup>

The first step in treatment is simple needle aspiration of the trapped air from the pleural space or draining the air via chest tubes with a water seal.<sup>1,3-5</sup> The second step is to stop air leakage and prevent recurrences through surgical interference or chemical pleurodesis.<sup>1,2</sup> According to the consensus statement of the American College of Chest Physicians (ACCP), indications for surgical treatment of spontaneous pneumothorax include persistent air leakage for more than four days, failure of the lung to expand after chest tube drainage (CTD), recurrent pneumothorax, synchronous bilateral pneumothorax, hemopneumothorax, tension pneumothorax, and high-risk occupational groups such as pilots and divers with the first spontaneous pneumothorax.<sup>6-9</sup> The closure of the air leak, pleurodesis, partial pleurectomy, pleural abrasion, bullectomy, lung resection through VATS, axillary mini-thoracotomy (AMT), and formal anterolateral or posterolateral thoracotomy are some of the surgical procedures used to treat PSP that are associated with the disease course and progression.<sup>1,3,9</sup>

According to the new developments in the management of spontaneous pneumothorax,<sup>10</sup> video-assisted thoracoscopic surgery (VATS) is safer, more effective, and less invasive. However, the conventional technique is the open thoracotomy method with bullectomy and pleurectomy.<sup>3</sup>

In order to reduce pneumothorax recurrence, it is often recommended to combine pleurodesis with bullectomy. Scratching, abrasion, and partial or semi-total pleurectomy are some methods for surgical pleurodesis. Several chemical agents, such as talc, tetracycline, minocycline, povidone-iodine, autologous blood, and dextrose have been described for the chemical pleurodesis. Nevertheless, no technique or agent could guarantee with absolute certainty that a recurrence would not occur in the future.<sup>11,12</sup>

Although there are some studies, similar to ours, that retrospectively compared VATS and open thoracotomy in the treatment of PSP,<sup>13-15</sup> there are some controversies over the best

method to treat a spontaneous pneumothorax.<sup>11</sup> This study aims to compare the outcomes of PSP patients treated with VATS and open conventional thoracotomy procedures and evaluate their advantages over one another in terms of the length of the procedure, post-operation length of hospitalization, recurrence, and complications. In addition, the strength of the current study, when compared to previous matched studies, lies in the examination of the patients based on a more comprehensive initial value.

## Patients and Methods

The present research is a historical cohort study that was conducted from January 2006 to December 2012 at the emergency department or general surgery ward at Dr. Masih Daneshvari Hospital, affiliated with Shahid Beheshti University of Medical Sciences (Tehran, Iran). The study was approved by the Research Ethics Committee of Shahid Beheshti University of Medical Sciences (code: IR.SBUMS.REC.1392.665). Ninety patients with the diagnosis of PSP who were admitted to the emergency department or general surgery ward at Dr. Masih Daneshvari Hospital and underwent surgery by open or VATS approach were included in the current study. Written informed consent was obtained from all the participants before the interview and physical examination. All the patients' records were carefully reviewed retrospectively, and the patients were evaluated prospectively at the surgical clinic. The inclusion criteria were ipsilateral relapse after an episode of PSP treated with CTD and persistent air leakage of more than four days after placing a CTD in the first episode of pneumothorax. The exclusion criteria included secondary spontaneous pneumothorax, iatrogenic and traumatic pneumothorax, and pre-existing pulmonary disease. All methods were carried out by relevant guidelines and regulations. The study was carried out in accordance with the principles of the Helsinki Declaration and was compatible with the methodology of previous similar studies.<sup>13-15</sup>

The primary treatment of PSP performed in our hospital was a simple aspiration or CTD. Failure in simple aspiration, also known as CTD, was defined as persistent air leaks or pneumothoraces that failed to resolve after single or repeated aspiration; VATS or open thoracotomy was selected as the secondary treatment. The patients were divided into two separate groups. 25 patients (Group 1) underwent open thoracotomy, while 65 patients (Group 2) underwent VATS. A thoracic surgery

resident performed all of the surgeries, either independently or under the supervision of thoracic surgery faculty members. The initial values such as age, sex, side of the lung involved, previous medical history of pneumothorax, as well as surgical outcomes including the length of surgery, length of hospitalization, recurrence, complication, and mortality rates were compared between the two groups.

All the patients in the first group underwent the standard posterolateral thoracotomy technique, and the second group underwent three-port thoracoscopic surgery using two 10.5 mm and one 5.5 mm Thoracoport™ Single Use Trocar (Covidien, Medtronic, USA). Both the open and VATS groups underwent the apical lung wedge resection. If there was a bulla or bleb, it was resected. Apical pleurectomy was done, and then pleural abrasion was performed by scrubbing the parietal pleura until a uniform aspect of bloody pleura was achieved. At the end of the procedure, one or two chest tubes number 28 (SUPA Medical Devices, Iran) were inserted into the thorax of each patient in both groups and connected to the chest bottle. The chest tubes were safely withdrawn, if the daily outputs were less than 150 mL/ 24 hours, and also there was no air leak, and the lungs were well expanded.

**Statistical Analysis**

The data were analyzed using SPSS software (version 18.0, Chicago, IL, USA) and GraphPad Prism software (version 9) and expressed as mean±SD for quantitative variables, and frequency and percentage for qualitative variables.

The Student's *t* test and analysis of variance (ANOVA) were used to test the hypotheses for comparing the means between groups. The Student's *t* test was used to compare the means between two groups, whereas ANOVA was used to compare the means among three or more groups. In ANOVA, the first step was to obtain a common P value. A significant P value of the ANOVA test indicated that the

mean difference between at least one pair was statistically significant. To identify that significant pair(s), multiple comparisons were performed. In this study, ANOVA followed by Bonferroni's *Post hoc* test was used to compare the differences between different treatment groups. The Chi squared test and fisher's exact test were used to compare qualitative variables between groups. P values less than 0.05 were considered statistically significant.

**Results**

A total of 90 patients, 74 men (82.2%) and 16 women (17.8%), who were diagnosed with PSP and underwent surgery, within seven years, were evaluated. The patients' age ranged from 15 to 68. In 69 (76.7%) and 82 (91.1%) of the cases, the patients complained of chest pain and shortness of breath, respectively, and the diagnosis was confirmed by plain radiography and chest CT scan. Open thoracotomy and VATS were performed in 65 (72.2%) and 25 (27.7%) of the patients, respectively. VATS was converted to open in seven cases out of the 25 open thoracotomy patients. The clinical and demographic characteristics of PSP patients who underwent surgery are summarized in table 1.

The most common procedure performed on all the patients was apical lung wedge resection. Apical lung wedge resection was done in combination with the other procedures (apical or total pleurectomy and scarification), but it was done alone in two patients (2.2%). In 47 patients (52.2%), a combination of apical lung wedge resection, apical parietal pleurectomy, and scarification was used. A combination of apical lung wedge resection and scarification was performed in 32 patients (35.5%). Six patients (6.6%) underwent both an apical pleurectomy and an apical lung wedge resection. A combination of total pleurectomy and apical lung wedge resection was done in three patients (3.3%).

Surgery was performed after the first episode of pneumothorax in 34 patients (37.7%) and after the pneumothorax recurrence in

**Table 1:** Clinical and demographic characteristics of PSP patients who underwent surgery

Variable	VATS N(%)	Open Thoracotomy N(%)	P value
Total, number (90 patients)	65 (72.2%)	25 (27.7%)	-
Age (mean±SD, year)*	28.14±9.37	27.08±9.31	0.632
Sex (male)***	53 (81.5%)	20 (80%)	>0.999
Smoking***	9 (13.8%)	4 (16%)	0.749
Right side involved***	38 (58.5%)	16 (64%)	0.631
Left side involved**	27 (41.5%)	7 (28%)	0.235
Bilateral involved***	0 (0.0%)	2 (8%)	0.075
Previous medical history of pneumothorax**	42 (64.6%)	12 (48%)	0.150

\*Student's *t* test; \*\*Chi square test; \*\*\*Fisher's exact test; VATS: Video-assisted thoracoscopic surgery

**Table 2:** Comparison of video-assisted thoracoscopic surgery, open thoracotomy, and converted VATS to open groups in terms of the operation time and postoperative hospital stay

Variable	VATS (mean±SD)	Open Thoracotomy (mean±SD)	Converted VATS to Open (mean±SD)	P value*
Total number of patients (n=82)	63 (76.8%)	15 (18.2%)	4 (4.8%)	-
Length of the surgery (min)	176.82±52.23	189.67±42.78	255.00±32.40	0.011
Postoperative hospital stay (days)	6.65±3.67	7.22±2.96	7.57±3.50	0.150

\*ANOVA test was performed. VATS: video-assisted thoracoscopic surgery

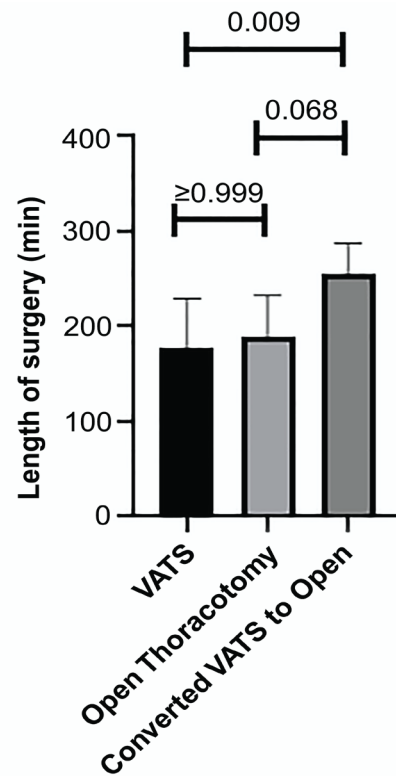
56 patients (62.2%). Among these patients, recurrences occurred in 45 (50.0%), 9 (10.0%), and 2 (2.2%) cases for the first, second, and third times, respectively. Before surgery, all the patients had received CTD treatment.

In our study, the length of the surgery for the 82 patients (63 VATS, 15 open, and four with converted VATS to open) was estimated using ANOVA with Bonferroni's *post hoc* test. The patients with prior talc pleurodesis were included in the converted group. As indicated in table 2 and figure 1, there were significant differences in the length of surgery (P=0.011) among the three mentioned groups (in the two groups and the subgroup converted to open).

Although the length of surgery in our study was found to be longer in the open thoracotomy and converted VATS to open groups, the results of the ANOVA test indicated no significant difference between these groups in terms of the length of postoperative hospital stay (P=0.150).

Of the 90 patients, 77 cases were visited for prospective follow-up. The mean of the duration of follow-up was 57±16.4 weeks (ranging, from 1-234 weeks). Our surgical interventions resulted in fourteen (18.2%) recurrences, including three open thoracotomies (15.8%), and 11 VATS procedures (19.0%). According to the results of Fisher's exact test, there was no significant difference in recurrence between the open and VATS groups (P=0.749). These 14 recurrent cases were all subjected to reoperation (nine with thoracotomy and five with VATS).

The comparison of the patients with PSP who underwent surgery according to the recurrence and complications was summarized in table 3. The failure of lung expansion and air leak were the most common complications in the VATS and thoracotomy groups, respectively. In our



**Figure 1:** Comparison of the operation time in video-assisted thoracoscopic surgery, open thoracotomy, and converted VATS to open groups in terms of the ANOVA with Bonferroni's *Post hoc* test. VATS: video-assisted thoracoscopic surgery

study, no mortality was reported. A comparison of the patients with PSP who underwent surgery based on the outcome is summarized in table 3.

### Discussion

The current standard of care for treating PSP around the world is video-assisted thoracoscopic surgery, which is consistent with the findings of

**Table 3:** Comparison of video-assisted thoracoscopic surgery, open thoracotomy, and converted VATS to open groups in terms of the recurrence and complications

Variable	VATS (N%)	Open Thoracotomy (N%)	P value*
Total number of patients (n=90)	65 (72.2%)	25 (27.7%)	
Recurrence	11 (16.9%)	3 (12%)	0.749
Complications	Air leakage	4 (16%)	0.048
	Bleeding	0 (0.0%)	>0.999
	Failure of lung Expansion	1 (4%)	>0.999

\*Fisher's exact test. VATS: video-assisted thoracoscopic surgery

the present study, in which VATS was the most commonly used surgery to treat PSP.<sup>5</sup> According to the surgical indications to treat PSP, the most common surgical indication was recurrent pneumothorax, and the results of our study were well-matched with the other studies.<sup>6, 7, 16</sup>

The findings of the study indicated that although there were no significant differences between study groups (open thoracotomy vs. VATS) in terms of the mean age, sex, smoking, side of the involved lung, previous medical history of pneumothorax, mean postoperative hospital stay, recurrence, post-operation bleeding, and failure of lung expansion, there were significant differences between these two groups in terms of the operation time and air leakage. According to the methods of surgery (open thoracotomy vs. VATS), Doğusoy and others found no significant differences in the patients' age, sex, postoperative length of hospital stay, recurrence, and complication rates. According to this study, the disadvantage of VATS was a longer duration of operation. However, the advantages were less pain, more patient satisfaction, and a quicker return to daily activities.<sup>6</sup>

The majority of patients in both groups in the present study had a history of pneumothorax, and in the majority of these cases, the pneumothorax was on the right side, which was consistent with the findings of Tulay and others.<sup>17</sup>

In the current study, the open thoracotomy group had a longer mean postoperative hospital stay, but the difference was not statistically significant. In other studies, patients who underwent VATS had shorter hospital stays than those who underwent open thoracotomy.<sup>6, 8, 15, 18-20</sup>

In our study, the length of surgery in patients treated with VATS was shorter than the open thoracotomy group, which was consistent with the findings of other studies.<sup>6, 19</sup> The reason for this outcome could be that the patients who underwent open thoracotomy had more complications, such as adhesions and multiple blebs/bullae, which prolonged the procedure.

In our study, the recurrence rate following open thoracotomy and VATS was 15.1% (n=3) and 19.0% (n=11), respectively. Therefore, although the VATS group had a higher recurrence rate, it was not statistically significant. According to a higher rate of recurrence in the VATS group, the findings of this study were consistent with that of other studies.<sup>4, 6, 19, 21-23</sup> The recurrence rate of spontaneous pneumothorax following VATS and open thoracotomy is about 4-11% and 1%, respectively.<sup>23</sup> The higher recurrence in the VATS group could be due to the poor vision during VATS, which resulted in not seeing blebs/bullae (missed leaking blebs/bullae), and

consequently, an incomplete resection. Another explanation could be that this method causes a less intense pleural inflammatory reaction than thoracotomy.<sup>24</sup> All parts of the pleura can be easily abraded during an open thoracotomy, which would result in a lower recurrence rate.<sup>24</sup>

In the current study, the mean postoperative hospital stay in VATS and open thoracotomy groups were 6.65 and 7.22 days, respectively (about 0.6 days lower in the VATS group), which was consistent with the findings of other studies in which hospital length of stay was reduced by an average of one day in VATS patients.<sup>23</sup>

The length of the surgical incision and tissue damage was shorter in the VATS group, resulting in less postoperative pain, improved patient compliance for coughing, and faster ambulation, all of which ultimately reduced complications.<sup>25</sup> In this study, the most prevalent complication in the VATS group was the failure of the lung to be expanded, which could be related to the inferior capacity of VATS to remove all the blebs/bullae compared to the open thoracotomy procedure. Therefore, this leads to more air leakage and consequently failure of the lungs to be expanded. On the other hand, in this study, air leakage was the most frequent complication in the thoracotomy group, which was consistent with the findings of previous studies.<sup>26</sup>

In our study, the converted group consisted of four patients with prior talc pleurodesis. In this group, thorough VATS adhesiolysis was performed, but due to progression failure, it was converted to open thoracotomy. Thus, according to the difficult conditions for VATS in PSP, the findings of the present study were compatible with those of Ng and others.<sup>27</sup> They have found that poor lung function in patients who could not tolerate one-lung ventilation, prior thoracic surgery or talc pleurodesis with extensive adhesions, giant pulmonary bull, and severely emphysematous lungs were the difficulties of VATS in spontaneous pneumothorax.<sup>27</sup> In the conversion from VATS to open thoracotomy, the roles of the surgeon and the institutional experience, as well as the influence of conversion on the immediate and late surgical outcomes are not fully known.<sup>28</sup> The mortality rate in our study was zero, which was similar to the previous studies.<sup>6, 29</sup>

The present study had some potential limitations. The first limitation was the small sample size, with thirteen patients refusing to participate or failing to follow up, so a larger registry of the patients from multiple thoracic surgery centers is required. The second limitation was the short mean duration of follow-ups, which was about 57 weeks (14 months),

which should be increased in future studies. The third limitation was the retrospective nature of this study, as in most previous research on VATS versus open thoracotomy, some factors led to a selection bias, such as determining how one is chosen for VATS versus open surgery. Hence, many of these factors as well as other non-measurable issues would affect the results leading to misperceiving and misinterpretation of information. To decrease the selection bias, better randomization by some future randomized control clinical trials should be done.

### Conclusion

When comparing VATS to open thoracotomy in the surgical treatment of PSP, VATS could be the primary treatment option due to a shorter length of surgery and a lower complication rate such as air leakage, though there is no difference in terms of the length of hospital stay.

### Acknowledgment

We would all like to thank the patient for granting permission for this case to be presented in this paper. This paper is the result of Saadat Mehrabi's residency dissertation for the thoracic surgery subspecialty. The authors would also like to thank Dr. Aida Irajie at the Central research laboratory, Shiraz University of Medical Sciences, Shiraz, Iran, for her technical assistance.

### Authors' Contributions

M.B.S: Study design, evaluating the patients clinically, operation of the patients (main surgeon), interpretation of the data, and critically revision; S.M: Study design, evaluating the patients clinically, operation of the patients (co-surgeon), interpretation of the data, and critically revision; C.I: data analysis, drafting, and critically revision; M.J.Y.B: Data analysis, interpretation of the data, drafting and critically revision; All authors have read and approved the final manuscript and agree to be accountable for all aspects of the work in ensuring that questions related to the accuracy or integrity of any part of the work are appropriately investigated and resolved.

**Conflict of Interest:** None declared.

### References

- 1 Wilson PM, Rymeski B, Xu X, Hardie W. An evidence-based review of primary spontaneous pneumothorax in the adolescent population. *J Am Coll Emerg Physicians Open*. 2021;2:e12449. doi: 10.1002/emp2.12449. PubMed PMID: 34179877; PubMed Central PMCID: PMC8212556.
- 2 Aujayeb A. Spontaneous Pneumothorax: New Horizons. *J Respir*. 2021;1:80-3. doi: 10.3390/jor1010008.
- 3 Foroulis CN. Surgery for primary spontaneous pneumothorax. *J Thorac Dis*. 2016;8:E1743-E5. doi: 10.21037/jtd.2016.12.31. PubMed PMID: 28149629; PubMed Central PMCID: PMC5227202.
- 4 Carson-Chahhoud KV, Wakai A, van Agteren JE, Smith BJ, McCabe G, Brinn MP, et al. Simple aspiration versus intercostal tube drainage for primary spontaneous pneumothorax in adults. *Cochrane Database Syst Rev*. 2017;9:CD004479. doi: 10.1002/14651858.CD004479.pub3. PubMed PMID: 28881006; PubMed Central PMCID: PMC6483783.
- 5 Daemen JHT, Lozekoot PWJ, Maessen JG, Gronenschild MHM, Bootsma GP, Hulsewe KWE, et al. Chest tube drainage versus video-assisted thoracoscopic surgery for a first episode of primary spontaneous pneumothorax: a systematic review and meta-analysis. *Eur J Cardiothorac Surg*. 2019;56:819-29. doi: 10.1093/ejcts/ezz116. PubMed PMID: 31329896.
- 6 Dogusoy I, Yildirim M, Ustaalioglu R, Demirbag H. A comparison of axillary thoracotomy versus video-assisted thoracoscopic surgery in the surgical treatment of primary spontaneous pneumothorax. *Turk Gogus Kalp Damar Cerrahisi Derg*. 2018;26:132-7. doi: 10.5606/tgkdc.dergisi.2018.15279. PubMed PMID: 32082722; PubMed Central PMCID: PMC7018116.
- 7 Chikaishi Y, Kanayama M, Taira A, Nabe Y, Shinohara S, Kuwata T, et al. What is the best treatment strategy for primary spontaneous pneumothorax? A retrospective study. *Ann Med Surg (Lond)*. 2019;45:98-101. doi: 10.1016/j.amsu.2019.07.034. PubMed PMID: 31440373; PubMed Central PMCID: PMC6699185.
- 8 Al-Mourgi M, Alshehri F. Video-Assisted Thoracoscopic Surgery for the Treatment of First-Time Spontaneous Pneumothorax versus Conservative Treatment. *Int J Health Sci (Qassim)*. 2015;9:428-32. PubMed PMID: 26715922; PubMed Central PMCID: PMC4682597.
- 9 Marcheix B, Brouchet L, Renaud C, Lamarche Y, Mugniot A, Benouaich V, et al. Videothoracoscopic silver nitrate pleurodesis for primary spontaneous pneumothorax: an alternative

- to pleurectomy and pleural abrasion? *Eur J Cardiothorac Surg.* 2007;31:1106-9. doi: 10.1016/j.ejcts.2007.03.017. PubMed PMID: 17466531.
- 10 Puri HV, Asaf BB, Pulle MV, Bishnoi S, Kumar A. Video-assisted thoracoscopic surgery management of primary spontaneous pneumothorax: Results in 110 consecutive cases. *Lung India.* 2021;38:36-40. doi: 10.4103/lungindia.lungindia\_453\_19. PubMed PMID: 33402636; PubMed Central PMCID: PMC8066916.
  - 11 Amer K. Controversies in Pneumothorax Treatment. In: Amer K. *Pneumothorax.* Intech Open Book series. University Hospital Southampton. Pneumothorax: IntechOpen; 2019. doi: 10.5772/intechopen.87141.
  - 12 Mehrabi S, Tanideh N, Hosseinpour R, Irajie C, Yavari Barhaghtalabi MJ. A left lung with four lobes: a new discovery during the thoracotomy for recurrent primary spontaneous pneumothorax. *J Cardiothorac Surg.* 2021;16:276. doi: 10.1186/s13019-021-01651-3. PubMed PMID: 34583735; PubMed Central PMCID: PMC8479984.
  - 13 Al-Qudah A. Video-assisted thoracoscopy versus open thoracotomy for spontaneous pneumothorax. *J Korean Med Sci.* 1999;14:147-52. doi: 10.3346/jkms.1999.14.2.147. PubMed PMID: 10331559; PubMed Central PMCID: PMC83054364.
  - 14 Jimenez-Merchan R, Garcia-Diaz F, Arenas-Linares C, Giron-Arjona JC, Congregado-Loscertales M, Loscertales J. Comparative retrospective study of surgical treatment of spontaneous pneumothorax. Thoracotomy vs thoracoscopy. *Surg Endosc.* 1997;11:919-22. doi: 10.1007/s004649900487. PubMed PMID: 9294273.
  - 15 Bagheri R, Ziaollah Haghi S, Attaran D, Ebadi F, Rajabnejad Y, Rajabnejad Ao. Video-assisted thoracoscopic surgery versus axillary thoracotomy in primary spontaneous pneumothorax. *Journal of Cardio-Thoracic Medicine.* 2017;5:538-42.
  - 16 Kocatürk Cİ, Cansever L, Günlüoğlu MZ, Turna A, Özdemir S, Çınar U, et al. The results of wedge resection and partial pleurectomy in the surgical treatment of primary spontaneous pneumothorax: videothoracoscopy or axillary thoracotomy. *Turk Gogus Kalp Dama.* 2011;19:213-7. doi: 10.5606/tgkdc.dergisi.2011.015.
  - 17 Tulay CM, Ozsoy IE. Spontaneous Pneumothorax Recurrence and Surgery. *Indian J Surg.* 2015;77:463-5. doi: 10.1007/s12262-013-0876-6. PubMed PMID: 26730046; PubMed Central PMCID: PMC84692894.
  - 18 Laohathai S. Outcome comparison between video assisted thoracoscopic surgery and open thoracotomy on primary spontaneous pneumothorax in a tertiary hospital in Thailand. *Journal of The Medical Association of Thailand.* 2021;104:100-4. doi: 10.35755/jmedassocthai.2021.01.11510.
  - 19 Sawada S, Watanabe Y, Moriyama S. Video-assisted thoracoscopic surgery for primary spontaneous pneumothorax: evaluation of indications and long-term outcome compared with conservative treatment and open thoracotomy. *Chest.* 2005;127:2226-30. doi: 10.1378/chest.127.6.2226. PubMed PMID: 15947341.
  - 20 Wakefield CJ, Seder CW, Arndt AT, Geissen N, Liptay MJ, Karush JM. Cannabis Use Is Associated With Recurrence After Primary Spontaneous Pneumothorax. *Front Surg.* 2021;8:668588. doi: 10.3389/fsurg.2021.668588. PubMed PMID: 34113644; PubMed Central PMCID: PMC8185055.
  - 21 Takahashi R. Evaluation of Spontaneous Pneumothorax Surgeries: A 16-Year Experience in Japan. *Surg Res Pract.* 2016;2016:7025793. doi: 10.1155/2016/7025793. PubMed PMID: 27191013; PubMed Central PMCID: PMC84846764.
  - 22 Pages PB, Delpy JP, Falcoz PE, Thomas PA, Filaire M, Le Pimpec Barthes F, et al. Videothoracoscopy versus thoracotomy for the treatment of spontaneous pneumothorax: a propensity score analysis. *Ann Thorac Surg.* 2015;99:258-63. doi: 10.1016/j.athoracsur.2014.08.035. PubMed PMID: 25440269.
  - 23 Porcel JM, Lee P. Thoracoscopy for Spontaneous Pneumothorax. *J Clin Med.* 2021;10. doi: 10.3390/jcm10173835. PubMed PMID: 34501282; PubMed Central PMCID: PMC8432077.
  - 24 Joshi V, Kirmani B, Zacharias J. Thoracotomy versus VATS: is there an optimal approach to treating pneumothorax? *Ann R Coll Surg Engl.* 2013;95:61-4. doi: 10.1308/003588413X13511609956138. PubMed PMID: 23317731; PubMed Central PMCID: PMC83964642.
  - 25 Bendixen M, Jorgensen OD, Kronborg C, Andersen C, Licht PB. Postoperative pain and quality of life after lobectomy via video-assisted thoracoscopic surgery or anterolateral thoracotomy for early stage lung cancer: a randomised controlled trial. *Lancet Oncol.* 2016;17:836-44. doi: 10.1016/S1470-2045(16)00173-X. PubMed PMID:

- 27160473.
- 26 Yoo A, Ghosh SK, Danker W, Kassis E, Kalsekar I. Burden of air leak complications in thoracic surgery estimated using a national hospital billing database. *Clinicoecon Outcomes Res.* 2017;9:373-83. doi: 10.2147/CEOR.S133830. PubMed PMID: 28721079; PubMed Central PMCID: PMC5498775.
- 27 Ng CS, Lee TW, Wan S, Yim AP. Video assisted thoracic surgery in the management of spontaneous pneumothorax: the current status. *Postgrad Med J.* 2006;82:179-85. doi: 10.1136/pgmj.2005.038398. PubMed PMID: 16517799; PubMed Central PMCID: PMC2563704.
- 28 Puri V, Patel A, Majumder K, Bell JM, Crabtree TD, Krupnick AS, et al. Intraoperative conversion from video-assisted thoracoscopic surgery lobectomy to open thoracotomy: a study of causes and implications. *J Thorac Cardiovasc Surg.* 2015;149:55-61. doi: 10.1016/j.jtcvs.2014.08.074. PubMed PMID: 25439768; PubMed Central PMCID: PMC4272658.
- 29 Cardillo G, Bintcliffe OJ, Carleo F, Carbone L, Di Martino M, Kahan BC, et al. Primary spontaneous pneumothorax: a cohort study of VATS with talc poudrage. *Thorax.* 2016;71:847-53. doi: 10.1136/thoraxjnl-2015-207976. PubMed PMID: 27422793.