

Original Article

Diagnostic Efficacy of Digital Waters' and Caldwell's Radiographic Views for Evaluation of Sinonasal Area

Hamed Ebrahimnejad ¹, Seyed Hosein Hoseini Zarch ^{2✉}, Adineh Javadian Langaroodi ³

¹ Oral and Maxillofacial Radiologist, Department of Oral and Maxillofacial Radiology, School of Dentistry, Kerman University of Medical Sciences, Kerman, Iran

² Associate Professor, Department of Oral and Maxillofacial Radiology, Dental Materials Research Center, School of Dentistry, Mashhad University of Medical Sciences, Mashhad, Iran

³ Assistant Professor, Department of Oral and Maxillofacial Radiology, Maxillofacial Diseases Research Center, School of Dentistry, Mashhad University of Medical Sciences, Mashhad, Iran

Abstract

Objectives: New digital two-dimensional imaging systems are considered as an easily accessible modality for sinonasal evaluation. The aim of this study was to assess the diagnostic efficacy of digital Waters' and Caldwell's radiographic views for evaluation of sinonasal area.

Materials and Methods: A total of 273 patients fulfilling the inclusion criteria were enrolled in this descriptive-analytical study. Complete opacification or mucosal thickening of frontal, ethmoidal and maxillary sinuses and nasal septum deviation were assessed on digital Waters and Caldwell images. Considering cone beam computed tomography (CBCT) as the gold standard, accuracy, sensitivity, specificity, positive predictive value (PPV) and negative predictive value (NPV) were obtained for the plain films.

Results: The sensitivity and specificity for the diagnosis of complete opacification were 89.47% and 95.66% (for frontal sinus), 100% and 97.59% (for ethmoidal air cells), and 100% and 96.42% (for maxillary sinuses), respectively. Regarding mucosal thickening, the sensitivity and specificity were 51.43% and 90.70% (for frontal sinus), 60.84% and 84.80% (for ethmoidal air cells) and 81% and 74.74% (for maxillary sinuses), respectively. The sensitivity of Waters and Caldwell images for detecting nasal septum deviation was 84.31% and 87.25%, respectively; whereas, their specificity was 100%.

Conclusions: Digital Caldwell image performs well in detecting frontal and ethmoidal opacification and nasal septum deviation. It has moderate efficacy in assessing frontal and ethmoidal mucosal thickening while it has superior performance for detection of healthy cases. Digital Waters' view is a reliable modality for maxillary sinus evaluation.

Keywords: Cone-Beam Computed Tomography; Nasal Septum; Paranasal Sinuses; Radiography
Journal of Dentistry, Tehran University of Medical Sciences, Tehran, Iran (2016; Vol. 13, No. 5)

✉ Corresponding author:

S. H. Hoseini Zarch, Department of Oral and Maxillofacial Radiology, Dental Materials Research Center, School of Dentistry, Mashhad University of Medical Sciences, Mashhad, Iran

hsimple11@yahoo.com

Received: 6 February 2016

Accepted: 11 May 2016

INTRODUCTION

Sinonasal inflammatory disease is usually considered as the most common illness in the United States [1]. Acute and chronic rhinosinusitis are the most prevalent diseases in this category [2]. Many predisposing factors such as anatomical anomalies, allergy and inheritance can make an individual prone to chronic rhinosinusitis [3]. Nasal septum deviation is also associated with chronic sinusitis and is usually accompanied by nasal obstruction, hypernasality and various degrees of anosmia [4].

Radiography plays a fundamental role in the

diagnosis of sinonasal inflammatory diseases [5,6]. The main radiographic diagnostic criteria for sinusitis include sinus opacification, air-fluid level and mucosal thickening. Mucosal thickening is common to both acute and chronic sinusitis [7-9].

Although it is generally accepted that computed tomography (CT) is the gold standard modality for sinonasal imaging, cone-beam computed tomography (CBCT) can also be reliable in this field. Visualization quality of paranasal sinuses and bony structures in CBCT is similar to CT. Furthermore, CBCT produces high-resolution

images and can show benefits for evaluating bony aspects of sinonasal area by using a lower radiation dose [6,10-13].

Using plain films such as Waters' view (occipitontal view) and Caldwell's view (occipitofrontal view) is a traditional method for evaluating sinonasal area. They are favorable for their availability, ease of use, low radiation dose and low cost [14-16]. With emergence of new digital systems, plain films show more efficacy than before. The numerous features of image enhancement in digital imaging, alongside lower radiation dose may represent digital plain radiography as a simple and acceptable modality in this field [17]. Considering the CBCT as the gold standard, the purpose of this study was to assess the diagnostic efficacy of digital Waters' and Caldwell's radiographic views for evaluation of the sinonasal area.

MATERIALS AND METHODS

The information of patients who were referred from the Mashhad University of Medical Sciences Otolaryngology Department to the Department of Radiology between 2009-2015 was collected. All these patients were clinically suspected for acute or chronic rhinosinusitis and their physicians had requested digital Waters' and Caldwell's radiographic views for primary assessment.

The diagnostic criteria for rhinosinusitis included mucopurulent drainage, nasal obstruction (congestion), facial pain, pressure and fullness, or decreased sense of smell. After evaluating the Waters' and Caldwell's views, CBCT from the sinonasal area was requested for the subjects who needed a more detailed examination. Among these, patients whose Waters, Caldwell and CBCT scans were all captured on the same day were recruited for this study. The patients who had interventional procedures such as medication intake in the time period between plain films and CBCT acquisition were excluded. The subjects with traumatic injuries or tumoral masses were

also excluded. The patients were given oral and written information about the study and gave their written informed consent. The regional ethics committee approved the study protocol (code: 930175).

The Waters and Caldwell radiographs were captured by Promax (Planmeca Inc., Helsinki, Finland) and the images were digitized using Konica CR receptor (Konica Minolta Medical Imaging, Wayne, NJ, USA) at 64-68kVp and 8-10mA.

The CBCT scans were obtained and evaluated with Promax 3D Max and Romexis 2.4.2.R software, respectively (Planmeca Inc., Helsinki, Finland) at 80-84kVp, 6-8mA, volume size=230×160mm, voxel size=400µm, exposure time=12s and slice interval=2mm. Images were reconstructed using a high spatial frequency reconstruction algorithm.

The data from 273 patients (124 women and 149 men with a mean age of 43 years) were collected. Under a constant viewing condition, the Waters, Caldwell and CBCT images were interpreted independently by two experienced maxillofacial radiologists who filled the checklists. Divergent interpretations were discussed and final agreement was reached in all cases. The observers were completely blinded to the relationship between the radiographs.

Complete opacification or mucosal thickening of frontal, ethmoidal and maxillary sinuses and nasal septum deviation were the parameters studied (Figs. 1 and 2). The sphenoid sinus was excluded, as it does not create a reliable image on open-mouth Waters radiographs.

For each patient, the left and right frontal, ethmoidal and maxillary sinuses were assessed separately. The agenetic frontal sinuses (unilateral or bilateral) were excluded from the study. The frontal and ethmoidal sinuses were assessed on the Caldwell images, while the Waters radiographs were used for the maxillary sinuses. Nasal septum deviation was evaluated on both Waters' and Caldwell's views.

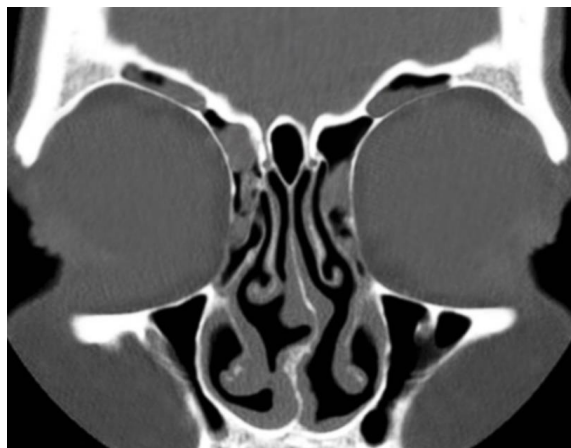

Fig. 1: The frontal and ethmoidal sinuses show mucosal thickening on the coronal view.

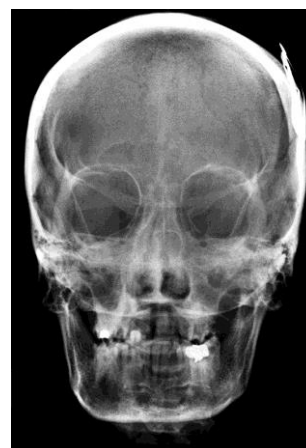


Fig. 2: A Caldwell radiograph showing opacification of frontal and ethmoidal sinuses.

Mucosal thickening was assessed by measuring the mucosal thickness from the sinus wall to the maximum mucosal prominence on CBCT scans. Mucosal thickening greater than 2 and 3mm in ethmoidal and maxillary sinuses, respectively was considered pathological [7,18-21]. On the Waters and Caldwell radiographs, the study parameters such as mucosal thickening were only registered as “yes” or “no” without measurement because the measurements were not reliable (Fig. 3). Nasal septum deviation was assessed on CBCT scans. On the coronal section illustrating the most deviated point, a line was drawn from the base of the crista galli of ethmoid bone (superior insertion of septum) to the inferior insertion of septum at the level of maxillary crest. Another line connected the base of the crista galli to the most deviated point of nasal septum. The formed angle was considered as the degree of septum deviation [22] (Fig. 4). In S-shaped nasal septa, the most deviated side was recorded. Using CBCT as the gold standard, the Waters/Caldwell findings were assessed and their diagnostic efficacy was analyzed.

Statistical analysis:

Descriptive statistical methods were used to present the results. Accuracy, sensitivity, specificity, positive predictive value (PPV) and negative predictive value (NPV) indices were calculated for each study parameter [23].

Furthermore, confidence intervals (95% CI) were computed for each statistical index using the StatXact 5 software package (Cytel Software Corporation, Cambridge, MA, USA) [24].

RESULTS

Complete opacification of frontal sinuses:

From 546 left and right frontal sinuses, 43 were agenetic (13 bilateral and 17 unilateral). On CBCT scans, complete opacification was detected in 19 sinuses (four bilateral and 11 unilateral, Table 1).

Mucosal thickening of frontal sinuses:

On CBCT images, 105 frontal sinuses had mucosal thickening (38 bilateral and 29 unilateral) while Caldwell's view showed 91 affected sinuses. The thickened mucosa was averagely 2-35mm. The diagnostic indices are presented in Table 1.

Complete opacification of ethmoidal air cells:

From 546 ethmoidal sinuses, seven were fully opacified on CBCT scans (two bilateral and three unilateral). The sensitivity and specificity of Caldwell radiographs for detection of complete opacification of ethmoidal air cells were 100% and 97.59%, respectively (Table 1).

Mucosal thickening of ethmoidal air cells:

On CBCT scans, 143 ethmoidal sinuses had pathological mucosal thickening (>2mm). Caldwell's view detected thickened mucosa in

Table 1: Diagnostic indices demonstrating the efficacy of Waters and Caldwell radiographs

Radiograph	Evaluated parameter	No.	Accuracy, % (95% CI)	Sensitivity, % (95% CI)	Specificity, % (95% CI)	PPV, % (95% CI)	NPV, % (95% CI)
Caldwell	Frontal sinus complete opacification	503	95.43 (±1.82)	89.47 (±2.68)	95.66 (±1.78)	44.74 (±4.35)	99.57 (±0.57)
Caldwell	Frontal sinus mucosal thickening	503	82.50 (±3.32)	51.43 (±4.37)	90.70 (±2.54)	59.34 (±4.29)	87.62 (±2.88)
Caldwell	Ethmoidal air cells complete opacification	546	97.62 (±1.28)	100 (0)	97.59 (±1.29)	35 (±4)	100 (0)
Caldwell	Ethmoidal air cells mucosal thickening	546	71.79 (±3.77)	60.84 (±4.09)	84.80 (±3.01)	66.23 (±3.97)	73.98 (±3.68)
Waters	Maxillary sinus complete opacification	546	96.52 (±1.54)	100 (0)	96.42 (±1.56)	44.12 (±4.16)	100 (0)
Waters	Maxillary sinus mucosal thickening	546	67.03 (±3.94)	81 (±5.44)	74.74 (±3.64)	81.85 (±3.23)	52.54 (±4.19)

*PPV=Positive predictive value, NPV=Negative predictive value, CI=Confidence interval

154 sinuses and showed better specificity than sensitivity (Table 1).

Complete opacification of maxillary sinuses:

From 546 maxillary sinuses evaluated, 15 were totally opacified (three bilateral and nine unilateral). Waters' view showed high sensitivity and specificity in detecting the opacified maxillary sinuses. However, its PPV was low (Table 1).

Mucosal thickening of maxillary sinuses:

According to CBCT scans, pathological maxillary sinus mucosal thickening (>3mm) was observed in 200 sinuses. Waters' view detected thickened mucosa in 154 sinuses and showed higher sensitivity than specificity (Table 1).

Nasal septum deviation:

Among 273 patients, 204 had nasal septum deviation detected on CBCT scans (95 women and 109 men). Both Waters' and Caldwell's views could detect septum deviation; however, Caldwell's view showed a slightly better result in detecting deviated septa (Fig. 5).

Sinusitis:

According to the radiographic evidence of sinusitis (opacification and pathological mucosal thickening), we plotted a grouped bar chart showing the efficacy of Waters' and Caldwell's views in detecting sinusitis in frontal, ethmoidal and maxillary sinuses (Fig. 6).

DISCUSSION

The diagnostic efficacy of digital Waters and Caldwell radiographs was evaluated in this research. However, no previous study has evaluated the reliability of digital plain films for assessment of sinonasal area. The relatively large sample size, alongside simultaneous image capturing procedure for each patient increased the reliability of the results. The high prevalence of inflammatory sinonasal diseases certainly underscores the need for assessment of the efficacy of related imaging modalities.

Frontal sinus opacification or mucosal thickening can be found either alone or in companion with other paranasal sinus involvements [5]. Although Caldwell's view showed excellent capability in illustrating fully opacified frontal sinuses, it had a moderate false negative rate in detecting mucosal thickening (sensitivity=51.43%). This means that Caldwell's view can detect intact frontal sinuses better than the ones with mucosal thickening. This was also true for ethmoidal air cells. Caldwell's view can show air cell opacification in an acceptable manner; whereas, its sensitivity is mediocre in displaying ethmoidal mucosal thickening (50%). Moreover, the low PPV proves that the physician should not rely much on its positive results.

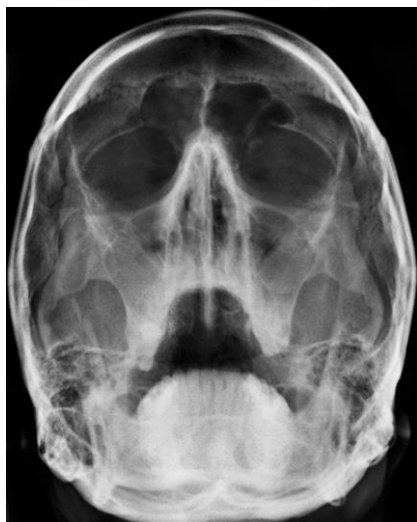

Fig. 3: A Waters radiograph showing maxillary sinus mucosal thickening.

Waters' view was used for the maxillary sinus assessment. Complete opacification of maxillary sinus is an infrequent finding that reveals a severe inflammatory or tumoral condition [7]. From 19 false positive full opacification records on Waters radiographs, 18 cases had pathological mucosal thickening. This can underline the fact that Waters' view is an acceptable modality for maxillary sinus assessment. Burke et al. [21] evaluated 30 patients with maxillary sinusitis and compared plain films with CT scan as the gold standard. The sensitivity and specificity of plain films for maxillary sinusitis were 70% and 96-100%, respectively. This was almost consistent with our results; however our results showed lower specificity. An overall comparison between the diagnostic efficacy of Waters' and Caldwell's views in detecting different paranasal sinusitis revealed that in cases of disease, they were reliable for maxillary, ethmoidal and frontal sinuses (in order of reliability). In a study by Iinuma et al, [25] the paranasal sinuses of 61 patients with sinusitis were evaluated using plain films and CT scan as the gold standard. They categorized the plain film findings as under-diagnosis, matched-diagnosis and over-diagnosis. Matched-diagnosis was reported in maxillary, frontal and ethmoidal sinuses, respectively.

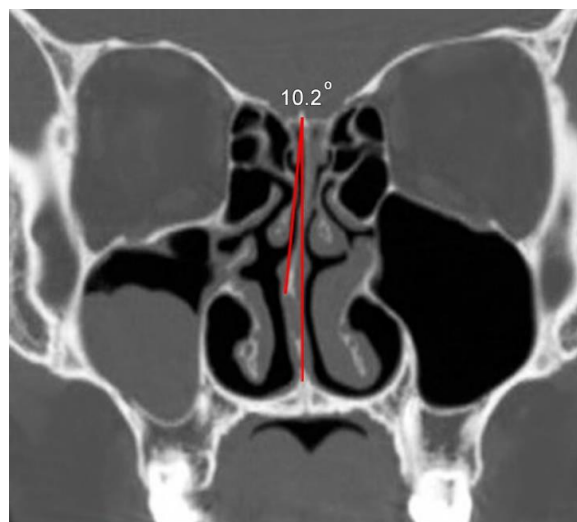


Fig. 4: The coronal CBCT view was used for assessing nasal septum deviation.

The highest rate of over-diagnosis of sinusitis was assigned to the posterior ethmoidal cells. The involvement of anterior ethmoidal cells remained mostly under-diagnosed. Our results supported this assertion that plain films (especially Waters' view) can well illustrate radiographic signs of sinusitis.

About 75% of patients (n=204) had some degrees of nasal septum deviation. Waters' and Caldwell's views correctly diagnosed 172 and 178 cases, respectively. Both views performed well in this regard. As expected, the diagnostic efficacy of plain films was higher in severely deviated septa.

Chen et al, [26] and some other researchers [27-29] investigated the diagnostic efficacy of plain films in pediatric sinusitis. Although their results were often consistent with our data, since the physiology and course of inflammatory sinonasal disease in children is different from adults, this comparison is not reliable.

Konen et al. [30] obtained Waters and high-resolution CT scans (gold standard) from 134 patients, who were suspected for sinusitis. Regarding the maxillary sinusitis diagnosis, the accuracy, sensitivity, specificity, PPV and NPV of Waters' view were 67.7%, 87.6%, 78.6%, 82.5% and 76.9%, respectively. The sphenoid sinus showed unreliable results.

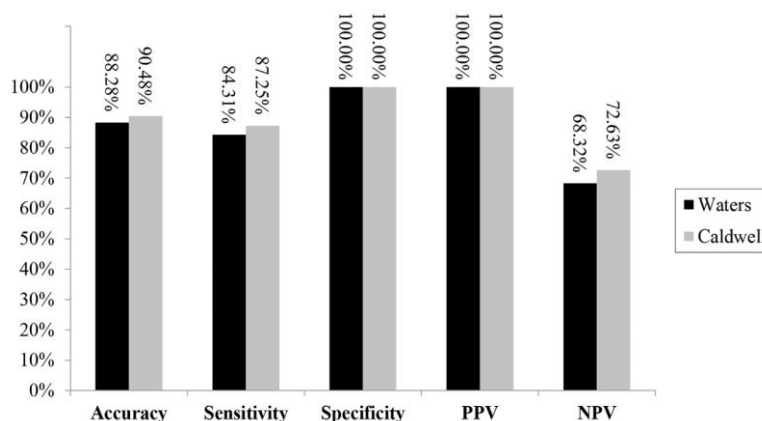


Fig. 5: Statistical measures demonstrating the efficacy of Waters and Caldwell radiographs in diagnosing nasal septum deviation (n=273) (PPV=Positive predictive value, NPV=Negative predictive value)

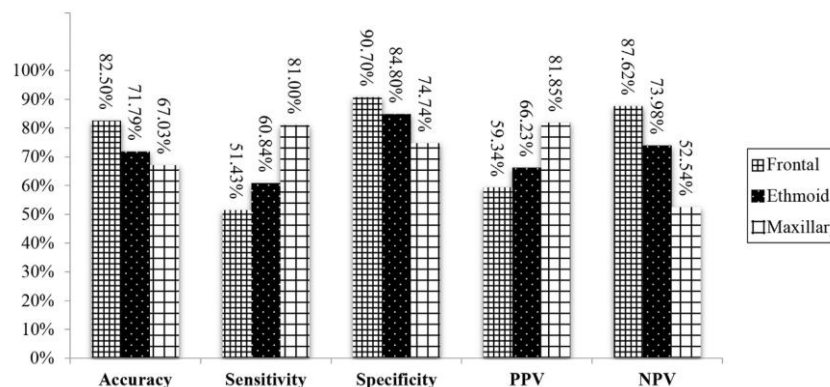


Fig. 6: Statistical measures demonstrating the efficacy of Waters and Caldwell radiographs in diagnosing sinusitis, categorized by each paranasal sinus (PPV=Positive predictive value, NPV=Negative predictive value)

These findings were confirmed by the current study. The diagnostic value of Waters radiograph was evaluated in another study on 40 patients with sinusitis. Comparing with CT as the gold standard, the sensitivity, specificity and PPV of Waters' view was 83.3%, 69.2% and 83.3%, respectively [31]. Our study agreed with the above. The same results were obtained in another study on 47 patients. Aaløkken et al. [32] investigated the diagnostic efficacy of Waters' and Caldwell's views, considering CT as the gold standard. The sensitivity of plain films in detecting paranasal sinusitis was low (except for maxillary sinuses) but their specificity was high. Our findings were in line with those of the above-mentioned study, however, our results showed higher sensitivity.

CONCLUSION

Digital plain films such as Waters' and Caldwell's views show acceptable diagnostic value in sinonasal area. Digital Caldwell's view performs well in assessing frontal and ethmoidal sinus opacification, as well as nasal septum deviation.

It has average efficacy in cases of frontal or ethmoidal mucosal thickening. Digital Waters' view is a reliable modality for maxillary sinus evaluation.

REFERENCES

1- Braun H, Buzina W, Freudenschuss K, Beham A, Stammberger H. 'Eosinophilic fungal rhinosinusitis': a common disorder in Europe? Laryngoscope. 2003 Feb;113(2):264-9.

- 2- Krouse JH. Inflammatory sinonasal disease. *Facial Plast Surg Clin North Am.* 2004 Nov;12(4):407-14.
- 3- Staikūniene J, Vaitkus S, Japertiene LM, Ryskiene S. Association of chronic rhinosinusitis with nasal polyps and asthma: clinical and radiological features, allergy and inflammation markers. *Medicina (Kaunas).* 2008;44(4):257-65.
- 4- Rao JJ, Kumar EV, Babu KR, Chowdary VS, Singh J, Rangamani SV. Classification of nasal septal deviations—relation to sinonasal pathology. *Indian J Otolaryngol Head Neck Surg.* 2005 Jul;57(3):199-201.
- 5- Calhoun KH, Waggenspack GA, Simpson CB, Hokanson JA, Bailey BJ. CT evaluation of the paranasal sinuses in symptomatic and asymptomatic populations. *Otolaryngol Head Neck Surg.* 1991 Apr;104(4):480-3.
- 6- Varonen H, Makela M, Savolainen S, Laara E, Hilden J. Comparison of ultrasound, radiography, and clinical examination in the diagnosis of acute maxillary sinusitis: a systematic review. *J Clin Epidemiol.* 2000 Sep;53(9):940-8.
- 7- Som P, Curtin H. *Head and neck imaging.* 5th ed., St. Louis, Mosby, 2011:167-217.
- 8- Mafee MF, Tran BH, Chapa AR. Imaging of rhinosinusitis and its complications: plain film, CT, and MRI. *Clin Rev Allergy Immunol.* 2006 Jun;30(3):165-86.
- 9- Momeni AK, Roberts CC, Chew FS. Imaging of Chronic and Exotic Sinonasal Disease: review. *AJR Am J Roentgenol.* 2007 Dec;189(6 Suppl):S35-45.
- 10- Ritter L, Lutz J, Neugebauer J, Scheer M, Dreiseidler T, Zinser MJ, et al. Prevalence of pathologic findings in the maxillary sinus in cone-beam computerized tomography. *Oral Surg Oral Med Oral Pathol Oral Radiol Endod.* 2011 May;111(5):634-40.
- 11- Angelopoulos C. Cone beam tomographic imaging anatomy of the maxillofacial region. *Dent Clin North Am.* 2008 Oct;52(4):731-52.
- 12- Leung R, Chaung K, Kelly JL, Chandra RK. Advancements in computed tomography management of chronic rhinosinusitis. *Am J Rhinol Allergy.* 2011 Sep-Oct;25(5):299-302.
- 13- Schulze D, Heiland M, Thurmann H, Adam G. Radiation exposure during midfacial imaging using 4- and 16-slice computed tomography, cone beam computed tomography systems and conventional radiography. *Dentomaxillofac Radiol.* 2004 Mar;33(2):83-6.
- 14- Mendelsohn M, Noyek A. The role of conventional sinus radiographs in paranasal sinus disease. In: Shankar L, Evans K. *An atlas of imaging of the paranasal sinuses.* 2nd ed., United States, CRC Press, 2006:35-6.
- 15- Saiki T, Yumoto E. Quantification of X-ray opacity of the maxillary sinus in the Waters' view. *Auris Nasus Larynx.* 1997 Jul;24(3):289-97.
- 16- Williams JW Jr, Roberts L Jr, Distell B, Simel DL. Diagnosing sinusitis by X-ray: is a single Waters view adequate? *J Gen Intern Med.* 1992 Sep-Oct;7(5):481-5.
- 17- Cowen AR, Davies AG, Kengyelics SM. Advances in computed radiography systems and their physical imaging characteristics. *Clin Radiol.* 2007 Dec;62(12):1132-41.
- 18- Eggesbø HB. Radiological imaging of inflammatory lesions in the nasal cavity and paranasal sinuses. *Eur Radiol.* 2006 Apr;16(4):872-88.
- 19- Rak KM, Newell JD 2nd, Yakes WF, Damiano MA, Luethke JM. Paranasal sinuses on MR images of the brain: significance of mucosal thickening. *AJR Am J Roentgenol.* 1991 Feb;156(2):381-4.
- 20- Sheikhi M, Pozve NJ, Khorrami L. Using cone beam computed tomography to detect the relationship between the periodontal bone loss and mucosal thickening of the maxillary sinus. *Dent Res J (Isfahan).* 2014 Jul;11(4):495-501.
- 21- Burke TF, Guertler AT, Timmons JH. Comparison of sinus x-rays with computed tomography scans in acute sinusitis. *Acad Emerg Med.* 1994 May-Jun;1(3):235-9.
- 22- Elahi MM, Frenkiel S, Fageeh N. Paraseptal structural changes and chronic sinus disease in relation to the deviated septum. *J Otolaryngol.* 1997 Aug;26(4):236-40.
- 23- Chu K. An introduction to sensitivity, specificity, predictive values and likelihood ratios. *Emerg Med Australas.* 1999 Sep 8;11(3):175-81.
- 24- Agresti A, Coull BA. Approximate is better than "exact" for interval estimation of binomial proportions. *Am Stat.* 1998 May;52(2):119-26.
- 25- Iinuma T, Hirota Y, Kase Y. Radio-opacity of the paranasal sinuses. Conventional views and CT. *Rhinology.* 1994 Sep;32(3):134-6.

- 26- Chen LC, Huang JL, Wang CR, Yeh KW, Lin SJ. Use of standard radiography to diagnose paranasal sinus disease of asthmatic children in Taiwan: comparison with computed tomography. *Asian Pac J Allergy Immunol.* 1999 Jun;17(2):69-76.
- 27- McAlister WH, Lusk R, Muntz HR. Comparison of plain radiographs and coronal CT scans in infants and children with recurrent sinusitis. *AJR Am J Roentgenol.* 1989 Dec;153(6):1259-64.
- 28- Ros SP, Herman BE, Azar-Kia B. Acute sinusitis in children: is the Water's view sufficient? *Pediatr Radiol.* 1995;25(4):3.
- 29- Lee HS, Majima Y, Sakakura Y, Inagaki M, Sugiyama Y, Nakamoto S. [Conventional X-ray versus CT in diagnosis of chronic sinusitis in children]. *Nihon Jibiinkoka Gakkai Kaiho.* 1991 Sep;94(9):1250-6.
- 30- Konen E, Faibel M, Kleinbaum Y, Wolf M, Lusky A, Hoffman C, et al. The value of the occipitomeatal (Waters') view in diagnosis of sinusitis: a comparative study with computed tomography. *Clin Radiol.* 2000 Nov;55(11):856-60.
- 31- Timmenga N, Stegenga B, Raghoobar G, van Hoogstraten J, van Weissenbruch R, Vissink A. The value of Waters' projection for assessing maxillary sinus inflammatory disease. *Oral Surg Oral Med Oral Pathol Oral Radiol Endod.* 2002 Jan;93(1):103-9.
- 32- Aaløkken TM, Hagtvedt T, Dalen I, Kolbenstvedt A. Conventional sinus radiography compared with CT in the diagnosis of acute sinusitis. *Dentomaxillofac Radiol.* 2003 Jan;32(1):60-2.