



Role of Transthoracic Echocardiography in the Evaluation of Patients with Retinal Vein Occlusion

Afsoon Fazlinezhad^{1,4}, Toka Banaee², Ali Azari³, Leila Bigdelu^{1,4,5*}, Mojde Amini⁶

¹ Cardiologist, Department of Cardiology, Ghaem Hospital, Faculty of Medicine, Mashhad University of Medical Sciences, Mashhad, Iran

² Ophthalmologist, Retina Research Center, Department of Ophthalmology, Faculty of Medicine, Mashhad University of Medical Sciences

³ Cardiac-Surgeon, Department of Cardiac Surgery, Ghaem Hospital, Faculty of Medicine, Mashhad University of Medical Sciences, Mashhad, Iran

⁴ Cardiologist, Member of Cardiovascular Research Center, Ghaem Hospital, School of Medicine, Mashhad University of Medical Sciences, Mashhad, Iran

⁵ Cardiologist, Member of Preventive Cardiovascular Care Research Center, Imam Reza Hospital, School of Medicine, Mashhad University of Medical Sciences, Mashhad, Iran

⁶ Medical Student, Faculty of Medicine, Mashhad University of Medical Sciences, Mashhad, Iran

ARTICLE INFO

Article type:

Original article

Article history:

Received: 7 Dec 2013

Revised: 31 Dec 2013

Accepted: 4 Jan 2014

Keywords:

Cardiovascular Diseases

Retinal Vein Occlusions

Transthoracic Echocardiography

ABSTRACT

Introduction: Retinal vein occlusion is a common vascular disorder disrupting vision. Two basic types of RVO are branch retinal vein occlusion and central retinal vein occlusion (CRVO). Retinal vein occlusion is a multifactor process including systemic illness and local retinal factors. RVO may be associated with atherosclerotic risk factors. We analyzed the role of 2 dimensional transthoracic echocardiography (TTE) for detecting the cardiac disease in patients with retinal veins occlusion.

Materials and Methods: In this cross-sectional study 70 recently diagnosed patients with RVO enrolled in the study. The clinical diagnosis of retinal vein occlusion and its type was confirmed by a vitreoretinal specialist. The Patients were then referred for performing complete TTE.

Results: The prevalence of RVO increased with age, but did not vary by sex. The most frequent cardiovascular risk factor was hypertension. The findings of our study revealed that a variety of echocardiographic abnormalities may be presented in patients with RVO. Diastolic dysfunction was the most frequent echocardiographic finding and we found positive correlation between diastolic dysfunction with increasing age and the presence of hypertension. Other findings included mitral regurgitation (52.9%), mitral stenosis (2.9%), mitral annulus calcification (1.4%), mitral valve prolapse (8.6%), aortic insufficiency (22.9%), sclerotic aortic valve (27.1%), tricuspid regurgitation (45.7%), pulmonary insufficiency (8.6%), mild pulmonary hypertension (8.6%), and moderate to severe pulmonary hypertension (4.3%) Mild LVH (11.4%), Moderate LVH (8.6%). Abnormality on IAS was defined in these patients, including patent foramen ovale, lipomatosis IAS, exaggerated motion of IAS, and aneurysm of IAS.

Conclusion: In our study, the most common echocardiographic finding was diastolic dysfunction which was compatible with the patients' age and the fact that the most prevalent risk factor was hypertension. Other findings were not more prevalent than general population. We think that a routine workup for structural heart diseases is unwarranted in these patients.

► Please cite this paper as:

Fazlinezhad F, Banaee T, Azari A, Bigdelu L, Amini M. Role of Transthoracic Echocardiography in the Evaluation of Patients with Retinal Vein Occlusion. *J Cardiothorac Med.* 2014; 2(1): 127-133.

Introduction

Retinal vein occlusion (RVO) is the second most common type of retinal vascular disorders after diabetic retinal disease. The condition can occur at any age but is uncommon under the age

*Corresponding author: Leila Bigdelu, Cardiology Department, Ghaem Hospital, Ahmad Abad Street, Mashhad, Iran. Tel: +985118012739; Fax: +985118012739; Email: bigdelul@mums.ac.ir

© 2014 *mums.ac.ir* All rights reserved.

This is an Open Access article distributed under the terms of the Creative Commons Attribution License (<http://creativecommons.org/licenses/by/3.0>), which permits unrestricted use, distribution, and reproduction in any medium, provided the original work is properly cited.

of 60 and it becomes more frequent later in life. Occlusion can occur in the central retinal vein and affects the entire venous blood supply of the retina (Central Retinal Vein Occlusion or CRVO) or one of the branches of the central retinal vein (Branch Retinal Vein Occlusion or BRVO). Both entities are heralded by sudden painless visual loss in the affected eye, which is usually more severe in CRVO. Diagnosis is basically clinical, based on ophthalmoscopic findings which include retinal hemorrhages, edema and ischemia (cotton wool spots), and the presence of venous engorgement and tortuosity. These signs occur across the entire retina in CRVO, and are sectorial in BRVO. The exact cause is unknown but many of affected patients have vascular risk factors—most commonly, hypertension. Other weaker risk factors include diabetes mellitus (DM), dyslipidemia, smoking, obesity, and hemostatic factors (1). The exact pathophysiology of the disease is still not clear, but as the central retinal vein and artery have a common adventitial sheath within the optic nerve, and occlusion in CRVO occurs in this region, it has been hypothesized that atherosclerosis of the central retinal artery, a medium sized artery, may cause compression on the accompanying vein with resultant turbulent intra-luminal flow, endothelial cell injury and thrombus formation. The same pathophysiology has been proposed for BRVO, but as in the retina, the only site where an artery and its accompanying vein have a common adventitial sheath is at the arteriovenous crossings. The site of occlusion in BRVO is usually at the arteriovenous crossing sites. Other less common causes including: venous wall disease, inflammation in the adjacent retina (retinitis), and thrombophilia; have been proposed as predisposing factors for retinal vein occlusions (2).

So RVO is related to cardiovascular risk factors. But its association to the cardiac structural disease is not well understood. In this study, we aimed to evaluate echocardiographic findings in patients with retinal vein occlusion.

Materials and Methods

Patients' selection

Consecutive cases of retinal vein occlusion presenting to Khatam-Al-Anbia Eye Hospital, from September 2010 to November 2012 were recruited in prospective study. All patients underwent complete ophthalmic examination. The clinical diagnosis of retinal vein occlusion and its type was confirmed by a vitreoretinal specialist. The Patients were then referred for cardiovascular evaluation as a component of standard work up in CRVO.

Patients who did not consent to perform

echocardiography and patients with suboptimal two dimensional images did not include in this study.

The Patients' demographic information and cardiovascular risk factors were recorded. Cardiovascular risk factors were defined as follows: (1) history of hypertension included systolic blood pressure of at least 140 mmHg or diastolic blood pressure of at least 90 mmHg within 24 hours of admission (2) DM was defined as symptoms of diabetes plus a random plasma glucose concentration greater than 200 mg/dL or prior diagnosis of DM before admission, (3) total cholesterol level more than 200 mg/dL or triglycerides exceeding more than 150 mg/dL within 24 hours of admission was determined as hyperlipidemia, and (4) a history of smoking was defined as pipe, cigarette, tobacco and cigar use. Carotid ultrasonography was performed in 26 patients.

Echocardiography

Echocardiograms were obtained using Philips Envicor-C with 2.5-3.5 MHz probe by experienced cardiologist during the first month of RVO diagnosis. We used B-mode, M-mode, color Doppler or the contrast echo. Left ventricular (LV) size and wall thickness and left atrium (LA) diameter were measured in the parasternal long axis view on M mode. LV ejection fraction (LVEF) was calculated in the parasternal view on M-mode and in apical 2- and 4-chamber views on 2 dimensional (2-D) mode using the Simpson rule. All valves were evaluated for presence of stenosis, regurgitation, calcification, sclerosis, and rheumatismal changes. Severities of valve stenosis or regurgitation were estimated with respect to the standard echocardiographic guidelines. The morphology of aortic valve was evaluated by high-frequency, high resolution of the valve in multiple views(3). Aortic valve sclerosis was defined as abnormal focal irregular thickening of a trileaflet aortic valve without stenosis or commissural fusion (at least one leaflet per valve was involved). The antegrade velocity across the sclerotic aortic valve is less than 2.5 m/s (4, 5). Patients also were evaluated for congenital cardiac anomaly and agitated saline contrast injection method was used for ruling out of patent foramen ovale (PFO) with or without the Valsalva maneuver. PFO was diagnosed if a right-to-left atrial shunt was detected by color Doppler or by the contrast echo method. We evaluated LV diastolic function with mitral inflow velocities (E, A) pattern, which usually can be defined as various stages of diastolic dysfunction. Systolic pulmonary artery pressure (SPAP) measured with echocardiog-

raphic parameters. Ascending aorta and aortic arch were also evaluated for detection of calcification.

Statistical analysis

All data analysis was performed using SPSS statistics 16.0 for Windows. All data were presented as mean ± SD for continuous variables. Baseline demographics and clinical characteristics were compared between different groups using independent samples t-test, Mann-Whitney U test, chi-square and/or Fisher’s exact test, as appropriate. Bivariate correlations were assessed using Pearson’s and Spearman’s correlation coefficients for normally and non-normally distributed data, respectively. A probability value of < 0.05 was considered significant for all data analysis.□

Results

Baseline characteristics

The patients’ baseline characteristics are summarized in Table 1. There were 36 females (51.4%) and 34 males (48.6%) (*P*. 0.687), with a mean age of 57.9±14.1 years. The relative prevalence RVO increased with age Figure 1). Thirty-one patients (44.3%) had CRVO and 39 patients (57.7%) had BRVO. Left, right, and both eyes were affected in 36, 32, and 2 patients, respectively.

Table 1. Cardiovascular risk factor of 70 patients with retinal vein occlusion

	Female (36) N (%)	Male (34) N (%)	Total (70) N (%)	<i>P</i> value
Hypertension	14(38.9)	18(52.9)	32(45.7)	N0.238
Diabetes mellitus	6(16.7)	7(20.6)	13(18.6)	0.673
Dyslipidemia	14(38.9)	13(38.2)	27(38.6)	0.951
Smoking	4(11.1)	8(23.5)	12(17.1)	0.168

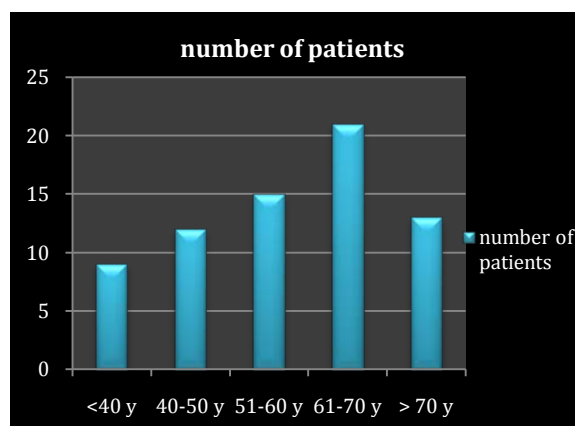


Figure 1. The relative prevalence of retinal vein occlusion with age

Review of the patients’ medical records revealed that the most common cardiovascular risk factor was hypertension then hyperlipid-

emia, and DM (Table 1). There was no significant statistical difference in both genders regarding the prevalence of atherosclerotic risk factors. There was a significant positive association between increasing age and increasing the prevalence of hypertension in both genders. Hypertension was significantly more prevalent with increasing of age (*P*. 0.009).

In our study, there was no previous history of peripheral or central vascular diseases. Doppler examination of the carotid arteries, performed in 26 patients, revealed atherosclerotic plaque in 61.5% of them. There was no significant association between presence of atherosclerotic plaque and type of venous occlusion (CROV vs. BRVO *P*, 0.689).

Echocardiographic results

Left ventricular systolic and diastolic function

There was no left ventricular systolic dysfunction. Mean LV ejection fraction was 55±34%. Echocardiographic finding are summarized in Table 2 and categorized in 3 groups (total patient with RVO, 2 sub-groups of patients with BRVO, and CRVO). Diastolic dysfunction was the most frequent echocardiographic finding in our study, but according to this fact that the diastolic dysfunction can be a normal finding at the age of 65 years, after excluding this group of patients, the prevalence of diastolic dysfunction was 50%. There was also a significant statistical relationship between the diastolic dysfunction with age of more than 60 years and systemic hypertension (*P*. 0.02 and 0.00, respectively). In our study, we did not find significant statistical association between diastolic dysfunction and other risk factors Table 2.

Table 2. Correlation between diastolic dysfunction and other factors.

Characteristics	Presence of diastolic dysfunction N (%)	Absence of diastolic dysfunction N (%)	<i>P</i> value
Female	24(46.2)	12(66.7)	0.13
Male	28(53.8)	6(33.3)	
Hypertension	24(46.2)	4(22.2)	0.02
Diabetes mellitus	11(21.2)	2(11.1)	0.49
Dyslipidemia	20(38.5)	7(38.9)	0.97
Smoking	8(15.4)	4(22.2)	0.49
Age > 60 year	32(61.5)	2(11.1)	0.00
Age ≤ 60 year	20(38.5)	16(88.9)	

Left ventricular hypertrophy

LV wall thickness was normal in 45.7% of patients and the rest of them had left ventricular hypertrophy (Table 3).

Valvular study

Twenty-four patients (34.3%) had no valvular dysfunction and the most frequent valvular

Table 3. Echocardiographic Findings

Echocardiographic findings	CRVO (31) N (%)	BRVO (39) N (%)	RVO (70) N (%)	P value
Diastolic dysfunction				
Normal	7(22.6)	11(28.2)	18(25.7)	0.786
I	22(71.0)	27(69.2)	49(70.0)	
II,III	2(6.4)	1(2.6)	3(4.3)	
Valvular dysfunction				
Mitral regurgitation	15(48.4)	22(56.4)	37(52.9)	0.732
Mitral stenosis	0(0)	2(5.1)	2(2.9)	0.499
Mitral annulus calcification	0(0)	1(2.6)	1(1.4)	1.0
Mitral valve prolapse	2(6.5)	4(10.3)	6(8.6)	0.687
Aortic insufficiency	27(83.9)	28(71.8)	16(22.9)	0.211
Aortic stenosis	0(0)	0(0)	0(0)	
Sclerotic aortic valve	8(25.8)	11(28.2)	19(27.1)	0.823
Tricuspid regurgitation	14(45.2)	18(46.2)	32(45.7)	0.934
Pulmonary insufficiency	2(6.5)	4(10.3)	6(8.6)	0.687
pulmonary or tricuspid stenosis	0(0)	0(0)	0(0)	
Pulmonary artery pressure				
Normal	26(83.9)	35(89.3)	61(87.1)	0.831
Mild pulmonary hypertension	3(9.7)	3(7.7)	6(8.6)	
Moderate-Severe pulmonary hypertension	2(6.4)	1(2.6)	3(4.3)	
Inter ventricular septum thickness				
Normal	17(73.9)	15 (65.2)	32(45.7)	0.720
Mild LVH	3(13.0)	5(21.7)	8(11.4)	
Moderate LVH	3(13.0)	3(13.0)	6(8.6)	
Abnormality of IAS				
Atrial septal defect	0(0)	0(0)	0(0)	0.320
Paten foramen ovale	6(19.4)	4(10.3)	10(14.3)	
Lipomatosis IAS	1(3.2)	2(5.1)	3(4.3)	
Exaggerated motion of IAS	4(12.9)	8(20.5)	12(17.1)	0.400
Aneurysm of IAS	2(6.5)	4(10.3)	6(8.6)	0.680

IAS: Inter atrial septum; LVH: left ventricular hypertrophy.

dysfunction was mitral regurgitation and tricuspid regurgitation respectively. Sclerotic aortic valve was observed in 19 patients of which 9 patients were female and 10 patients were male. Aortic sclerosis had significant statistical association with age more than 60 year and presence of systemic hypertension (P . 0.01 and 0.02, respectively). Systolic pulmonary artery pressure was normal in the most of patients (87.1%) and severe pulmonary artery hypertension was observed only in 1.4% of patients.

Inter atrial septum anomalies (IAS)

The most common abnormality was exaggerated motion of IAS (17.1%). The presence of patent foramen ovale was evaluated by contrast injection or color Doppler study and it was found in 14.3% of patients.

Discussion

RVO and cardiovascular risk factors

RVO most commonly affects middle-aged to older patients. The overall prevalence of RVO is about 1.1 % (0.9% for branch RVO and 0.2% for central RVO) in the general population (2). The prevalence of RVO increases with age, but does not vary by sex. We found similar findings in our study but the mean age of our patients was lower than other studies (6, 7). It may be due to the selection biases as the elderly patients might have not attended for cardiovascular evaluation

in this study, as most of them have previously been under the care of another cardiac specialist and have chosen to refer to that facility for more work up. Cheung and collages evaluated the relationship of retinal vein occlusion and the cardiovascular risk factors in a large population-based sample of middle-aged and elderly people. After adjusting for age, they found that retinal vein occlusion was associated with hypertension, higher systolic or diastolic blood pressure, old age, hypertriglyceridemia, and renal dysfunction. Retinal vein occlusion was additionally associated with increased body mass index. RVO was not significantly associated with direct factors of subclinical atherosclerosis (e.g., carotid intima media thickness and coronary artery calcium scores) or markers of inflammation (e.g., C reactive protein, interleukin-6) and endothelial dysfunction (e.g., soluble intercellular adhesion molecule-1) or coagulation (e.g., D dimer) (7). In our study, the prevalence of RVO increased with age and there were no gender preference. The most frequent cardiovascular risk factor was hypertension (45.7%). The other risk factor included dyslipidemia (38.6%), diabetes mellitus (18.6%), and smoking (17.1%). Atherosclerotic carotid plaques have been showed to be associated with cardiovascular risk factors and mortality (8). Twenty-six patients were also underwent carotid ultrasonography and atherosclerotic plaque was found in 61.5% of them and it

may be related to the presence of atherosclerotic risk factors.

Systolic and diastolic function and LV Hypertrophy

Two dimensional TTE is an easily available diagnostic modality used for evaluating of cardiac diseases but none of the echocardiographic findings had high sensitivity and specificity for the detection of coronary artery disease and screening or risk assessment of coronary atherosclerosis in the absence of infarction and regional wall motion abnormalities(9). The evaluation of left ventricular diastolic function is an essential part of a routine echocardiographic examination. The various stages of diastolic dysfunction can be detected by Doppler echocardiography. Diastolic dysfunction can occur in systemic hypertension, valvular diseases, coronary artery disease and it can also be normal finding in the elderly people (10, 11). Hypertension is a common cause of diastolic dysfunction because of high prevalence of hypertension in most societies and resultant LV wall hypertrophy. Our study was performed in middle-age patients and the most prevalent risk factor was hypertension, so diastolic dysfunction was the most frequent echocardiographic findings and such as other studies, we found positive correlation between diastolic dysfunction with increasing age and the presence of hypertension (12).

Valvular dysfunction or abnormality

The leakage of blood from the left ventricle into the left atrium is called mitral regurgitation (MR). MR has various structural or functional etiologies but the most common causes of MR include myxomatous mitral changes, coronary heart disease, rheumatic heart disease, and chordal rupture (13). Although significant mitral valve regurgitation is seen in about 2% of the population, the prevalence of mild MR is about 70 to 80% in general population. Thus the prevalence of MR was not higher than general population.

In mitral stenosis (MS), the orifice of mitral valve was narrowed and the impedance of the left ventricular filling is increased. Rheumatismal heart disease is the common cause of MS but severe calcification of the mitral annulus, rheumatoid arthritis, carcinoid heart disease can also cause stenosis. Although it is still a major cause of valvular disease in our country but the prevalence of rheumatismal MS in our study was not higher than general population.

Mitral valve prolapse (MVP) is the systolic billowing of one or both mitral leaflets into the left atrium during systole, occurring in 2.4% of

the general population. It could be viewed in either myxomatous or normal mitral valve leaflets(14). In our study, the prevalence of MVP was 8.6% and it was more prevalent than the general population.

Aortic regurgitation is the result of aortic root dilatation as a major cause or as a result of aortic valve diseases. Aortic root diameters at all levels were related to age, height, weight, body surface area, and the presence of hypertension (15). Aortic regurgitation of any severity was found in 22.9% of the study subjects and we think the most important cause for its prevalence is senile age and presence of hypertension as cause of aortic root dilatation.

AVS is a common echocardiographic finding in the elderly and it was found in 26% , 37% , and 48% of those over age 65 , 75, and 85years, respectively (16, 17). Some studies revealed that AVS causes increasing in all-cause of cardiovascular mortality (16, 18, 19) and the others reported that the development of AVS is correlated with the atherosclerotic risk factors including male gender, age, dyslipidemia, hypertension, smoking, and diabetes mellitus and it shares many essential risk factors with atherosclerosis (4, 20). There are also some clinical situations associated with AVS such as end stage renal disease, Paget disease, and hyperparathyroidism. Taylor et al reported that the increased risk of cardiovascular mortality and morbidity associated with AVS was not dependent on the presence of established cardiovascular risk factors. The exact mechanism of increased cardiovascular mortality that is associated with AVS is not defined yet. The potential mechanisms include: systemic inflammation, dystrophic calcification, and endothelial dysfunction (20, 21). In the present study, the prevalence of AVS was 27.1% among study population and it may be most probably associated with old age of the study group and the presence of multiple risk factors.

Tricuspid and pulmonary valve regurgitation is presence in up to 80 to 90% and 70 to 80 % of normal population, respectively and in our study; their prevalence wasn't more than normal subjects.

Pulmonary artery pressure

The pulmonary artery pressure can also be measured by echocardiography technique. Pulmonary arterial hypertension was defined as mean pulmonary artery pressure more than 25mmHg at rest with a pulmonary capillary wedge pressure less than 15mmHg. There are various disorders which can cause pulmonary hypertension, including intra-cardiac shunts,

connective tissue disorders and pulmonary diseases. All of the 3 patients who had moderate to severe pulmonary artery pressure were heavy smokers. We think smoking was the most important cause of pulmonary artery hypertension in these patients.

Abnormality of IAS

The foramen ovale is a tunnel-shaped space between the overlying septum secundum and septum primum of the atrium. It usually closes in 75% of normal subjects at birth but a patent foramen ovale (PFO) can persist into adulthood in up to 25% of people. PFOs have been implicated in the pathophysiologic mechanism of cryptogenic stroke. There are two probable causes for the occurrence of stroke. PFO may serve as a tunnel that connects the two atria, which can cause thrombosis in the right heart circulation moving into the systemic circulation. It is also hypothesized that tunnel-like structure of PFO may be a nidus for in situ thrombus formation and paradoxical embolization(22, 23). It can be hypothesized that PFO can be a source of emboli to the retinal vein but in our study, the prevalence of PFO was not higher than the healthy subjects. Exaggerated motion of IAS and aneurysm of IAS was found in 17.1% and 8.6% of patients respectively and it may be a predictor of the presence of ASD and PFO but we have no case of ASD in our evaluation.

Lipomatosis IAS is a non-encapsulated mass of fatty tissue the inter-atrial septum. It is a rare benign tumor which was incidentally recognized at the time of cardiac imaging or surgery. The incidence of lipomatosis IAS was about 1% to 8% which was diagnosed at autopsy and by transthoracic echocardiography, respectively. Although it is often an incidental finding in an asymptomatic patient, it can be presented by cardiac arrhythmias such as atrial fibrillation, ectopic atrial rhythm, or Supraventricular tachycardia (24). We found this mass in 4.3% of our patients and it was not higher than the general population and there was no association between this mass and presence of RVO.

Conclusion

This study demonstrates that cardiovascular risk factors, especially hypertension are common in patients with retinal vein occlusion. The most common echocardiographic finding was diastolic dysfunction. Other echocardiographic abnormalities such as LVH and AR were matched with patients' age and risk factors. Thus we think, TEE should not be considered as an adjunct to the systemic workup in patient with RVO.

Acknowledgement

The authors would like to thank vice chancellery of research, Mashhad University of Medical Sciences, Mashhad, Iran and thank Dr. Esmaili for data analysis.

Conflict of Interest

The authors declare no conflict of interest.

References

1. Zhou JQ, Xu L, Wang S, Wang YX, You QS, Tu Y, Yang H, et al. A longitudinal analysis of risk factors associated with central retinal vein occlusion. *Ophthalmology*.120:362-70.
2. Wong TY, Larsen EKM, Klein R, Mitchell P, Couper DJ, Klein BE, et al. Cardiovascular risk factors for retinal vein occlusion and arteriolar emboli: the Atherosclerosis Risk in Communities & Cardiovascular Health studies. *Ophthalmology*. 2005; 112: 540-7.
3. Agmon Y, Khandheria BK, Meissner I, Schwartz GL, Petterson TM, O'Fallon WM, et al. Independent Association of High Blood Pressure and Aortic Atherosclerosis A Population-Based Study. *Circulation*. 2000;102:2087-93.
4. Agmon Y, Khandheria BK, Meissner I, Sicks JD, O'Fallon WM, Wiebers DO, et al. Aortic valve sclerosis and aortic atherosclerosis: different manifestations of the same disease? Insights from a population-based study. *J Am Coll Cardiol* 2001;38:827-34.
5. Lee JC, Zhao X-Q, Otto CM. Aortic valve sclerosis. *Journal of Echocardiography*. 2005;3:51-9. Aortic valve sclerosis. *J Echocardiogr*. 2005;3:51-9.
6. Rogers S, McIntosh RL, Cheung N, Lim L, Wang JJ, Mitchell P, et al. The prevalence of retinal vein occlusion: pooled data from population studies from the United States, Europe, Asia, and Australia. *Ophthalmology*. 2010;117:313-9.
7. Cheung N, Klein R, Wang JJ, Cotch MF, Islam AF, Klein BE, et al. Traditional and novel cardiovascular risk factors for retinal vein occlusion: the multiethnic study of atherosclerosis. *Invest Ophthalmol Vis Sci*. 2008;49:4297-302.
8. Polak JF, Szklo M, Kronmal RA, Burke GL, Shea S, Zavodni AEH, et al. The Value of Carotid Artery Plaque and Intima-Media Thickness for Incident Cardiovascular Disease: The Multi-Ethnic Study of Atherosclerosis. *J Am Heart Assoc*. 2013;2.
9. Greenland P, Alpert JS, Beller GA, Benjamin EJ, Budoff MJ, Fayad ZA, et al. 2010 ACCF/AHA Guideline for Assessment of Cardiovascular Risk in Asymptomatic Adults A Report of the American College of Cardiology Foundation/American Heart Association Task Force on Practice Guidelines Developed in Collaboration With the American Society of Echocardiography, American Society of Nuclear Cardiology, Society of Atherosclerosis Imaging and Prevention, Society for Cardiovascular Angiography and Interventions, Society of Cardiovascular Computed Tomography, and Society for Cardiovascular Magnetic

- Resonance. *Journal of the American College of Cardiology*. 2010;56:e50-e103.
10. Nagueh SF, Appleton CP, Gillebert TC, Marino PN, Oh JK, Smiseth OA, et al. Recommendations for the evaluation of left ventricular diastolic function by echocardiography. *Eur J Echocardiogr*. 2009; 10: 165-93.
 11. Hees PS, Fleg JL, Dong SJ, Shapiro EP. MRI and echocardiographic assessment of the diastolic dysfunction of normal aging: altered LV pressure decline or load? *Am J Physiol Heart Circ Physiol*. 2004;286:H782-H8.
 12. Yip G, Sanderson J. Diastolic dysfunction and hypertension. *N Engl J Med*. 2001; 344:1401.
 13. Jones EC, Devereux RB, Roman MJ, Liu JE, Fishman D, Lee ET, et al. Prevalence and correlates of mitral regurgitation in a population-based sample (the Strong Heart Study). *Am J Cardiol*. 2001;87:298-304.
 14. Hayek E, Gring CN, Griffin BP. Mitral valve prolapse. *The Lancet*. 2005; 365:507-18.
 15. Kim M, Roman MJ, Cavallini MC, Schwartz JE, Pickering TG, Devereux RB. Effect of Hypertension on Aortic Root Size and Prevalence of Aortic Regurgitation. *Hypertension*. 1996;28:47-52.
 16. Otto CM. Aortic stenosis: even mild disease is significant. *Eur Heart J*. 2004;25:185-7.
 17. Fazlinezhad A, Hosseini L, Yousefzadeh H, Akhlaghi S. Correlation Between Aortic Valve Sclerosis and Coronary Artery Disease: A Cross - Sectional Study. *J Cardiothoracic Med* 2013;1:20-5.
 18. Olsen MH, Wachtell K, Bella JN, Gerds E, Palmieri V, Nieminen MS, et al. Aortic valve sclerosis relates to cardiovascular events in patients with hypertension (a LIFE substudy). *Am J Cardiol* 2005;95:132-6.
 19. Taylor Jr HA, Clark BL, Garrison RJ, Andrew ME, Han H, Fox ER, et al. Relation of aortic valve sclerosis to risk of coronary heart disease in African-Americans. *Am J Cardiol*. 2005; 95:401-4.
 20. Novaro GM, Sachar R, Pearce GL, Sprecher DL, Griffin BP. Association between apolipoprotein E alleles and calcific valvular heart disease. *Circulation*. 2003; 108:1804-8.
 21. Poggianti E, Venneri L, Chubuchny V, Jambrik Z, Baroncini LA, Picano E. Aortic valve sclerosis is associated with systemic endothelial dysfunction. *J Am Coll Cardiol*. 2003; 41:136-41.
 22. Fazlinezhad A, Azimi S, Azarpazhooh M, Khajedaluee M, Kashani MM. Patent Foramen Ovale in Young Adults with Cryptogenic Stroke or Transient Ischemic Attack. *J Teh Univ Heart Ctr*. 2009; 4:185-8.
 23. Ebrahimi HA, Moghadam AH, Aredestani E. Evaluation of patent foramen ovale in young adults with cryptogenic stroke. *ARYA atherosclerosis*. 2011; 7:74.
 24. Xanthos T, Giannakopoulos N, Papadimitriou L. Lipomatous hypertrophy of the interatrial septum: a pathological and clinical approach. *Int J Cardiol*. 2007; 121:4-8.