



Surgical Management of Calcified Liver Hydatid Cyst Complicated with Thoracobiliary Fistula: A Case Series and Literature Review

Mohsen Sokouti¹, Abasad Gharedaghi¹, Seyed Ziaeddin Rasihashemi^{1*}, Sina Zarrintan²

¹ General Thoracic Surgeon, Department of Cardiothoracic Surgery, Imam Reza Hospital, Tabriz University of Medical Sciences, Tabriz, Iran

² General Surgeon, Department of General & Vascular Surgery, Imam Reza Hospital, Tabriz University of Medical Sciences, Tabriz, Iran

ARTICLE INFO

Article type:
Case Report

Article history:
Received: 27 Dec 2015
Revised: 5 Apr 2016
Accepted: 6 Apr 2016

Keywords:
Calcification
Hydatid Cyst
Liver
Thoracobiliary Fistula

ABSTRACT

Thoracobiliary fistula is a rare complication of hydatid cyst of the liver especially in the calcified form. Surgery is the only medical option. The treatment consists of radical surgical procedures in the majority of the patients. Conservative surgical treatments are performed with high mortality rate. Herein, we will describe two patients of calcified hydatid cysts of the liver whose condition becomes complicated with Thoracobiliary fistula.

The first patient was treated with right thoracotomy and resection of pleural hydatid cysts. Then, were evacuated the ruptured laminated membrane and daughter cysts of infected hepatic hydatid cysts through diaphragmatic opening and sub diaphragmatic drainage of the calcified liver hydatid cyst. The second patient was also treated with right thoracotomy, resection of pulmonary hydatid cysts, evacuation of ruptured bile stained laminated membrane and daughter cysts of hepatic hydatid cysts through diaphragmatic opening and sub diaphragmatic drainage of the calcified cyst cavity.

Our patients underwent conservative surgery which posed a severe risk. Both cases are discussed together with review of the literature.

► Please cite this paper as:

Sokouti M, Gharedaghi A, Rasihashemi SZ, Zarrintan S. Surgical Management of Calcified Liver Hydatid Cyst Complicated with Thoracobiliary Fistula: A Case Series and Literature Review. *J Cardiothorac Med.* 2016; 4(2):456-460.

Introduction

Hydatid disease is an old parasitic infection caused by *Echinococcus Granulosus* which is endemic in Mediterranean area, Australia, New Zealand and The Middle East. The definitive hosts are usually dogs and other carnivores. Sheep are intermediary hosts. Human are accidentally involved if they are in touch with such intermediary hosts. Hexacanth Embryo which is released from an ingested ovum passes through the intestinal wall into the portal circulation and develops a cyst inside the liver. Visceral ingestion

of the intermediary host with the definitive host completes the life cycle of Echinococcosis. In some cases, the parasite remains viable and cysts continue to grow while necrosis or calcifications are added (1).

Echinococcal cysts in the liver and lung can lead to complications such as Thoracobiliary fistula to some extent. Calcified hydatid cyst of the liver being complicated by thoracobiliary fistula is an extremely rare complication of the Echinococcosis. The incidence is 1%- 2% in the

*Corresponding author: Seyed Ziaeddin Rasihashemi, Department of Cardiothoracic Surgery, Imam Reza Hospital, Tabriz University of Medical Sciences, Tabriz, Iran. Tel: 00989144126652; Fax: 00984133341317; Email: zia.hashemi@yahoo.com

© 2016 *mums.ac.ir* All rights reserved.

This is an Open Access article distributed under the terms of the Creative Commons Attribution License (<http://creativecommons.org/licenses/by/3.0>), which permits unrestricted use, distribution, and reproduction in any medium, provided the original work is properly cited.

literature (2). Peacock reported the first case of hepatic extension of hydatid cyst to bronchial openings in 1850 (3).

However, far too little attention has been paid to thoracic complications of calcified liver hydatid cyst in the literature.

In this report, we aimed to determine our own experience in managing two patients of calcified hydatid cyst of the liver complicated with thoracobiliary fistula. We also reviewed the literature and the surgical treatments of the aforementioned patients.

Case presentation

Patient 1: A 54-year-old man who had a history of pulmonary and pleural hydatid cyst in the past five years was referred to our hospital with a pain on the right side of his chest, fever and recurrence of the disease. Blood and serologic investigations showed the following results:

White Blood Cell count was $10500/\text{mm}^3$ with 4% eosinophil count, negative Casoni test, Erythrocytes Sedimentation Rate 32mm/1 hour and 49 mm/2 hour. Indirect test for Echinococcosis antibody IgG was positive. CT-scan and chest x-ray showed enlarged homogenous and complete calcified hydatid cyst of the liver (segments of 7, 8) with $11 \times 10 \times 9$ cm dimension and pleural and pulmonary hydatid cysts (Figure 1). Ultrasonography of biliary system was normal with 7mm diameter of common bile duct. He underwent right standard Posterolateral Thoracotomy to remove pleural and pulmonary hydatid cysts and a large amount of bile stained daughter cysts were found in the right lower pleural spaces of thoracotomy. On exploratory thoracotomy, the pleural cysts penetrated the lower segments of

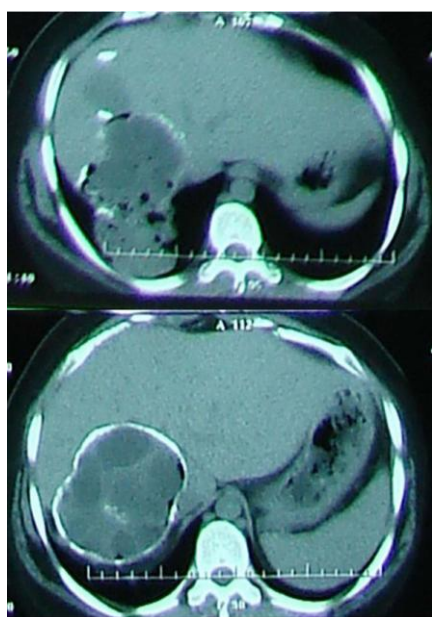


Figure 1. Chest CT scan showing large calcified hydatid cyst of the liver and pleuropulmonary hydatid cysts

the lung and were removed with no bronchobiliary fistula. The cysts emerged from the calcified infected hydatid cyst of the liver through one diaphragmatic opening with $3 \times 3 \times 4$ cm dimension. The diaphragmatic opening was augmented and all of the infected and ruptured daughter cysts were extracted from the calcified liver cyst. Major parts of calcified pericyst layer were removed and biliary openings were closed by delayed absorbable suture (3-0 Vicryl, Ethicon). Due to the infection of cystic bile fluid, the cavity was irrigated with 20% saline solution and drained with 22 French Foley catheter sub diaphragmatically. The diaphragmatic opening was closed in two layers and upon the insertion of two chest tubes, the chest wall closed permanently. Regular postthoracotomy care was provided in ICU, including the administration of ceftriaxone and Metronidazole as well as controlling the patient's analgesic. Chest tubes were removed on day 5 and irrigation of the cystic cavity continued after discharge.

In the controlled CT-scan of the abdomen during the third month, the calcified hydatid cyst was collapsed. Thus, the patient was treated with drainage of Pus which continued for an 18-month follow-up period. The follow-up required appropriate antibiotics. Medical chemotherapy with Albendazole 800 mg/day continued for the next six months. Histopathologic examination revealed hydatid cyst with a substantial amount of ruptured bile stained laminated membranes. Generally, the patient did not benefit from the type of management.

Patient 2: A 27-year-old woman was presented with chronic cough and pain on the right side of the chest for three years. Blood and serologic investigations showed the following results:

White Blood Cell count was $11800/\text{mm}^3$ with normal eosinophil count, positive Casoni test, Erythrocytes Sedimentation Rate 26mm/1 hour and 48mm/2 hour. Indirect test for Echinococcosis antibody IgG was positive. CT-scan of the chest showed right lower lobe hydatid cyst (68×62 mm) and completely homogenous calcified liver hydatid cyst 97×77 mm located in the right liver lobe subdiaphragmatically (Figure 2). Ultrasonography of biliary system was normal. She was admitted in our hospital in December 2010 and prepared for surgery.

Right posterolateral thoracotomy was carried out and pulmonary bile stained hydatid cyst of the right lower lobe in the 8th segment was evacuated. Bronchial openings were closed by 3-0 vicryl. fistula was disconnected. All of the ruptured daughter cysts of the calcified hydatid cyst of the liver were evacuated. The cavity was irrigated with 20% normal saline and then drained sub-diaphragmatically, while the diaphragmatic

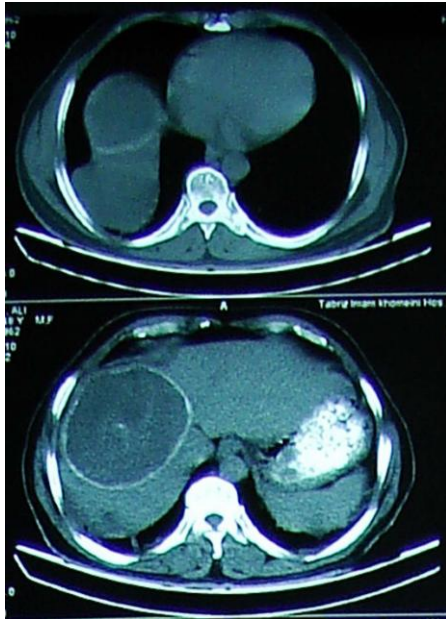


Figure 2. CT scan of the chest showing right lower lobe pulmonary hydatid cyst, and large calcified hydatid cyst in the right liver lobe

opening was closed in two layers through the same incision. Liver cavity was drained separately through sub-diaphragm by a Folly catheter. The pleural cavity was drained by two chest tubes. There were no intraoperative complications. The chest tubes were removed on day 4 and the patient was discharged on day 7 after surgery. However, she was admitted again because of pneumothorax and continuous bile drainage on day 34 after surgery. Upon the insertion of the chest tubes, she was scheduled for sphincterotomy by Endoscopic Retrograde Cholangiopancreatography (ERCP). Because of massive air leak, right posterolateral thoracotomy was performed first and pneumothorax was controlled by inferior lobectomy of the lung. After Sphincterotomy drainage, bile leakage from cyst cavity was stopped on day 51. She was treated with Albendazole 800 mg/day for six months after her surgery. Pus drainage of cyst cavity was stopped during the next four months. Histopathologic examination revealed hydatid cyst with plenty of ruptured bile stained scolices. The one-year follow-up period of the patient was satisfactory.

Discussion

Thoracobiliary fistula is an abnormal communication between the biliary system and thoracic cavity. Compromised perfusion of the diaphragm, secondary to inflammation of pericyst, the action of bile on diaphragm and the pressure gradient between pleural and abdominal cavities are factors contributing to produce sinus tract communication between the biliary and thoracic space (4, 5). As the same mechanism, thoraco-

biliary fistula can be produced in calcified liver hydatid cyst. Thoracobiliary fistula is associated with high mortality rate and to the present day, many extensive radical surgeries have been proposed in this regard. Some examples are pulmonary resection, decortication, partial hepatectomy, total or partial Pericystectomy, biliary closure with or without capitonage of the liver and bile drainage with Sphicterotomy (T-tube drainage). Such procedures are performed by standard thoracotomy, Thoracoabdominal and abdominal combined with thoracotomy incisions (1). Conservative treatments of thoracobiliary fistula are suggested by a number of authors and are applied to less invasive procedures such as the drainage of the cyst cavity, Marsupialization, Omentoplasty and Sphicterotomy. Nevertheless, high morbidity rate and failure have been reported (4).

For unknown reasons, some hepatic hydatid cysts stop growing, degenerate and undergo calcification. Calcification of the hepatic hydatid cyst occurs in about 10% to 16.6% of the cases and there has been little discussion about it in the literature (5).

Clinically speaking, the disease is characterized with chronic coughing, right shoulder pain, fever and bile stained sputum in bronchobiliary types. Bronchoscopy and bronchography rarely show the fistula and are not essential for an accurate diagnosis (3). Abdominal ultrasound is necessary to show the morphology of the liver cyst and possibly, the biliary tree obstruction. Computed tomography aids to differentiating the relationship between the cyst and blood vessels, helping to identify the surgical approach options (6).

Calcification of pericyst layer of hydatid cyst of the liver, right lower lobe pneumonia, atelectases and hourglass-shaped lesion in the lateral projection of chest x-ray with or without pleural effusion are radiologic features of calcified liver hydatid cyst being complicated with thoracobiliary fistula. Calcification of the cyst is easily detected by CT, but MRI is superior in detecting all irregularities of the calcification rim (1, 2).

In many cases, the definitive surgery for Thoracobiliary fistula includes the removal of the fistula tract, calcified pericystectomy and hepatectomy. In case the pulmonary tissue is destroyed by necrotizing pneumonia, it might require a wide resection of all damaged pulmonary tissues (7).

In reviewing literature, Prousalidis and associates studied 75 patients of symptomatic calcified liver hydatid cyst without thoracobiliary fistula. Their treatment consisted of relatively aggressive procedures such as cystopericystectomy, pericystectomy and limited removal of the calcification as well as the capitonage of

cyst cavity or omentoplasty and myoplasty which resulted in good (5).

According to Tocchi's study on 31 patients with thoracobiliary fistula of the liver hydatid cyst, their surgical access was confined to Laparotomy at first. Subsequently, thoracotomy or thoracoabdominal incisions were applied as well. The patients were grouped into conservative and radical surgery treatment groups. However, the number of cases with calcified thoracobiliary fistula has not been mentioned.

In their study, radical surgery with thoracoabdominal approaches was recommended while conservative treatment was associated with such postoperative complications as infection and recurrence of disease (8).

On the other hand, a number of surgeons recommend radical surgeries for thoracobiliary fistula through thoracotomy. Francoise and colleagues believed that radical surgery bears a noticeable degree of morbidity with no certain mortality. Conservative surgery still plays a pivotal role in the process of treatment (9, 10).

Kabiri, Kilani and Gerazounis, in their studies carried out on large series of 123, examined 40 and 21 patients who underwent thoracotomy for thoracobiliary fistula. They suggested that using thoracotomy would restrict proper access to the disconnection of the fistula, decortication, segmental resection, pulmonary lobectomy and pericystectomy with biliary opening closures and hepatic resections. Radical surgery is also recommended for both calcified and noncalcified thoracobiliary fistulae (6, 7, 11).

A new procedure consisting of cyanacrylate glue Embolization of fistula through bronchoscopy has also come to attention. However, a few of its side effects such as foreign body reactions, infection and bronchiectasis have caused the method's rare usage (12).

Radical surgery and pericystectomy of calcified hydatid cyst of the liver is not risk-free. If calcification reaches over the inferior vena cava, hepatic veins or hilum of the liver, extra measures must be taken to avoid damaging great vessels. In the hands of an experienced surgeon, pericystectomy of calcified pericyst layer through thoracotomy can be safe. Controlling intraoperative bleeding is probable. However, due to technical difficulties associated with resection or pericystectomy, sometimes thoracoabdominal procedure might be required (8). Postoperative bile leak into cyst cavity following surgery is common and it is necessary to reduce mean basal pressure of common bile duct with T-tube drainage or sphincterotomy by either surgery or ERCP to prevent recurrence of thoracobiliary fistula (12, 13). In their study 2 from 8 patients needed T-tube drainage and one patient needed

sphincterotomy.

Like the above highlighted review of the literature, our patients who were treated with radical surgery obtained remarkable results. Although aggressive surgery is dangerous and might be associated with massive intraoperative bleeding, it proves to be more effective (14).

The prognosis of our two presented patients who were treated with conservative surgery of calcified hydatid cysts became complicated with thoracobiliary fistula. Thus, the procedure was not satisfactory due to the prolonged management of morbidity.

Our study was carried out on the surgical treatment of liver hydatid cyst in the endemic area. Since there has not been any clear, separate study on the surgical treatment of pure calcified hydatid cyst complicated with thoracobiliary fistula, we could compare surgical results of calcified and noncalcified liver hydatid cyst in the literature. Comparison was mostly carried out with the results of liver hydatid cyst and probably the calcified form which had been complicated with thoracobiliary fistula (authors in the literature did not mention how many of their patients are of the calcified form). The calcified form is a noticeably different condition which requires further study on its surgical treatment with multicenter studies in endemic area.

In our study, all thoracobiliary disconnections, pulmonary resections and decortication were performed through thoracotomy. Pericystectomy of calcified layer, liver resections and hepatic lobectomy were performed through thoracotomy. We concluded that one out of four patients needs T-tube insertion into common bile duct via right thoracotomy (14).

Tocchi's series of surgical access consist of thoracotomy or thoracoabdominal incisions for radical treatment of such conditions as lung resection and Pericystectomy. Occasionally, laparotomy was performed for pericystectomy and drainage of cysts and more success was achieved through thoracoabdominal incisions (8).

Gerazounis, Kabiri, Killani and Tierris used the transthoracic approach for pulmonary lesions, total evacuation and debridment of the cysts. Laparotomy was carried out for intraoperative injury to inferior cava and resection of enlarged gallbladder or gallstone, liver resections and T-tube insertion (6, 7, 10, 11).

Pecker's study proposed surgical treatment for thoracobiliary fistula and in fewer cases, it is claimed that it could be treated nonoperatively (4).

The results of our conservative surgical treatments were similar with the literature through abdominal, thoracic, or thoracoabdominal incisions and cyst drainage via sub diaphragm.

In the literature, hepatic lobotomies were carried out via laparotomy but our left hepatic lobectomy was carried out transdiaphragmatically through thoracotomy incision.

The reported mortality rate of the literature is 2%-43%, with higher morbidity rate (6, 11, 15). The rate of recurrence was significantly lower after radical surgeries (9).

There was no mortality or recurrence in our two patients with calcified thoracobiliary fistula who were treated with radical surgery (14). These two recent presentations, which were treated conservatively, had high morbidity with poor results.

Conclusion

Calcified hydatid cyst of the liver complicated with thoracobiliary fistulae requires treatments similar to noncalcified hydatid cysts. The patients who are treated by radical surgery in our series and the above highlighted patients of the literature experience more satisfying results than those who undergo conservative treatment.

Conflict of interest

The authors declare no conflicts of interest.

References

1. Pedrosa I, Saiz A, Arrazola I, Ferreiros I, Pedrosa CS. Hydatid disease: radiologic and pathologic features and complications. *Radiographics*. 2000; 20:795-817.
2. Bhat S, Kamble RT, Sundaram P, Joshi JM. Transdiaphragmatic extension of hepatic hydatid cyst. *Indian J Chest Dis Allied Sci*. 2002; 44:191-4.
3. Gugenheim J, Ciardullo M, Traynor O, Bismuth H. Bronchobiliary fistula in adults. *Ann Surg* Jan. 1988; 207:90-4.
4. Peker Y, Can MF, Genc O, Gozubuyuk A, Zeybek N, Tufan T. Appropriate approach to bronchobiliary fistula: a cases series with hydatid disease and algorithm of case-based management. *Int Surg*. 2007; 92:239-46.
5. Prousalidis J, Tzardinoglou E, Kosmidis C, Katsolis K, Aletras O. Surgical management of calcified hydatid cysts of the liver. *HPB Surg*. 1999; 11:253-9.
6. Kabiri EH, El Maslout A, Benosman A. Thoracic rupture of hepatic hydatidosis (123 cases). *Ann Thorac Surg*. 2001; 72:1883-6.
7. Gerazounis M, Athanassiadi K, Metaxas E, Athanassiou M, Kalantzi N. Bronchobiliary fistula due to echinococcosis. *Eur J Cardiothorac Surg*. 2002; 22:306-8.
8. Tocchi A, Mazzoni G, Miccini M, Drumo A, Cassini D, Colace L, et al. Treatment of hydatid bronchobiliary fistulas: 30 years of experience. *Liver Int*. 2007; 27:209-14.
9. Aydin U, Yazici P, Onen Z, Ozsoy M, Zeytunlu M, Kilic M, et al. The optimal treatment of hydatid cyst of the liver: radical surgery with a significant reduced risk of recurrence. *Turk J Gastrentrol*. 2008; 19:33-9.
10. Franciosi CM, Romano F, Porta G, Caprotti R, De Fina S, Colombo G, et al. Surgical treatment of hydatid disease of the liver. An experience from outside the endemic area. *Chir Ital*. 2002; 54:667-72.
11. Kilani T, EL Hammami S, Horchani H, Ben Milared-Mrad K, Hantous S, Mestiri I, et al. Hydatid disease of the liver with thoracic involvement. *World J Surg*. 2001; 25:40-5.
12. Chong CF, Chong VH, Jalihal A, Mathews L. Bronchobiliary fistula successfully treated surgically. *Sigapour Med J*. 2008; 49:e208-11.
13. Greenen JE, Tooli J, Hogan WJ, Dodds WJ, Stewart ET, Mavrelis P, et al. Endoscopic Sphincterectomy: follow up evaluation of effects on the sphincter of Oddi. *Gastroenterology*. 1984; 87:754-8.
14. Sokouti M, Montazeri V, Fachrju A. Thoracobiliary fistula of calcified hydatid cyst of the liver. *Iran J Med Sci*. 2010; 35:65-8.
15. Daradkeh S, El-Muhtaseb H, Farah G, Sroujeh AS, Abu-Khalaf M. Predictors of morbidity and mortality in the surgical management of hydatid cyst of the liver. *Langenbecks Arch Surg*. 2007; 392:35-9.