

Histological, Biomechanical and Radiological Evaluation of Bone Repair with Human Platelet Rich Plasma in Rabbit Model

Zahra Shafiei-Sarvestani,¹ Ahmad Oryan,² Abdolhamid Meimandi-Parizi,³ Amin Bigham-Sadegh*¹

1. Department of Veterinary Surgery and Radiology, Faculty of Veterinary Medicine, Shahr-e-Kord University, Shahr-e-Kord, Iran
2. Department of Veterinary Pathobiology, Faculty of Veterinary Medicine, Shiraz University, Shiraz, Iran
3. Department of Veterinary Surgery and Radiology, Faculty of Veterinary Medicine, Shiraz University, Shiraz, Iran

Article information	Abstract
<p>Article history: Received: 9 Dec 2013 Accepted: 25 Dec 2013 Available online: 22 Jan 2014 ZJRMS 2015 Feb; 17(2): 1-6.</p> <p>Keywords: Platelet rich plasma Bone repair Rabbit</p> <p>*Corresponding author at: Department of Veterinary Surgery and Radiology, Faculty of Veterinary Medicine, Shahr- e-Kord University, Shahr-e- Kord, Iran E-mail: dr.bigham@gmail.com</p>	<p>Background: This study was carried out to evaluation the effect of human platelet rich plasma (hPRP) on the bone repair process in rabbit model which could be used in many procedures of orthopedic or maxillofacial bone and implant reconstructive surgery.</p> <p>Materials and Methods: This study is a prospective experimental study on animal model. A critical size defect (10 mm) was created in the radial diaphysis of 24 rabbit and then supplied with human PRP (treatment group) or the defect left empty (control group). Radiographs of each forelimb was taken postoperatively on 1st day and at the 2nd, 4th, 6th and 8th weeks post injury to evaluate bone formation, union and remodeling of the defect. The operated radii were removed on 56th postoperative day and were evaluated for biomechanical properties and histopathological criteria.</p> <p>Results: The results indicate that human PRP (as a xenogenic PRP) in treatment group significantly promote bone regeneration in critical size defects compared with control group ($p < 0.05$).</p> <p>Conclusion: This study showed that hPRP has a high regenerative capacity in critical size bone defects in rabbit model after 8 weeks.</p> <p>Copyright © 2015 Zahedan University of Medical Sciences. All rights reserved.</p>

Introduction

There is a continuing search for bone substitutes to avoid or minimize the need for autogenous bone grafts. The use of bone grafts in the management of nonunion cases is well accepted. These grafts act as scaffolds, which provide the necessary biomechanical strength that is required to withstand the compressive forces involved during motion. They also promote the ingrowth of cells and other biological products, which eventually leads to the replacement of these grafts by bioactive tissues [1]. Autogenic and allogenic bone grafts are commonly used to treat these conditions. However, the limited availability of graft sites and the donor-site morbidity associated with the use of autologous bone grafts have been a major concern. In allogenic bone grafts, concerns over transmissible diseases and risk of contamination remain high, making its use less appealing for patients. Bone grafts are generally made from either biological material, for example, hydroxyapatite or synthetic materials, for example, calcium carbonate. Each of these grafts has unique advantages when used in patients; however, the common deficiency seen in these grafts appears to be in their ability to promote early bone incorporation, which, in turn, translates to late healing. The use of osteogenic promoters includes biological substances, cell therapies and mechanical induction [1]. These therapies are still novel and expensive with the exception of one product: PRP (platelet-rich plasma). PRP is not only easy to obtain and produce, but also safe

[2, 3]. In many literatures, PRP has been used to improve bone healing in the fields of orthopaedic and maxillofacial surgeries; however, reports on the benefits of this material have not been conclusive as there have been contradictory outcomes, which report both good and poor results [2-8]. Clinical studies data were influenced by variables, such as defect size, site and patient factors that were not standardized, whilst the few experimental studies carried out did not demonstrate clearly if the PRP used had comparable concentrations. A study to determine the true effectiveness of PRP in treating non- or delayed union is, therefore, necessary to justify its use in clinical practice. In this study, a standardised technique to treat a delayed union model was performed in phenotypically identical rabbits and assessed for healing using biomechanical, histological and radiological methods to illustrate the role of PRP in enhancing bone healing.

Materials and Methods

Animals and operative procedure: This study is a prospective experimental study on animal model. Twenty four New Zealand white rabbits (12 months old, mixed sex, weighing 2.5 ± 0.5 kg) were prepared from animal house of Shiraz University of Medical Sciences and kept in separate cages, fed a standard diet and allowed to move freely during the study. Rabbits kept in a well-ventilated area, away from draughts, fumes and noise, and at a

temperature $23\pm 2^{\circ}\text{C}$. The animals were randomly divided into 2 equal groups (each group was 12 rabbits) as treated (hPRP) and control. All the animals were anesthetized by intramuscular administration of 40 mg/kg ketamine hydrochloride (Alphasan, Netherlands) and 5 mg/kg xylazine (Alphasan, Netherlands). In all animals the right forelimb was prepared aseptically for operation. A 5 cm skin incision was made over the forearm craniomedially and then the radius was exposed by dissecting the surrounding muscles. A 10 mm segmental defect was then created on the middle portion of each radius as a critical size bone defect [9]. Four days postoperation, 1 mL hPRP was injected percutaneously into the defect of bones in the treatment group [10] while the defects of the animals of the control group were left empty. The animals were housed in compliance with our institution's guiding principles "in the care and use of animals". The study was performed under regulation of Shiraz University as "using animals in scientific procedures" and the Ethics Committee approved the design of the experiment.

PRP preparation: Human PRP was prepared and supplied by the Shiraz blood bank Center. About 500 mL blood from a healthy donor was collected in 70 mL of anticoagulants (citrate-phosphate-dextrose [CPD]) and cooled to about 22°C . Within 24 h of extraction, the blood was separated through centrifugation into erythrocytes, buffy coat (leukocytes and thrombocytes) and plasma. From the buffy coat the leukocytes were removed through filtration, and the isolated fraction of platelets was human PRP. To obtain information on the increase in platelet concentration and the final concentration of platelets in the PRP of the obtained blood, both the whole blood and the prepared PRP were subjected to platelet counts. Platelet counts were performed using a hematology analyzer (Advia 120, Bayer B.V., Mijdrecht, the Netherlands) [11]. Number of platelets in the whole blood was $239\times 10^9/\text{L}$ and in the PRP was $2422\times 10^9/\text{L}$.

Post operative evaluations

Radiological evaluation: Radiographs of each forelimb was taken postoperatively on 1st day and at the 2nd, 4th, 6th and 8th weeks postoperation to evaluate bone formation, union and remodeling of the defect [9]. The results were scored using a modified Lane and Sandhu scoring system [12].

Histopathological evaluation: Eight weeks after operation the rabbits were euthanized for histopathological and biomechanical evaluation. The histopathological evaluation was randomly carried out on 6 rabbits of each group. The right forelimb of each animal was harvested and dissected free of soft tissues. Sagittal sections containing the defect were cut with a slow speed saw. Each slice was then fixed in 10% neutral buffered formalin. The formalin-fixed bone samples were decalcified in 15% buffered formic acid solution and processed for routine histological examination. Two 5 μm in thickness sections were cut from the centers of each specimen and were stained with hematoxylin and eosin. The sections were blindly evaluated and scored by 2 pathologists according to the Emery's scoring system [13] and based on this scoring system the defects were

evaluated as follows: when the gap was empty (score=0), if the gap was only filled with fibrous connective tissue (score=1), with more fibrous tissue than fibrocartilage (score=2), more fibrocartilage than fibrous tissue (score=3), fibrocartilage only (score=4), more fibrocartilage than bone (score=5), more bone than fibrocartilage (score=6) and filled only with bone (score=7).

Biomechanical evaluation: The biomechanical test was conducted on the injured and normal contralateral bones of half of the rabbits of each group. The test was performed using a universal tensile testing machine (Instron, London, UK) [14-16]. The three-point bending test was performed to determine the mechanical properties of bones. The bones were placed horizontally on two rounded supporting bars located at a distance of 30 mm, and were loaded at the midpoint of the diaphysis by lowering the third bar so that the defect was in the middle and had an equal distance from each grip. The bones were loaded at a rate of 10 mm/min until fracturing occurred. The behavior of each specimen under loading was characterized by determining the following parameters from the load deformation to destruction curve.

1. Tan- α : the coefficient of inclination for the linear portion of the load-deformation curve represents the index of stiffness of the material and is expressed as Newton/mm. It is easily calculated by measuring the slope of a line drawn as a tangent to the curve at any defined point. The slope gives the approximate stiffness of the preparation.
2. Ultimate strength: the highest registered load (N).
3. The specimen's extension at the ultimate strength region. The term "strain" means the fractional increase in the length of the material due to an applied load. It is calculated by dividing the extension by the original length of the specimen. Strain is more useful than extension, because it minimizes the influence of length measurement error and does not depend on the specimen size.

4. Maximum stress: Proportion of the ultimate strength to the cross sectional area of the specimen ($\text{Newton}/\text{mm}^2$).

The data derived from the load deformation and stress-strain curves were expressed as Mean \pm SEM for each group and the ultimate strength, stiffness, maximum stress and strain was measured and recorded.

Statistical analysis: The radiological and histopathological data were compared by Kruskal-Wallis, non-parametric ANOVA. When p -values were found to be less than 0.05, then pair wise group comparisons was performed by Mann-Whitney U test. The biomechanical data were compared by a student's t -test between the treated and normal limb data and also was used for biomechanical analysis between the treated bones of the two groups (SPSS-17 for windows, SPSS Inc, Chicago, USA).

Results

No animal was died during operation or until the end of the experiment and all the animals completed the study without any complications.

Radiographic findings

Bone formation: There was 0-25% bone formation in some rabbits in the control group, however 25-50% bone formation was observed in the defect of the animal of hPRP group on 14th postoperative day. The statistical tests supported significant difference on 14th postoperative day for bone formation ($p=0.001$).

There was significantly more (50-75%) bone formation activity in the defects of the rabbits of hPRP group compared to those of the control group (0-25% bone formation) on 28th postoperative day ($p=0.002$). On 42nd postoperative day there was 75-100% bone formation in all rabbits in hPRP group while 25-75% bone formation was seen in the rabbits of the control group ($p=0.002$). There was 100% bone formation in the animals of the hPRP group and 50-75% bone formation in those of the control group on 56th post operative day (Table 1, Fig. 1 and 2).

Bone union: There was bone union in the rabbits of hPRP group and there was no evidence of union in the rabbits of the control group on 14th postoperative days. In addition, there was significant bone union in the rabbits of hPRP group compared to those of the control ones on 28th postoperative day. There was statistically significant difference for bone union at the 42nd and 56th post operative days in the radiological signs of bone union between the hPRP and control group ($p<0.05$) (Tables 2 and 3, Fig. 1 and 2).

Remodeling: Remodeling was not found in either group on 14th, 28th and 42nd postoperative days. On 56th postoperative day remodeling was observed in the rabbits of the treated group and statistical tests revealed significant difference between the 2 groups, and the operated area of the hPRP group showed a more advanced remodeling compared to those of the control one (Table 4, Fig. 1 and 2).

Histopathological findings: At histopathological level, the defects of the animals of the hPRP group showed more advanced repair criteria [med (min-max), 7 (6-7)] than those of the control group [med (min-max), 2 (1-5)] and statistical tests revealed significant difference between the two groups ($p=0.002$). In all of animals of hPRP group the defects were filled with remodeled bone tissue and histological union developed in any of these animals. Fibrous nonunions or fibrocartilages in the bone defects of the animals of the control group were dominant and the lesions of these animals showed poor re-vascularization. Bridging callus or histological union did not develop in any of these defects. These criteria lead to very slow repair process in the animals of the control group (Fig. 3).

Biomechanical properties: There was significant difference between the injured bone with normal bone of the control group in terms of ultimate strength ($p=0.01$) and stiffness ($p=0.04$) and the normal bones had superior ultimate strength and stiffness compared to their normal contralateral bones. In addition, the ultimate strength ($p=0.03$) and stiffness ($p=0.02$) of the treated limbs showed more advanced values in comparison with those of the control group (Table 5).

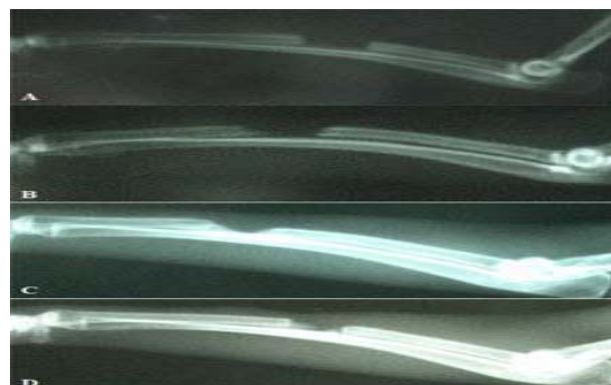


Figure 1. Radiographs of treated forelimb in control group, on 1st day (A), 14th postoperative day (B), 28th postoperative day (C), 42nd postoperative day (D) and 56th postoperative day (E)

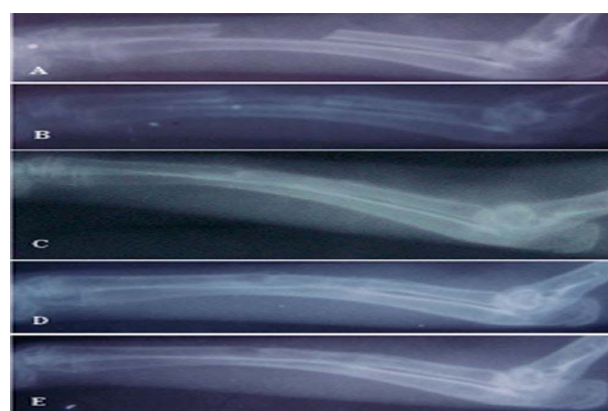


Figure 2. Radiographs of treated forelimb in hPRP group, on 1st day (A), 14th postoperative day (B), 28th postoperative day (C), 42nd postoperative day (D) and 56th postoperative day (E)

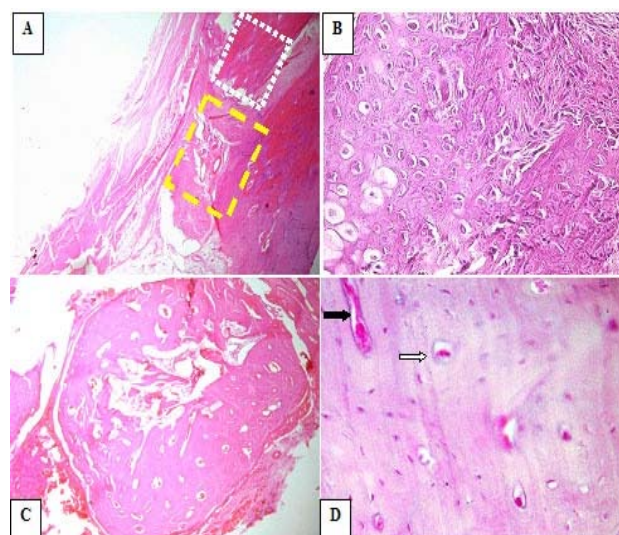


Figure 3. Photomicrograph of control group note to fibrous connective tissues in the defected area without bone marrow formation (yellow rectangle), note to old bone region (white rectangle) (A, H & E stain 4x). Note to extensive fibrocartilage tissue (B, H & E stain 40x). Photomicrograph of hPRP group, compact cortical bone and marrow formation was observed in grafted area (C, H & E stain 4x). Note to compact bone formation with several Haversian canal (white arrow) and Volkmann canal (black arrow) (D, H & E stain 40x)

Table 1. Radiographical findings for bone formation at various post-operative intervals

Postoperative days	Med (min-max)		p-Value ^a
	Control (N=6)	hPRP (N=6)	
14	0 (0-1)	1 (0-2) ^b	0.001
28	1 (0-1)	2 (1-3) ^c	0.002
42	1 (0-3)	3 (1-4) ^d	0.002
56	2 (1-3)	3 (2-4) ^e	0.001

Significant p-Values are presented in bold face.

^aKruskal-Wallis non-parametric ANOVA

^bp= 0.002 (compared with control by Mann-Whitney U test)

^cp= 0.007 (compared with control by Mann-Whitney U test)

^dp= 0.002 (compared with control by Mann-Whitney U test)

^ep= 0.001 (compared with control by Mann-Whitney U test)

Table 2. Radiological findings for proximal union at various post-operative intervals

Postoperative days	Med (min-max)		p-Value ^a
	Control (N=6)	hPRP (N=6)	
14	0 (0-0)	0 (0-2)	0.03
28	1 (0-1)	2 (0-2) ^b	0.008
42	1 (0-1)	2 (1-2) ^c	0.001
56	1 (0-2)	2(1-2) ^d	0.001

Significant p-values are presented in bold face

^aKruskal-Wallis non-parametric ANOVA

^bp= 0.01 (compared with the control group by Mann-Whitney U test)

^cp= 0.001 (compared with the control group by Mann-Whitney U test)

^dp= 0.002 (compared with the control group by Mann-Whitney U test)

Table 5. Biomechanical findings after 56th postoperative day

Three point bending test criteria	Mean±SEM			
	Control (N=6)		hPRP (N=6)	
	Normal limb	Treated limb	Normal limb	Treated limb
Ultimate strength (N)	74.33±10.0 ^a	38.6±7.5	98.6±7.7	99.1±19.1 ^b
Stress (N/mm ²)	3.64±0.7	2.18±0.3	6.08±0.77	6.28±0.69 ^c
Stiffness (N/mm)	128.3±7.4 ^d	91.6±14.9	118.3±14.4	105.0±5.0
Strain (%)	7.9±0.5	8.4±0.6	8.52±0.4	8.1±0.1

^ap= 0.01 (normal limb compared with treated limb in control group by student-t test)

^bp= 0.03 (compared with treated limb in control group by student t-test)

^cp= 0.02 (compared with treated limb in control group by student t-test)

^dp= 0.04 (normal limb compared with treated limb in control group by student t-test)

Discussion

This study was designed to provide an explanation for the existing confusion in the literature regarding the efficacy of the PRP application, and to give more insight into the effect of PRP on bone regeneration. To the authors' knowledge this is one of the first studies, which presents new data on the bone regenerative properties of the human PRP as a xenogenic PRP on bone repair in rabbit model. Such defect in the radius in the rabbit model has previously been reported suitable because there is no need for internal or external fixation which influences the repair process [9]. The segmental defect was created on the middle portion of the radius as long as 10 mm to prevent spontaneous and rapid healing [9].

The clinical and experimental data in the literature regarding the osteogenic potential of PRP are controversial. The results of the present investigation confirm a number of clinical and experimental studies demonstrating a positive influence of PRP on bone regeneration [2, 4]. However, in human maxillofacial

Table 3. Radiographical findings for distal union at various post-operative intervals

Postoperative days	Med (min-max)		p-Value ^a
	Control (N=6)	hPRP (N=6)	
14	0 (0-1)	1 (0-1) ^b	0.004
28	1 (0-1)	2 (0-2) ^c	0.002
42	2 (0-2)	2 (0-2) ^d	0.005
56	2 (0-2)	2 (0-2)	0.04

Significant P-values are presented in bold face

^aKruskal-Wallis non-parametric ANOVA

^bp= 0.01 (compared with the control group by Mann-Whitney U test)

^cp= 0.03 (compared with the control group by Mann-Whitney U test)

^dp= 0.007 (compared with the control group by Mann-Whitney U test)

Table 4. Radiographical findings for remodeling over various post-injury intervals

Postoperative days	Med (min-max)		p-Value ^a
	Control (N=6)	hPRP (N=6)	
14	0 (0-0)	0 (0-0)	1.000
28	0 (0-0)	0 (0-1)	0.3
42	0 (0-0)	0 (0-1)	0.03
56	0 (0-1)	1 (0-2) ^b	0.01

Significant p-values are presented in bold face

^aKruskal-Wallis non-parametric ANOVA

^bp= 0.01 (compared with group II by Mann-Whitney U test)

defects, neither autograft nor allograft or a mineral bone substitute material enhanced bone formation when augmented with PRP [17-19]. In a non-critical rabbit skull defect, PRP was not superior to the empty defect nor did PRP increased bone formation by autogenous bone [20].

The results of the present study indicate that hPRP stimulates a favorable reaction in the injured area of the long bones. The radiographic evaluation at two week post-injury showed that the bone gap in the hPRP group was healed before that of the control group and it was also already in the remodeling stage. While the defects of the control animals were still in the healing stage even at the end of eight weeks post-injury. This fact was corroborated by histopathologic and biomechanical data analysis, which showed that osteogenesis in the animals of hPRP group at 56 days post injury was stronger than those of the control group.

PRP contains several growth factors including isomers of PDGF, TGF-X 1, TGF-X 2, IGF-I, IGF-II and VEGF that all of them are promoters of bone regeneration. PDGF has been shown to be mitogenic for osteoblasts

[21] and stimulates migration of the mesenchymal progenitor cells [22]. It is stated that in the bone defects of the animal models, PDGF induced callus formation [23]. TGF- β also has a stimulative effect on osteogenesis and inhibits bone resorption [24]. In addition, it has been reported that IGF-I and the angiogenic factor VEGF induced bone formation in rats [25] and in rabbits [26], respectively. These growth factors support bone regeneration primarily via chemotactic and mitogenic effects on preosteoblastic and osteoblastic cells. Due to this phenomenon, an enhanced bone formation criteria in the animals of the hPRP group compared to those of the control ones was observed. However, hPRP does not contain BMPs, the most potent osteoinductive proteins, which promote stem cell differentiation into the osteoblastic lineage and are the only growth factors known to induce ectopic bone formation [27]. Schlegel et al. and Thorwarth et al. got better results by administering higher doses of hPRP (6.5-fold compared to normal blood) than with lower platelet concentrations (4.1-fold) on bone regeneration in skull defects of minipigs [28, 29]. Other experimental studies found no correlation between the platelet concentration with improvement in bone repair [20, 30]. In the present study, high platelet concentrations (10.1-fold compared to normal blood) were effective and lead to superior and faster bone formation than those of the control group.

The biomechanical evaluation performed in the present study indicated initial failure at the interosseous membrane, suggesting a strong load sharing mechanism through this syndesmosis between the radius and the ulna. The syndesmosis was shown to have extensive calcification, accounting for a large fraction of the bone volume in the defect and possibly contributed to the bone in-growth into the defected area. This was supported both by histopathologic and radiographic evidences showing new bone growth in a cone-like fashion and from the direction of the interosseous membrane in the defects of hPRP group as well as in the defects with no treatments. Thus, separating the radius from the ulna for biomechanical testing may damage this tissue. It is also important to consider that the radius and ulna act as a unit in the physiological setting and it may be more biologically-relevant to evaluate them together [31].

Based on the radiological, histopathological and biomechanical findings of the present study, healing of the defects of the animals of the control group was not very efficient and the defect area was filled with fibrous tissues and rarely with cartilage instead of osseous tissue. Barnes et al. indicated that the chondrocytes derived from

the mesenchymal progenitors proliferate and synthesize cartilaginous matrix until all the fibrous granulation tissue is replaced by cartilage. Where cartilage production is deficient, fibroblasts replace the region with generalized fibrous tissue. Discrete cartilaginous regions progressively grow and merge to produce a central fibrocartilaginous plug between the fractured fragments that splints the fracture [32].

Preparation of PRP from the animal blood is not a standardized procedure such as PRP preparation from human blood, therefore, it was not possible to purchase the rabbit PRP from the well known markets. Preparing the rabbit PRP from the same animals needed a sizeable volume of blood to be collected from each rabbit and the Ethics Committee laws did not permit to collect such amount of blood from rabbits and believed this will affect their healing potentials. In addition, the critical effective amounts of platelets in PRP for different animal species, levels of growth factors in different animal species and similarities or differences in their mechanisms of action with PRP of humans have still to be defined. Until then, the animal PRP preparations/studies should be interpreted carefully [33]. Production of xenoreactive antibodies against hPRP could not be excluded, which might have affected the results, however, in the current model, no histological signs of acute or chronic inflammatory response in hPRP xenograft was observed, although it may have been present earlier. As it is stated in the text one of the main reasons was that the properties of hPRP contents have been proved in many earlier studies, however, the rabbit's PRP contents is still unknown to our knowledge.

In overall, this study showed that hPRP has a high regenerative capacity in critical size bone defects in rabbit model after 8 weeks and it might be used to accelerate the bony defect healing in orthopedic or maxillofacial reconstructive surgery

Acknowledgements

This research was jointly supported by a grant (No. 89-GR-VT-17) from Shiraz University, research council, Shiraz, Iran.

Authors' Contributions

All authors had equal role in design, work, statistical analysis and manuscript writing.

Conflict of Interest

The authors declare no conflict of interest.

Funding/Support

Shiraz University.

References

1. Phieffer LS, Goulet JA. Delayed unions of the tibia. Instr Course Lect. 2006; 55: 389-401.
2. Pieri F, Lucarelli E, Corinaldesi G, et al. Effect of mesenchymal stem cells and platelet-rich plasma on the healing of standardized bone defects in the alveolar ridge: A comparative histomorphometric study in minipigs. J Oral Maxillofac Surg. 2009; 67(2): 265-272.
3. Weibrich G, Hansen T, Kleis W, et al. Effect of platelet concentration in platelet-rich plasma on peri-implant bone regeneration. Bone. 2004; 34(4): 665-671.
4. Creeper F, Lichanska AM, Marshall RI, et al. The effect of platelet-rich plasma on osteoblast and periodontal ligament cell migration, proliferation and differentiation. J Periodontal Res. 2009; 44(2): 258-265.

5. Plachokova AS, Nikolidakis D, Mulder J, et al. Effect of platelet-rich plasma on bone regeneration in dentistry: A systematic review. *Clin Oral Implants Res.* 2008; 19(6): 539-545.
6. Marx RE. Platelet-rich plasma: Evidence to support its use. *J Oral Maxillofac Surg.* 2004; 62(4): 489-496.
7. Griffin XL, Smith CM, Costa ML. The clinical use of platelet-rich plasma in the promotion of bone healing: A systematic review. *Injury.* 2009; 40(2): 158-162.
8. Butterfield KJ, Bennett J, Gronowicz G and Adams D. Effect of platelet-rich plasma with autogenous bone graft for maxillary sinus augmentation in a rabbit model. *J Oral Maxillofac Surg.* 2005; 63(3): 370-376.
9. Wise DL. Preclinical evaluation of bone graft substitutes. In: Bensen CV, An YH, Friedman RJ, editors. *Biomaterials and bioengineering handbook.* New York: CRC Press; 2000: 699-716.
10. Oryan A, Meimandi-Parizi A, Shafiei-Sarvestani Z and Bigham AS. Effects of combined hydroxyapatite and human platelet rich plasma on bone healing in rabbit model: Radiological, macroscopical, histopathological and biomechanical evaluation. *Cell Tissue Bank.* 2012; 13(4): 639-651.
11. Amable PR, Carias RB, Teixeira MV, et al. Platelet-rich plasma preparation for regenerative medicine: Optimization and quantification of cytokines and growth factors. *Stem Cell Res Ther.* 2013; 4(3): 67.
12. Lane JM, Sandhu HS. Current approach to experimental bone grafting. *Orthop Clin North Am.* 1987; 18(2): 213-225.
13. Emery SE, Brazinski MS, Koka A, et al. The biological and biomechanical effects of irradiation on anterior spinal bone grafts in a canine model. *J Bone Joint Surg Am.* 1994; 76(4): 540-8.
14. Oryan A, Goodship AE, Silver IA. Response of a collagenase-induced tendon injury to treatment with a polysulphated glycosaminoglycan (adequan). *Connect Tissue Res.* 2008; 49(5): 351-360.
15. Oryan A, Moshiri A, Meimandi-Parizi AH. Effects of sodium-hyaluronate and glucosamine-chondroitin sulfate on remodeling stage of tenotomized superficial digital flexor tendon in rabbits: A clinical, histopathological, ultrastructural and biomechanical study. *Connect Tissue Res.* 2011; 52(4): 329-39.
16. Oryan A, Shoushtari AH. Biomechanical properties and dry weight content of the developing superficial digital flexor tendon. *Comp Clin Pathol.* 2009; 18(2): 131-137.
17. Froum SJ, Wallace SS, Tarnow DP and Cho SC. Effect of platelet-rich plasma on bone growth and osseointegration in human maxillary sinus grafts: Three bilateral case reports. *Int J Periodontics Restorative Dent.* 2002; 22(1): 45-53.
18. Shanaman R, Filstein MR, Danesh-Meyer MJ. Localized ridge augmentation using GBR and platelet-rich plasma: Case reports. *Int J Periodontics Restorative Dent.* 2001; 21(4): 345-355.
19. Raghoobar GM, Schortinghuis J, Liem RS, et al. Does platelet-rich plasma promote remodeling of autologous bone grafts used for augmentation of the maxillary sinus floor? *Clin Oral Implants Res.* 2005; 16(3): 349-356.
20. Aghaloo TL, Moy PK, Freymiller EG. Investigation of platelet-rich plasma in rabbit cranial defects: A pilot study. *J Oral Maxillofac Surg.* 2002; 60(10): 1176-1181.
21. Pal US, Mohammad S, Singh RK, et al. Platelet-rich growth factor in oral and maxillofacial surgery. *Natl J Maxillofac Surg.* 2012; 3(2): 118-23.
22. Fiedler J, Röderer G, Günther KP and Brenner RE. BMP-2, BMP-4, and PDGF-bb stimulate chemotactic migration of primary human mesenchymal progenitor cells. *J Cell Biochem.* 2002; 87(3): 305-312.
23. Nash TJ, Howlett CR, Martin C, et al. Effect of platelet-derived growth factor on tibial osteotomies in rabbits. *Bone.* 1994; 15(2): 203-208.
24. Kasagi S, Chen W. TGF-beta1 on osteoimmunology and the bone component cells. *Cell Biosci.* 2013; 3: 4.
25. Spencer EM, Liu CC, Si EC and Howard GA. In vivo actions of insulin-like growth factor-I (IGF-I) on bone formation and resorption in rats. *Bone.* 1991; 12(1): 21-6.
26. Street J, Bao M, deGuzman L, et al. Vascular endothelial growth factor stimulates bone repair by promoting angiogenesis and bone turnover. *Proc Natl Acad Sci USA.* 2002; 99(15): 9656-9661.
27. Cook SD. Preclinical and clinical evaluation of osteogenic protein-1 (BMP-7) in bony sites. *Orthopedics.* 1999; 22(7): 669-671.
28. Schlegel KA, Donath K, Rupprecht S, et al. De novo bone formation using bovine collagen and platelet-rich plasma. *Biomaterials.* 2004; 25(23): 5387-5393.
29. Thorwarth M, Rupprecht S, Falk S, et al. Expression of bone matrix proteins during de novo bone formation using a bovine collagen and platelet-rich plasma (prp)-An immunohistochemical analysis. *Biomaterials.* 2005; 26(15): 2575-2584.
30. Kim SG, Kim WK, Park JC and Kim HJ. A comparative study of osseointegration of Avana implants in a demineralized freeze-dried bone alone or with platelet-rich plasma. *J Oral Maxillofac Surg.* 2002; 60(9): 1018-1025.
31. Guda T, Walker JA, Pollot BE, et al. In vivo performance of bilayer hydroxyapatite scaffolds for bone tissue regeneration in the rabbit radius. *J Mater Sci Mater Med.* 2011; 22(3): 647-656.
32. Barnes GL, Kostenuik PJ, Gerstenfeld LC and Einhorn TA. Growth factor regulation of fracture repair. *J Bone Miner Res.* 1999; 14(11): 1805-1815.
33. Plachokova AS, van den Dolder J, van den Beucken JJ and Jansen JA. Bone regenerative properties of rat, goat and human platelet-rich plasma. *Int J Oral Maxillofac Surg.* 2009; 38(8): 861-869.

Please cite this article as: Shafiei-Sarvestani Z, Oryan A, Meimandi-Parizi A, Bigham-Sadegh A. Histological, biomechanical and radiological evaluation of bone healing with human platelet rich plasma in rabbit model. *Zahedan J Res Med Sci.* 2015; 17(2): 1-6.