

Inserting central venous catheter in emergency conditions in coagulopathic patients in comparison to noncoagulopathic patients

Mohammad Nasr-Esfahani, Mohsen Kolahdouzan¹, Seyed Abbas Mousavi

Departments of Emergency Medicine and ¹Surgery, AL-Zahra Medical Center, Isfahan University of Medical Sciences, Isfahan, Iran

Background: The current study was designed to compare the complications and adverse effects of central venous catheter (CVC) insertion under ultrasound guidance in patients with and without coagulopathy. **Materials and Methods:** In this clinical trial, 59 patients who needed CVC for various reasons were enrolled. Patients were divided into two groups of those with and without coagulopathy based on complete blood count, prothrombin time, partial thromboplastin time, and international normalized ratio test results, and then, CVC was inserted with ultrasound guidance in both groups. The CVC inserting site was examined for hematoma and hemorrhage in four stages at different times. **Results:** There was no significant difference in the terms of demographic features, catheter lumen size ($P = 0.43$), and number of attempting for CVC placement (odds ratio [OR] = 2.35, 95% confidence interval [CI] = 0.36–15.3, $P = 0.39$) between two groups. Seven out of 59 patients suffered from complications (11.9%) that the complications in coagulopathic patients were oozing (5.7%) and superficial hematoma (8.6%) while in noncoagulopathic patients were 4.2% for both complications (OR = 0.54, 95% CI = 0.09–3.07, $P = 0.767$). **Conclusion:** According to our results, it can be concluded that inserting CVC with ultrasound guidance under emergency conditions causes no serious and life-threatening complications in coagulopathic patients.

Key words: Central venous catheter, coagulopathy, emergency, shock, ultrasound

How to cite this article: Nasr-Esfahani M, Kolahdouzan M, Mousavi SA. Inserting central venous catheter in emergency conditions in coagulopathic patients in comparison to noncoagulopathic patients. *J Res Med Sci* 2016;21:117.

INTRODUCTION

Inserting central venous catheter (CVC) is one of the medically necessary procedures for some admitted patients in hospitals.^[1] The CVC is inserted for various reasons, such as in patients without visible vessels or in shock, for drug, blood products and total parented nutrition (TPN) administration, hemodynamic monitoring, management of fluid therapy before operation, injection of chemotherapy drugs, and hemodialysis.^[2,3]

The old technique used for inserting the catheter is to use anatomical points to venipuncture which had low success rate and high chance of complications.^[3]

These complications ranged from small hematoma to large and serious hemorrhage with a prevalence of more than 15% as shown in previous studies, whereas the life-threatening complications are less common.^[3] Complications after the insertion of the CVC include hemorrhage from the entry point, subcutaneous hematoma, mediastinal hematoma, and hemothorax.^[1,2]

Use of ultrasound at the start of the procedure of inserting CVC in the internal jugular or femoral vein reduces the chances of failure.^[3] Use of ultrasound for inserting CVC started in 1978 and is currently considered as the best and safest method for this purpose.^[4] Use of ultrasound guidance while inserting CVC helps reduce complications and increase the success rate of the operation.^[5] However, there are reports of complications such as damage to the vein during sonography.^[6]

This is an open access article distributed under the terms of the Creative Commons Attribution-NonCommercial-ShareAlike 3.0 License, which allows others to remix, tweak, and build upon the work non-commercially, as long as the author is credited and the new creations are licensed under the identical terms.

For reprints contact: reprints@medknow.com

Access this article online

| | |
|----------------------|--|
| Quick Response Code: | Website: www.jmsjournal.net |
| | DOI: **** |

Address for correspondence: Dr. Seyed Abbas Mousavi, Department of Emergency Medicine, Al Zahra Medical Center, Isfahan University of Medical Sciences, Sofeh Street, Isfahan, Iran. E-mail: erfantomousavi138@yahoo.com

Received: 16-06-2016; **Revised:** 16-07-2016; **Accepted:** 24-08-2016

Currently, there is no comprehensive guideline for inserting of CVC in coagulopathic patients and it is not known for certain whether fresh frozen plasma (FFP) or concentrated platelets should be administered in these patients or not. Correcting coagulopathy can be helpful but is not always possible because correction and injection of blood factors require access to veins.^[7] Moreover, blood transfusion can lead to bloodborne infections such hepatitis or human immunodeficiency virus.^[8]

To implant CVC in coagulopathic patients, there are no absolute contraindications and some studies even suggest that there is no increase in hemorrhage risk in patients being treated with heparin.^[9] For coagulopathic patients, many researchers choose sites where compresses can be applied such as internal jugular or femoral veins.^[7,10,11]

However, many studies consider platelets $\leq 50 \times 10^9/L$ a contraindication to CVC placement, which may increase the risk of bleeding.^[7,12,13] Therefore, these authors suggested that platelet transfusion or correction of international normalized ratio (INR) in coagulopathic patients should be performed before venous puncture.

Because number of CVC insertions in medical centers is increasing^[4] and due to lack of sufficient studies on the complications caused by CVC insertion under ultrasound guidance, especially in coagulopathic patients, we designed this study. The aim of this study was to show that we can perform CVC in coagulopathic patients without correction of INR. In some patients, emergent CVC placement is necessary and we cannot wait to correct coagulation parameters. Therefore, if the complications of venous puncture in coagulopathic patients without correction of coagulation parameters were similar to noncoagulopathic patients, we can place CVC in all emergent patients without fearing life-threatening complications. The current study was designed to compare the complications and adverse effects of CVC insertion under ultrasound guidance in patients with and without coagulopathy.

MATERIALS AND METHODS

This clinical trial study was performed at Al-Zahra Sub-specialty University Hospital in Isfahan throughout years 2013–2014.

Fifty-nine patients who needed CVC for various reasons including patients without visible vessels or in shock, for drug, blood products and TPN administration, hemodynamic monitoring, management of fluid therapy before operation, injection of chemotherapy drugs, and hemodialysis were included in this study [Figure 1].

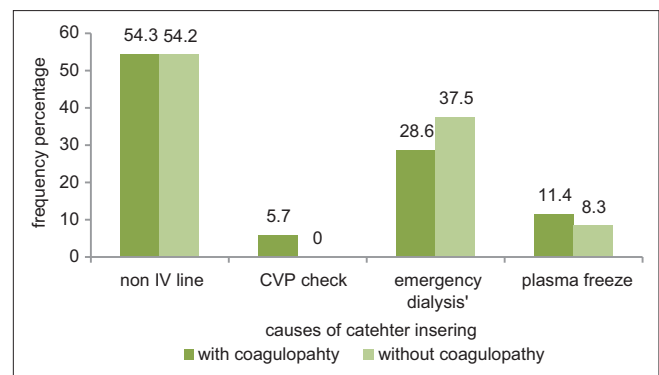


Figure 1: Reasons for inserting central venous catheter. Presents the distribution of causes of central venous catheter insertion in patients divided into two studied groups. There was no significant difference between two groups ($P = 0.6$)

Inclusion criteria consisted of a patient referred to the Emergency Department of Al-Zahra Medical Center who required CVC via femoral approach based on clinical conditions (monitoring CVP in fluid therapy or infusion of vasoactive drugs, administration of blood products). Exclusion criteria consisted of patients with infection on insertion region of target vein, thrombosis of the target vein, preexisting femoral catheter, pregnant patients, uncooperative patients, unable to determine the complications of CVC insertion due to death, platelet count $< 50,000$, and patients younger than 18 years were excluded from the study.

The study protocol was approved by the Ethics Committee (393723) of Isfahan University of Medical Sciences, and written informed consent was obtained from participants.

Procedures and variables assessments

The study flowchart is shown in Figure 2. Fifty-nine patients with indication for CVC who had been diagnosed by emergency medicine specialist and based on inclusion and exclusion criteria were included in the study. No patient was dropped out, and finally, all patients completed the study (35 patients in case group and 24 patients in control group). The method of study required that after physical examination and examining the history of patients, patients meeting the inclusion criteria were selected using simple random sampling. Then, patients were divided into two groups of those with and without coagulopathy based on complete blood count, prothrombin time (PT), partial thromboplastin time (PTT), and INR test results, and CVC inserting with ultrasound guidance was carried out in both groups. For this purpose, all the CVC placements were performed by specific trained 3rd-year emergency medicine resident under the supervision of specific attending physician in the same room with the same ultrasound device. The catheter used in these patients was single lumen

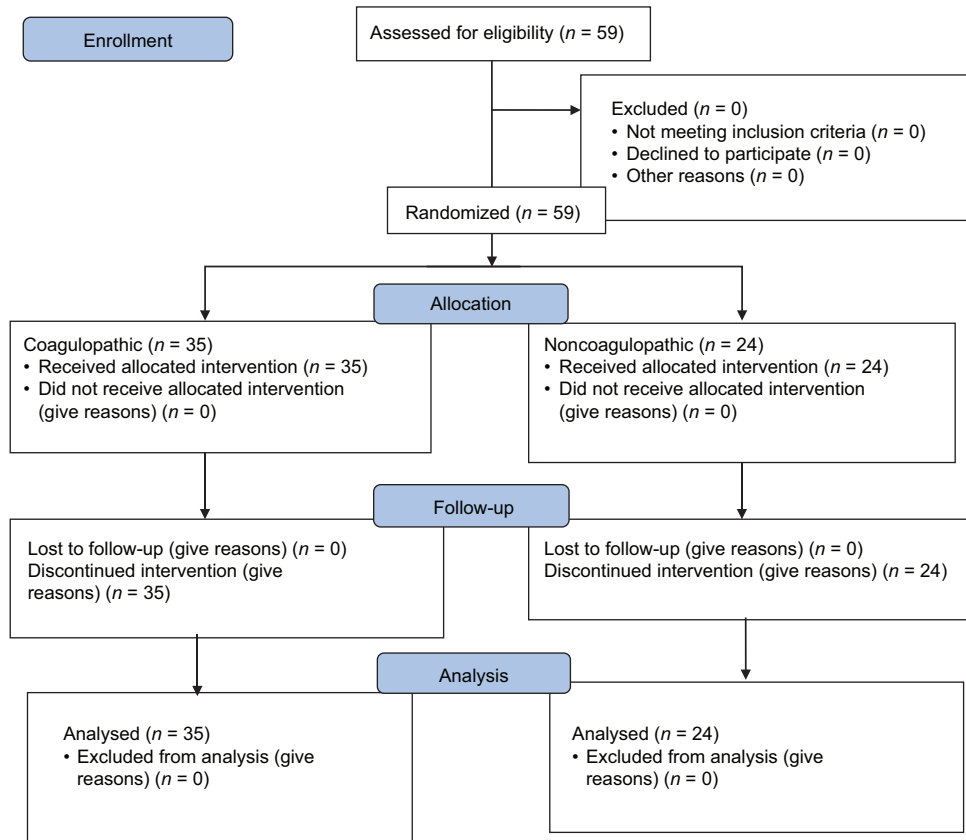


Figure 2: Study flowchart (CONSORT format)

or three lumens with the size of 16–20 Fr based on the needs of the patient. CVC was inserted with guidance of a 7.5 MHz ultrasound probe of MindRay device. For initial puncturing, a single lumen 18-gauge needle and real-time M-mode ultrasound were used. Furthermore, to have the best view for CVC placement and decrease the complications, we used the best view of ultrasound without any limitation. After initial puncturing, a guiding wire and a vasodilator were used which were mounted on the guiding wire as a temporally catheter. The normal limits for PT, PTT, and INR were 13–15 s, 37 s, and 1.5 s, respectively.^[1]

The CVC inserting site was examined for catheter hematoma, oozing and serious hemorrhage in four stages: In the first stage – every 5 min for the 1st h, in the second stage – every 15 min for the 2nd h, in the third stage – every 30 min for 1 h, and finally – every hour for 4 h for the fourth stage.

Statistical analysis

Quantitative and qualitative data were expressed as mean ± standard deviation and frequency and percentage, respectively. Normality of quantitative data was evaluated using Kolmogorov–Smirnov test and QQ plot. Between groups analysis was done using independent *t*-test for quantitative data and Chi-square test for qualitative data. All statistical analyses were performed using

statistical package for social sciences (SPSS 15, SPSS Inc., Chicago, USA).

RESULTS

In this study, 59 patients underwent inserting CVC in the central femoral. Based on PT, PTT, and INR test results, 24 patients were without coagulopathy and 35 patients had coagulopathy. The mean age of the patients were 55.17 ± 9.6 and 58.19 ± 2.4 years for coagulopathic and noncoagulopathic patients, respectively (*P* = 0.6) No significant difference was found in terms of gender distribution between studied groups (*P* = 0.82). Moreover, the mean levels of PT, PTT, and INR between two groups of patients were statistically significant (*P* < 0.001). Furthermore, there was no significant difference in catheter lumen size (*P* = 0.43) and number of attempting for CVC placement (odds ratio [OR] =2.35, 95% confidence interval [CI] =0.36–15.3, *P* = 0.39) for CVC procedure between two groups. Seven out of 59 patients suffered from complications (11.9%) that the complications in coagulopathic patients were oozing (5.7%) and superficial hematoma (8.6%) while in noncoagulopathic patients were 4.2% for both complications (OR = 0.54, 95% CI = 0.09–3.07, *P* = 0.767), which were limited to the catheter entry point and did not expand after further examinations.

Furthermore, we did not observe severe hemorrhage [Table 1].

DISCUSSION

Our study showed that outcomes such as number of attempting for CVC placement and complications did not differ between patients with and without coagulopathy; moreover, we did not observe severe hemorrhage or life-threatening complications. On the other hand, catheter lumen size and demographic features in both groups were similar; therefore, the parameters affect that the complications were similar in both groups and the only parameter was different between the groups was coagulopathic indexes.

Theodoro *et al.* showed that coagulopathy disorders have no correlations with the complications in CVC placement. They found that an adverse outcome occurred in 57 attempts (19.7%), the most common being 31 unsuccessful placements (11%).^[14] However, we found that adverse

outcome occurred in 20.3% attempts, with 8.4% unsuccessful placements, which may due to different methods of CVC placement. In our study, all the CVC placements were performed with femoral approaches with the best view of ultrasound without any limitation while Theodoro *et al.* used internal jugular approaches with specific view of ultrasound. Furthermore, Della Vigna *et al.* showed that in patients with cancer who had coagulation disorders, nontunneled CVC placement with US guidance was feasible and safe and did not require correction of coagulation parameters.^[15] However, their results were similar with our results, but they used subclavian and internal jugular approaches for CVC placement, which may have significant coagulopathy related complications such as hemothorax. Therefore, we can conclude that correction of coagulation parameters is not necessary for all CVC placement approaches. Moreover, Singh *et al.* suggested that ultrasound guidance CVC in liver disease patients with deranged coagulation is a safe and highly successful modality. They found that no major vascular or nonvascular complications were recorded in all patients. Overall incidence of minor vascular complications was 18.6%, of which 13% had significant ooze, 10.3% had hematoma formation, and 4.7% had both hematoma and ooze.^[16] However, our minor vascular complications were lower (11.84%), which may due to different methods and the professionalism of our emergency medicine resident.

On the other hand, Mumtaz *et al.* showed that the risk of hemorrhage complications during CVC inserting procedure in patients with impaired homeostasis was reported to be 3% while the results of our study showed no hemorrhage complications in CVC entry point. In this study, all complications were confined to hemorrhages that could be controlled by compressing the location.^[17] In the review article done by Frykholm *et al.* in 2014 for clinical guidelines, CVC demonstrated that coagulation disorders should not be reversed routinely, for example, by administration of FFP, tranexamic acid, desmopressin, Vitamin K, or platelets, but pharmacological treatment may be considered in selected patients.^[18]

Our study has confirmed this fact that CVC insertion with ultrasound guidance in coagulopathic patient is safe. The current policy in many medical centers is to correct coagulation parameters before invasive procedure such as deep vein cannulation.^[7] Therefore, based on our and other studies, we can conclude that we can perform CVC placement in all patients without attention to the coagulopathic parameters.

Limitations

There are several limitations of our study that may explain why some of our results differed from those in previous

Table 1: Demographic and clinical variables in coagulopathic and noncoagulopathic patients

| Variable | Group | | OR (95% CI) | P |
|--|--------------|-----------|------------------|--------|
| | Coagulopathy | | | |
| | Yes | No | | |
| Age (year) | 55.9±17.6 | 58.2±19.4 | - | 0.65 |
| Gender (%) | | | | |
| Male | 15 (42.9) | 11 (45.8) | - | 0.82 |
| Female | 20 (57.1) | 13 (54.2) | | |
| PT (s) | 29±20.7 | 12.7±2 | - | <0.001 |
| PTT (s) | 66.1±25.8 | 31.8±5.3 | - | <0.001 |
| INR | 5.03±2.37 | 1.27±0.12 | - | <0.001 |
| INR levels (%) | | | | |
| <1.5 | 0 | 24 (100) | - | <0.001 |
| 1.5-5 | 22 (62.9) | 0 | | |
| 5.1-9 | 10 (28.6) | 0 | | |
| >9 | 3 (8.6) | 0 | | |
| Catheter lumen size (mm), (%) | | | | |
| 20×7 | 0 | 2 (8.3) | - | 0.43 |
| 20×12 | 1 (2.9) | 1 (4.2) | | |
| 20×14 | 8 (22.9) | 4 (16.7) | | |
| 20×16 | 11 (31.4) | 6 (25) | | |
| 16×14 | 15 (42.9) | 10 (41.7) | | |
| Number of attempting for CVC placement (%) | | | | |
| Once | 33 (94.3) | 21 (87.5) | 2.35 (0.36-15.3) | 0.39 |
| Twice | 2 (5.7) | 3 (12.5) | | |
| Complications (%) | | | | |
| Oozing | 2 (5.7) | 1 (4.2) | 0.54 (0.09-3.07) | 0.767 |
| Superficial hematoma | 3 (8.6) | 1 (4.2) | | |

PT = Prothrombin time; PTT = Partial thromboplastin time; INR=International normalized ratio; CI = Conference interval; CVC = Central venous catheter; OR = Odds ratio

studies. At first, we did not do interim analysis; because of the heavy risk serious complications of the study; we recommend having interim analysis in the middle part of the study in another prospective study on this field. Furthermore, our results were not generalizable to pregnant, toxic or overdose patients. On the other hand, the results of this study may not be applicable to intensive care units or other hospital wards where intensivists and surgeons insert the majority of central catheters. Moreover, due to the high risk of serious complications in our study, we performed all CVC placements with specific trained 3rd-year emergency medicine resident under the supervision of specific attending physician; therefore, the rate of our study complications was low.

CONCLUSIONS

Our results showed that that inserting CVC with ultrasound guidance under emergency conditions causes no serious and life-threatening complications in coagulopathic patients. Nevertheless there is some controversy for correction of coagulopathy before CVC insertion.

Acknowledgments

This study was financially supported by Isfahan University of Medical Sciences, Isfahan. We gratefully acknowledge the dedicated efforts of the investigators, the coordinators, the volunteer patients who participated in this study, and Emergency Medicine Research Center, AL-Zahra Research Institute, Isfahan University of Medical Sciences.

Financial support and sponsorship

Nil.

Conflicts of interest

The authors have no conflicts of interest.

AUTHORS' CONTRIBUTION

All authors contributed in the conception of the work, designing the study, definition of intellectual content, literature review, conducting the study, data gathering; analysis and interpretation, manuscript preparation; review and editing, and approval of the final version of the manuscript.

REFERENCES

1. Eisen LA, Narasimhan M, Berger JS, Mayo PH, Rosen MJ, Schneider RF. Mechanical complications of central venous

2. Mumtaz H, Williams V, Hauer-Jensen M, Rowe M, Henry-Tillman RS, Heaton K, *et al.* Central venous catheter placement in patients with disorders of hemostasis. *Am J Surg* 2000;180:503-5.
3. Tercan F, Ozkan U, Oguzkurt L. US-guided placement of central vein catheters in patients with disorders of hemostasis. *Eur J Radiol* 2008;65:253-6.
4. Ullman JI, Stoelting RK. Internal jugular vein location with the ultrasound Doppler blood flow detector. *Anesth Analg* 1978;57:118.
5. Wilson JG, Berona KM, Stein JC, Wang R. Oblique-axis vs. short-axis view in ultrasound-guided central venous catheterization. *J Emerg Med* 2014;47:45-50.
6. Blaivas M. Video analysis of accidental arterial cannulation with dynamic ultrasound guidance for central venous access. *J Ultrasound Med* 2009;28:1239-44.
7. Fisher NC, Mutimer DJ. Central venous cannulation in patients with liver disease and coagulopathy – A prospective audit. *Intensive Care Med* 1999;25:481-5.
8. Doerfler ME, Kaufman B, Goldenberg AS. Central venous catheter placement in patients with disorders of hemostasis. *Chest* 1996;110:185-8.
9. Kusminsky RE. Complications of central venous catheterization. *J Am Coll Surg* 2007;204:681-96.
10. Goldfarb G, Lebrec D. Percutaneous cannulation of the internal jugular vein in patients with coagulopathies: An experience based on 1,000 attempts. *Anesthesiology* 1982;56:321-3.
11. Lee HS, Quinn T, Boyle RM. Safety of thrombolytic treatment in patients with central venous cannulation. *Br Heart J* 1995;73:359-62.
12. Mey U, Glasmacher A, Hahn C, Gorschlüter M, Ziske C, Mergelsberg M, *et al.* Evaluation of an ultrasound-guided technique for central venous access via the internal jugular vein in 493 patients. *Support Care Cancer* 2003;11:148-55.
13. Doerfler ME, Kaufman B, Goldenberg AS. Central venous catheter placement in patients with disorders of hemostasis. *Chest* 1996;110:185-8.
14. Theodoro D, Krauss M, Kollef M, Evanoff B. Risk factors for acute adverse events during ultrasound-guided central venous cannulation in the emergency department. *Acad Emerg Med* 2010;17:1055-61.
15. Della Vigna P, Monfardini L, Bonomo G, Curigliano G, Agazzi A, Bellomi M, *et al.* Coagulation Disorders in Patients with Cancer: Nontunneled Central Venous Catheter Placement with US Guidance—A Single-Institution Retrospective Analysis 1. *Radiology* 2009;253(1):249-52.
16. Singh SA, Sharma S, Singh A, Singh AK, Sharma U, Bhadoria AS. The safety of ultrasound guided central venous cannulation in patients with liver disease. *Saudi J Anaesth* 2015;9:155-60.
17. Roberts JR, Hedges JR. Roberts and Hedges' clinical procedures in emergency medicine. 6th ed., Ch. 22. Elsevier Health Sciences; 2013. p. 427-8.
18. Frykholm P, Pikwer A, Hammarskjöld F, Larsson AT, Lindgren S, Lindwall R, *et al.* Clinical guidelines on central venous catheterisation. Swedish Society of Anaesthesiology and Intensive Care Medicine. *Acta Anaesthesiol Scand* 2014;58:508-24.