

Pulmonary haemorrhage following Russell's viper (*Daboia russelii*) envenoming in Sri Lanka

RATHNAYAKA MUDIYANSELAGE MITHUN KAUSHIKA NAMAL RATHNAYAKA^{1,2,3*}, PANWILAHENA ELLAWATTE ANUSHA NISHANTHI RANATHUNGA⁴, SENANAYAKE ABEYSINGHE MUDIYANSELAGE KULARATNE⁵

¹Intensive care unit, Teaching Hospital, Ratnapura, Sri Lanka

²Postgraduate Institute of Medicine (Clinical Pharmacology and Therapeutics), University of Colombo, Sri Lanka

³Department of Veterinary Pathobiology, Faculty of Veterinary Medicine & Animal Science, University of Peradeniya, Sri Lanka

⁴Medical Unit, Teaching Hospital, Ratnapura, Sri Lanka

⁵Department of Medicine, Faculty of Medicine, University of Peradeniya, Sri Lanka

Abstract

Background: Out of four species of snakes in the family Viperidae in Sri Lanka, Russell's viper is widely distributed all over the country and causes severe envenoming manifestations such as coagulopathy and neuroparalysis. Most snakebite deaths occur due to its bites in Sri Lanka and systemic bleeding is the most trivial complication associated with coagulopathy caused by these snakes. Pulmonary hemorrhage is one effect which is rarely reported.

Case presentation: A 30-year-old previously well male was bitten by a Russell's viper on his left foot and had mild local pain, moderate swelling and two fang punctures. Two hours after the bite, he developed vomiting with bilateral ptosis and external ophthalmoplegia, so he was given 20 vials of polyvalent antivenom after the prophylactic therapy. Later, he had prolonged whole blood clotting test associated with hematuria, followed by respiratory failure for which he was intubated. He also had blood stained endotracheal tube secretions and pulmonary hemorrhage, revealed by high-resolution computed tomography of the chest. He also developed acute kidney injury, rhabdomyolysis and deep vein thrombosis. He completely recovered and was discharged on day 23.

Discussion: Snake venom serine proteinase, metalloprotease, snake venom metalloprotease and L-amino acid oxidase are hemotoxins of Russell's viper venom that cause venom induced consumption coagulopathy and hemorrhage. Metalloprotease has a direct action on lung microvasculature causing pulmonary hemorrhage.

Conclusion: Severe fatal systemic manifestations like pulmonary hemorrhage may occur rarely following Russell's viper bites.

Keywords: snakebites; antivenom; blood coagulation disorder; Russell's viper; hemorrhage

How to cite this article: Rathnayaka RN, Ranathunga PEAN, Kularatne, SAM. Pulmonary haemorrhage following Russell's viper (*Daboia russelii*) envenoming in Sri Lanka. *Asia Pac J Med Toxicol* 2020; 9(2):72-76.

INTRODUCTION

Sri Lanka is home to four species of snakes in the family Viperidae. They can be divided into 2 groups: true vipers and pit vipers. True vipers include Russell's viper (*Daboia russelii*) and the saw scaled viper (*Echis carinatus*), and pit vipers include the hump-nosed viper (*Hypnale spp.*) and Sri Lankan Green pit viper (*Trimeresurus trigonocephalus*). Of these 4 species, Russell's vipers and hump-nosed vipers are deadly venomous and are included in the WHO Category 1 classification of snakes, meaning antivenom is required [1]. In Sri Lanka, Russell's viper is responsible for 30-40% of all venomous snakebites [2] and the majority of deaths are caused due to its bite [3]. Its envenoming causes systemic manifestations such as venom-induced consumption coagulopathy (VICC), neuroparalysis and acute kidney injury (AKI) [4],[5]. There are three broadly classified

pulmonary manifestations in snakebites: generalized neuromuscular paralysis affecting airway and respiratory muscles, pulmonary edema, and pulmonary hemorrhage or thrombosis due to VICC [6]. Respiratory paralysis and pulmonary edema are due to either elapid [7] or, rarely, viper bites, [4] whereas VICC complicating pulmonary hemorrhage are widely caused by viper envenoming. We report a patient who presented with neuroparalysis, AKI and severe form of VICC, which manifested as pulmonary hemorrhage and hematuria, following a Russell's viper bite. The patient completely recovered after 23 days of treatment including intensive care management.

CASE PRESENTATION

A 30-year-old previously well, married male was transferred from a local hospital to a tertiary care centre for further management of a snakebite. He was bitten by a snake around

*Correspondence to: R.M.M.K.Namal Rathnayaka; MBBS, MPhil,MA,MSc (Toxicology), MSc (Clinical Pharmacology & Therapeutics), Intensive care unit, Teaching Hospital Ratnapura, Sri Lanka
E-mail: namalrath10@yahoo.com, Tel: 09714337784

1930 h on his left foot while walking on a footpath and the snake was identified as Russell's viper. On admission, he had mild local pain, moderate swelling and two fang punctures on the dorsum of foot, 17 mm apart (Figure 1). Twenty minutes whole blood clotting test (WBCT20) was negative (<20 min) on admission.

As he developed vomiting with bilateral ptosis and external ophthalmoplegia 2 hours after the bite, he was administered 20 vials of polyvalent antivenom after giving intravenous hydrocortisone 400 mg, chlorpheniramine 10 mg and subcutaneous adrenaline 0.25 mg as bolus doses. Halfway through the antivenom infusion, he developed shortness of breath, rhonchi in the lungs, low blood pressure (BP 84/62 mmHg) and bradycardia (heart rate 42 beats/min). Immediately, antivenom infusion was stopped and adrenaline 0.5 mg was administered intramuscularly. After vital parameters became normal, the infusion was restarted. His WBCT20 was positive 3 hrs after the bite, and was associated with hematuria. He developed respiratory failure around 6 hrs post bite with low oxygen saturation, shortness of breath, restlessness and bleeding from gums. He was immediately intubated, another 10 vials of antivenom were started and was transferred to the intensive care unit for mechanical ventilation. There was laryngeal edema associated with bleeding seen during intubation.

He was kept on synchronized intermittent mandatory ventilation (SIMV) mode with sedation and paralysis for 48 hrs. On day 2, another 10 vials of antivenom were administered due to persistent incoagulable blood associated with blood stained endotracheal tube secretions. On day 2, patient developed ischemic changes on his ECG (T wave inversions on V₁-V₅) and the 2D-echocardiogram showed 45% ejection fraction with global hypokinesia. He also had oliguria associated with elevated blood urea and creatinine levels (Figure 2) for which furosemide 5 mg/hour IV infusion was started. WBCT20 was negative from day 3 onwards. Patient was extubated on day 5 after getting T piece ventilation. He then developed hemoptysis. High-resolution computed tomography (HRCT) of chest was performed and confirmed pulmonary hemorrhage (Figure 3). On day 9, patient had severe pain in his right leg. A venous duplex study was done

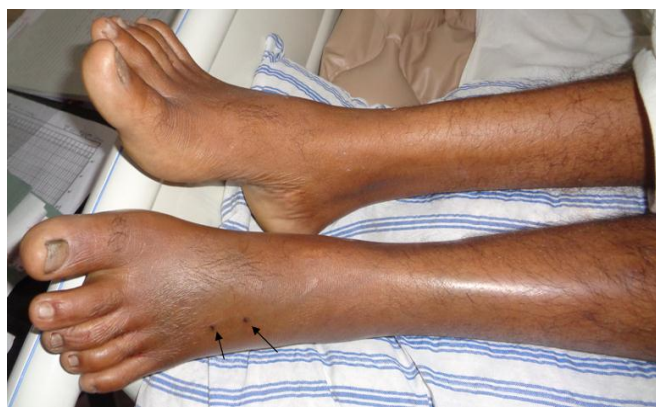

Figure 1. Site of bite (left foot) on day 2 of snakebite (indicated by arrows)

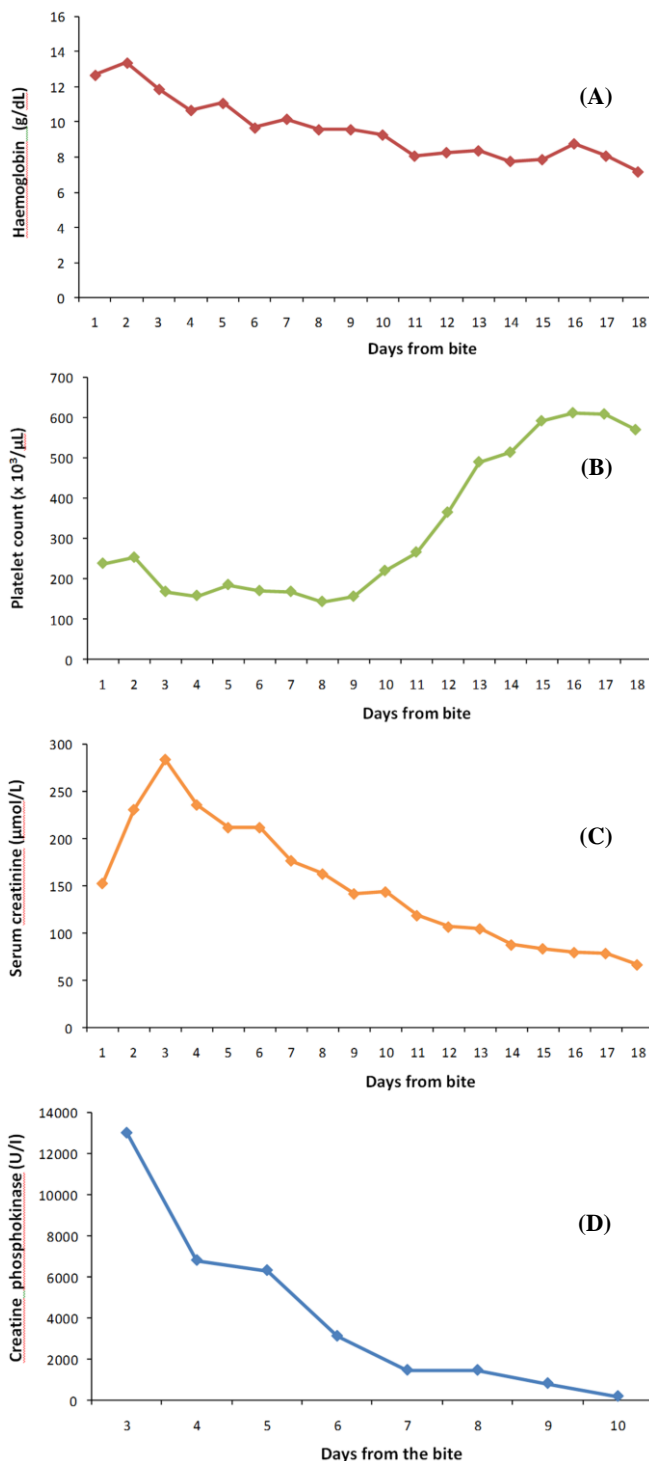


Figure 2. Daily changes of hemoglobin, platelet counts, creatinine and creatine phosphokinase levels

and showed deep vein thrombosis (DVT) of right leg extending from external iliac vein to popliteal vein, and soft tissue edema in bilateral lower limbs (Figure 4). Low molecular weight heparin infusion (18 IU/Kg/hour) was started for DVT and continued for 3 days and then warfarin 5 mg daily. In addition, clindamycin 600 mg IV 4 times a day and piperacillin tazobactam 4.5 g three times a day were

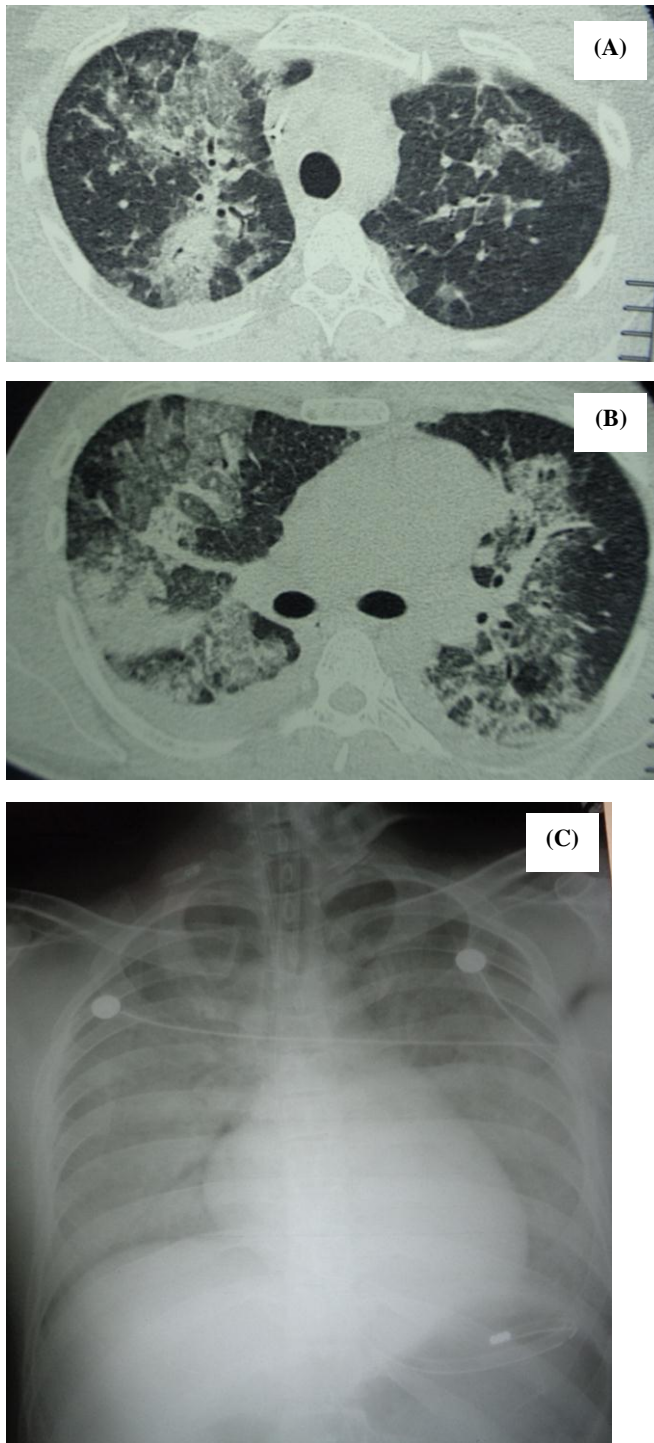


Figure 3. High-resolution computed tomography of chest (A, B) and chest x-ray (C) showing pulmonary hemorrhage on day 5 of snakebite

administered. Laboratory findings throughout hospital stay are shown in Table 1. On day 17, when the DVT was resolved, the patient was transferred to the medical ward. On day 23, he was discharged and followed up in a medical clinic for the DVT.

DISCUSSION

The life-threatening complications due to VICC caused

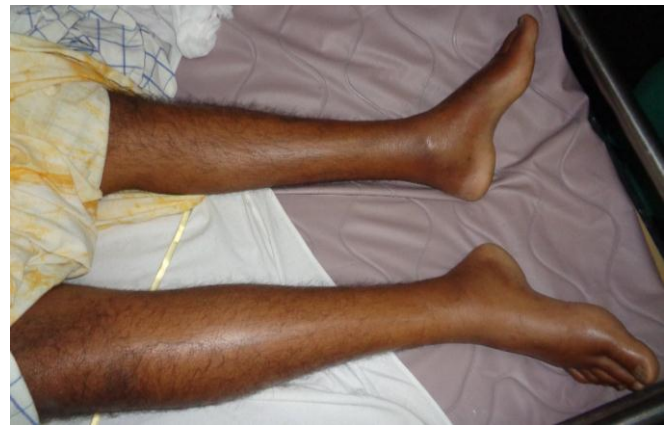

Figure 4. Deep vein thrombosis of right leg on day 9 of snakebite

by Russell's viper envenoming are intracranial bleeding [8] and pulmonary hemorrhage [9]. The venom of *Daboia russelii* contains hemotoxins which cause VICC and hemorrhages [10], such as basic coagulant metalloprotease (RVBCMP), snake venom serine proteinase (SVSPs), snakec (SCLs), and L-amino acid oxidase (LAAOs). RVBCMP is organ specific and has a direct action on lung microvasculature, which leads to pulmonary hemorrhage [11]. The hemotoxins do not induce bleeding equally in all human organs [12] which may be due to differences in the biochemical nature of the vascular wall. In mouse model, the venom has in-vitro hemorrhagic like activity in lungs, liver, kidneys, brain and heart [13]. Pulmonary hemorrhage following snake envenoming is a rare complication and is exclusively due to viper bites. Other snakes that cause fatal pulmonary hemorrhage include *Bothrops* species endemic to Central and South America [14],[15] and hump-nosed pit vipers (*Hypnale hypnale*) of Sri Lanka [16]. There is recent evidence of the Australian eastern brown snake (*Pseudonaja textilis*) causing fulminant pulmonary hemorrhage in dogs [17]. It was found that jararhagin, a metalloproteinase from *Bothrops jararaca* induces lung hemorrhage [15]. Other pulmonary effects such as acute respiratory distress syndrome (ARDS) and pulmonary edema following snakebites are rarely reported. However, pulmonary edema was found upon autopsy examination following Russell's viper bites [18] and hump-nosed viper (*Hypnale zara*) bites [19].

Pulmonary hemorrhage is acute bleeding or oozing of blood from the respiratory tract. Diffuse alveolar hemorrhage occurs due to widespread disruption of alveolar-capillary basement membranes, which leads to blood collecting within the alveoli. This may clinically manifest as hemoptysis, dyspnea, tachypnea and airspace opacities in radiological images. Our patient on day 1 may have had pulmonary hemorrhage, which could explain why he had bleeding from the laryngeal outlet upon intubation, and blood stained secretions from the endotracheal tube. After extubation on day 5, he also had hemoptysis and HRCT of the chest confirmed the possibility of pulmonary hemorrhage (Figure 3). He had high creatine phosphokinase (CPK) levels,

Table 1. Laboratory findings of the patient

Investigation	Reference range	Days from the snakebite											
		1	2	3	4	5	6	7	8	9	10	11	12
WBC (x10 ³ /μL)	4-11	26	27	20	13	13	13	15	13	16	20	19	18
Neutrophils (%)	50 -70	94	96	86	83	83	84	77	76	75	73	79	81
Hb (g/dL)	11-16	12.7	13.4	11.9	10.7	11.1	9.7	10.2	9.6	9.6	9.3	8.1	8.3
Platelets (x10 ³ /μL)	150-450	238	253	168	158	185	170	168	143	156	220	266	365
PT (sec.)	10-15	>80/12	19/12	16/12	15/12	14/12	18/12	14.6/12	14/12	15.8/12	28/12	20.9/12	15.3/12
INR	1 - 1.4	> 6	1.59	1.35	1.25	1.17	1.51	1.22	1.11	1.32	2.37	1.76	1.2
APTT (sec.)	25 - 30	>60/32	35/32	26/32	32/32	32/32	25/32	31.6/32	33/32	32/32	56/32	38.4/32	44/32
Na ⁺ (mmol/L)	135- 145	144	141	146	146	150	150	144	142	139	140	138	141
K ⁺ (mmol/L)	3.5 – 4.5	3.4	6.7	4.5	3.8	3.9	4.7	4.2	4.1	4.3	4.1	4.1	4.4
Creatinine (μmol/L)	60-115	153	231	284	236	212	212	177	163	142	144	119	107
Blood urea (mmol/L)	7.8-20.1	6.7	11.7	15.8	18.1	23	22.3	15.2	16	14	10	9	8
SGOT(AST) [U/I]	0 - 35	128	208	235	160	154	106	89	63	50	42	56	80
SGPT(ALT) [U/I]	0 - 45	38	46	51	47	54	47	50	42	36	30	23	48
T.Bilirubin (μmol/L)	5 - 21	17	7.2	8.3	9.7	11.3	10.3	12.9	10.5	10.7	9	4.6	6
CRP (mg/L)	< 6		9	201	234	257	189	116	128	192	168	136	117
CPK (U/I)	26-174			13024	6818	6327	3125	1468	1464		191		
pH	7.35-7.4	7.344	7.352	7.409	7.528	7.522	7.524	7.49	7.488	7.505	7.515	7.507	7.520
PCO ₂ (mmHg)	35-40	30	36	45	42	44	35	28	31	28	24	29	24
PO ₂ (mmHg)	100	111	120	149	131	130	111	115	83	84	158	66	71
FiO ₂		100	100	60	60	40	21	60	60	40	21	21	40
PO ₂ /FiO ₂		111.4	120	248	219	324	525	192	138	210	757	318	177

which gradually decreased (Figure 2D), suggesting rhabdomyolysis, a known complication in Russell's viper envenoming [5]. Also, the patient had elevated levels of creatinine and blood urea (Figure 2C), though normal urine output was maintained with a furosemide infusion. There was no metabolic acidosis seen in arterial blood gas analysis and serum potassium levels were also normal throughout except day 2, therefore, he did not need hemodialysis. Due to pulmonary hemorrhage, hemoglobin level persistently decreased (Figure 2A) and the patient had venom-induced thrombocytopenia (Figure 2B). However, peripheral blood microscopy showed no evidence of microangiopathic hemolysis. He also had cardiotoxic effects manifested as ischemic changes on the ECG and impairment of ejection fraction with global hypokinesia.

Snakebite has a significant impact on human health and economy through treatment-related expenditures and loss of productivity [20]. Early administration of anti-venom has been accompanied by significant improvement in outcomes [21]. This index case history conveys the deadly nature of viperid snake venom which results in fatal systemic bleeding to vital organs.

CONCLUSION

Severe fatal systemic manifestations like pulmonary

hemorrhage may rarely occur following Russell's viper bites. These patients need mechanical ventilation with intensive care treatment and prolonged hospital stay. Early elective intubation is beneficial and antivenom is the mainstay of management.

ACKNOWLEDGEMENT

We thank Consultant Physician (Dr.K.D.M. Kumarasinghe), Respiratory Physician (Dr.N. Dissanayaka), Anesthetists (Dr.R. Jayathilaka, Dr.J.J. Wanigaratne), medical officers and staff of Intensive Care Unit, Teaching Hospital, Ratnapura, Sri Lanka.

Conflict of Interest: None to be declared.

Funding and Support: None.

REFERENCES

1. Anonymous, 2010. WHO Guidelines for the production control and regulation of snake antivenom immunoglobulins. WHO Technical Series, pp. 1-134. www.who.int/blood_products/snakeantivenoms
2. De Silva A, Ranasinghe L. Epidemiology of snake-bite in Sri Lanka: a review. *Ceylon Med J.* 1983;28(3):144-54.
3. Kasturiratne A, Wickremasinghe AR, de Silva N, Gunawardena NK, Pathmeswaran A, Premaratna R, et al. The global burden of snakebite: a literature analysis and modeling based on regional estimates of envenoming and deaths. *PLoS Med.*

- 2008;5(11):e218.
4. Kularatne SAM. Epidemiology and clinical picture of the Russell's viper (*Daboia russelii russelii*) bite in Anuradhapura, Sri Lanka: a prospective study of 336 cases. *Southeast Asian J Trop Med Public Health*. 2003;34:855-62.
 5. Phillips RE, Theakston RD, Warrell DA, Galigedara Y, Abeysekera DT. et al. Paralysis, rhabdomyolysis and haemolysis caused by bites of Russell's viper (*Vipera russelii pulchella*) in Sri Lanka: failure of Indian (Haffkine) antivenom. *QJM*. 1988;68: 691-715.
 6. Gnanathanan A, Rodrigo C. Pulmonary effects and complications of snakebites. *Chest*. 2014;146(5):1403-12
 7. Kularatne SAM. Common krait (*Bungarus caeruleus*) bite in Anuradhapura, Sri Lanka: a prospective clinical study, 1996-98. *Postgrad Med J*. 2002;78 (919):276 -80 .
 8. Namal Rathnayaka RMMK, Kularatne SAM, Kumarasinghe KDM, Janaka Ranaweera, Nishanthi Ranathunga PEA. Ischemic brain infarcts and intracranial haemorrhages following Russell's viper (*Daboia russelii*) bite in Sri Lanka. *Toxicon*. 2017;125:70-3
 9. Palangasinghe DR, Weerakkody RM, Dalpatadu CG, Gnanathanan CR. A fatal outcome due to pulmonary hemorrhage following Russell's viper bite. *Saudi Med J*. 2015;36 (5):634-7
 10. Tan NH, Fung SY, Tan KY, Yap MKK, Gnanathanan CA, Tan CH. Functional venomics of the Sri Lankan Russell's viper (*Daboia russelii*) and its toxinological correlations. *Journal of Proteomics*. 2015;128:403-23
 11. Mukherjee, AK. Characterization of a novel pro-coagulant metalloprotease (RVBCMP) possessing alpha-fibrinogenase and tissue haemorrhagic activity from venom of *Daboia russelii russelii* (Russell's viper): evidence of distinct coagulant and haemorrhagic sites in RVBCMP. *Toxicon*. 2008;51(5):923-33.
 12. Warrell DA. Snake venom in science and clinical medicine, 1. Russell's viper: biology, venom and treatment of bite. *Trans R Soc Trop Med Hyg*. 1989;83:732-40.
 13. Datta K, Bhattacharyya D. In vitro haemorrhage-like activity of Russell's viper (*Vipera russelii russelii*) venom from Eastern India with mice organs. *Current Science*. 1999;77:1673-76.
 14. Luiz A. Benvenuti, Francisco O.S. Franca, Katia C. Barbaro, Jose R. Nunes, Joao L.C. Cardoso. Pulmonary haemorrhage causing rapid death after *Bothrops jararacussu* snakebite: a case report. *Toxicon*. 2003;42(3):331-34
 15. Escalante T, Núñez J, Moura da Silva AM, Rucavado A, Theakston RD, Gutiérrez JM. Pulmonary hemorrhage induced by jararhagin, a metalloproteinase from *Bothrops jararaca* snake venom. *Toxicol Appl Pharmacol*. 2003;193(1):17- 28.
 16. Namal Rathnayaka RMMK, Nishanthi Ranathunga PEA, Kularatne SAM. Systemic bleeding including pulmonary haemorrhage following hump-nosed pit viper (*Hypnale hypnale*) envenoming: A case report from Sri Lanka. *Toxicon*. 2019;170:21-8
 17. Leong OS, Padula AM, Leister E. Severe acute pulmonary haemorrhage and haemoptysis in ten dogs following eastern brown snake (*Pseudonaja textilis*) envenomation: Clinical signs, treatment and outcomes. *Toxicon*. 2018;150:188-194
 18. Jeyarajah R. Russell's viper bite in Sri Lanka. A study of 22 cases. *Am J Trop Med Hyg*. 1984;33:506-10.
 19. Maduwage K, Kularatne K, Wazil A, Gawarammana I. Coagulopathy, acute kidney injury and death following *Hypnale zara* envenoming-The first case report from Sri Lanka. *Toxicon*. 2011;58(8):641-43
 20. Ratindra Nath Mondal, Fazie Rabbi Chowdhury, Monirani, Nur Mohammad, Islam MM, Mohammad Ashraful Haque, Mohammad Abdul Faiz. Pre-Hospital and Hospital Management Practices and Circumstances behind Venomous Snakebite in Northwestern Part of Bangladesh. *Asia Pac J Med Toxicol* 2012;1:18-21.
 21. Hafezi Gh, Rahmani A, Soleymani M, Nazari P. An Epidemiologic and Clinical Study of Snake Bites during a Five-Year Period in Karoon, Iran. *Asia Pac J Med Toxicol* 2018;7:13-6.