

A Fatal Case of Suicide Fruit Ingestion in Singapore by *Cerbera cardiac* Glycoside intoxication: Case report and review of literatures

YEE-SHAY LEE¹, DEEPAK GHIMIRAY¹, TO HANG LUI¹, YI JU YAO²

¹ Department of Intensive Care Medicine, Ng Teng Fong General Hospital, NUHS Juronghealth Campus, Singapore

² Division Director of Analytical Toxicology Division, Health Sciences Authority

Abstract

Case Presentation: We present a case of lethal glycoside toxicity from *Cerbera* fruit ingestion. Despite the patient's asymptomatic presentation, life threatening clinical features such as hyperkalaemia, hypotension and arrhythmia occurred later. Treatments for cardiac glycoside toxicity were instituted: activated charcoal (AC), atropine, hyperkalaemia management, digoxin immune Fab (DigiFab) and intravenous lipid emulsion (ILE). Advanced Cardiac Life Support (ACLS) was instituted with automated chest compression device. The patient died despite prolonged of resuscitation effort. *Cerbera* glycoside toxicity warrants serious consideration in view of rare presentation and unpredictable nature of toxicology. **Discussion:** We highlight the prevalence of *Cerbera* species in Asia-Pacific and present the similarities of cardiac glycosides pharmacology. Early recognition of ingestion and cardiac monitoring are particularly important. In this case, patient deteriorated despite normal serum digoxin level. This poses significant diagnostic and prognostic challenge. As the evidence of *Cerbera* glycoside poisoning treatment options is lacking, we take this opportunity to examine treatment options in assumption of similar pharmacology among cardiac glycoside family. We present in-dept discussion on digoxin antidote, multidose-activated charcoal (MDAC), ILE to reduce of serum free glycoside. Electrical and pharmacology treatment for arrhythmia were explored. We propose ECMO should always be considered for cardiac toxicity in anticipation of treatment failure.

Conclusion: *Cerbera* glycoside poisoning should be treated with utmost caution as the fruit is easily accessible and highly toxic. Close cardiac monitoring is a must due to high mortality risk. DigiFab should be instituted as guided by toxicologist. Patients should be transferred to ECMO centre for observation in all cases due to the unpredictable nature of toxin. Further investigation of treatment is awaited.

Key Words: Cardiac glycoside; Apocynaceae; forensic toxicology; extracorporeal membrane oxygenation

How to cite this article: Lee YS, Ghimiray D, Lui TH, Yao YJ. A Fatal Case of Suicide Fruit Ingestion in Singapore by *Cerbera Cardiac Glycoside* Intoxication: Case Report and Review of Literature. *Asia Pac J Med Toxicol* 2020; 9(3):123-128.

CASE REPORT

A 22-year-old Singaporean female with history of depression was referred from psychiatric clinic after she allegedly ingested two kernels of *Cerbera odollam* 16 hours prior. She was referred to emergency department after she presented to her psychiatrist and expressed that she has not died after her suicide attempt. Ingestion of powder from two ground *Cerbera odollam* fruit kernels was confirmed after collaborative history with mother and visual inspection of kernels brought in by her mother. Her vital parameters were normal on presentation. She did not exhibit any toxidrome and physical examination were unremarkable except electrocardiogram (ECG) changes.

Her initial serum chemistries were normal except for hyperkalaemia of 5.3mmol/L which rapidly rose to 9.8mmol/L within three hours despite medical therapy. Serum digoxin level was undetectable. At the same time, she

developed frequent arrhythmia. Changes in ECG are demonstrated in Figure 1.

Medical management for hyperkalaemia was instituted: IV 50% dextrose with 10 Unit Insulin, 10mmol of calcium gluconate, and 100 ml of 8.4% sodium bicarbonate. IV atropine 0.6 mg was administered for bradycardia. As part of cardiac glycoside toxicity treatment, 200mg (Five vials; 40 mg per vial) of DigiFab was administered as boluses. She was admitted into the High Dependency Unit (HDU) for further monitoring and commenced on urgent continuous renal replacement therapy (CRRT) for life threatening hyperkalaemia.

30 minutes into CRRT, she developed persistent cardiac arrest and was resuscitated as per advanced cardiovascular life support (ACLS) algorithm. She was intubated and ventilated. Chest compression was continued with LUCAS CPR device.

Another five vials of DigiFab was administered with no

*Correspondence to: Yee-Shay Lee, PhD, Resident Physician, 1 Jurong East Street 21, Singapore 609606.
Email: lee.yeeshay@gmail.com, Tel: +6583433276

response. 500mL of 20% Lipofundin was administered but no improvement was observed. Electrical cardioversions were administered for ventricular fibrillation (VF) in between pulseless electrical activity (PEA). Subsequently, she went

into asystole with no return of spontaneous circulation. After 1.5 hours of CPR, resuscitation was deemed futile and ceased. Her treatment timeline has been showed in Figure 2. Subsequently, coroner’s toxicology diagnostics detected neriifolin (de-acetylated cerberin), confirming ingestion of *Cerbera* fruit.

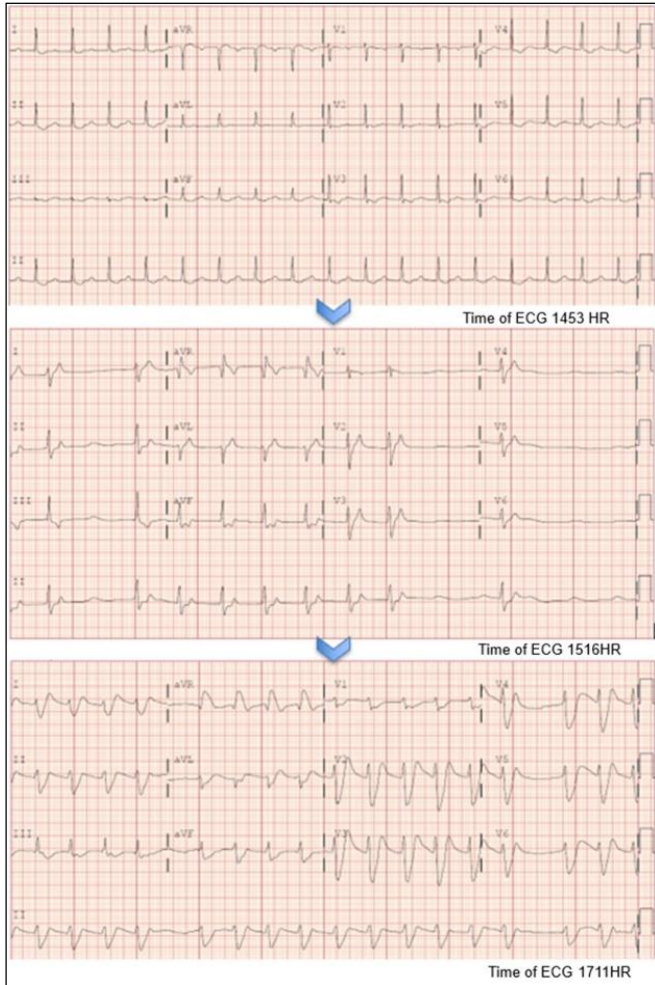


Figure 1. First ECG demonstrated first degree AV block with PR of 206 msec and T-wave inversions in the anterolateral leads. Subsequently, junctional rhythm evolved into idioventricular rhythm despite medical therapies.

DISCUSSION

Cerbera species, otherwise known as Pong-pong or suicide fruit trees, are found along the tropical coastal region of Africa to Asia-Pacific.(1) It is commonly found in Singapore parks and it is purchasable online.(2–6) Easy accessibility of this fruit renders it a dangerous choice for those who are determined in suicide attempt. Medical knowledge in managing *Cerbera* ingestion is lacking among the medical community despite quoted mortality risk up to 20%.(7–9) Cerberin, neriifolin, tanghinin and peruvoside are among the cardenolide group glycosides detected in Pong-pong fruit.(10,11) They share similar molecular structures and are thought to be responsible for toxicity. Its pharmacology has not been well established in vivo.

Pharmacology of Glycosides in *Cerbera* Species

Cerberin and neriifolin bear molecular structure similarities to digoxin in the cardiac glycoside family.(12) Glycosides are 4 carbocycles constituting a steroidal group, a sugar moiety linked to “A” ring and a lactone moiety linked to “D” ring as shown in Figure 3. Both cerberin and neriifolin have a shorter sugar chains in comparison to digoxin as shown in Figure 4.

Sharing similar chemical structure to digoxin, it is not unreasonable to approximate the pharmacokinetics of these cardiac glycosides with the better studied digoxin due to insufficient pharmacological data. In terms of bioavailability, digoxin has 60-80% bioavailability with 25% protein binding.(13) Digoxin is a lipophilic molecule with a large volume of distribution (5-6 L/kg) and is renally excreted. In the absence of formal studies, understanding on *Cerbera* glycoside poisoning needs to be extrapolated from management of cardiac glycoside toxicity.

Cerberin and neriifolin, as with all glycosides, inhibit the sodium-potassium adenosine triphosphatase (Na⁺/K⁺/ATPase)

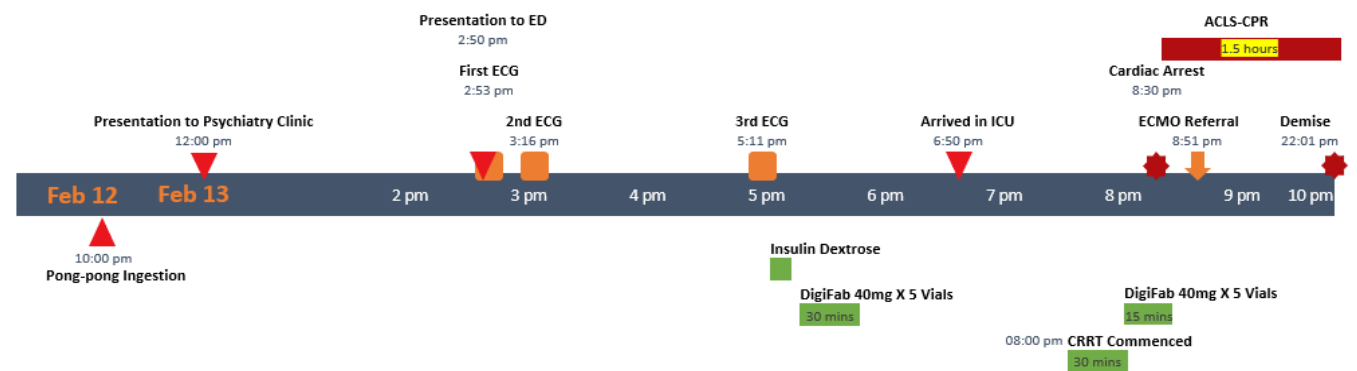


Figure 2. Timeline of Pong-pong ingestion until demise; ED: Emergency Department; ICU: Intensive Care Unit; ACLS: Advanced Cardiac Life Support; ECMO: Extra-Corporeal Membrane Oxygenation

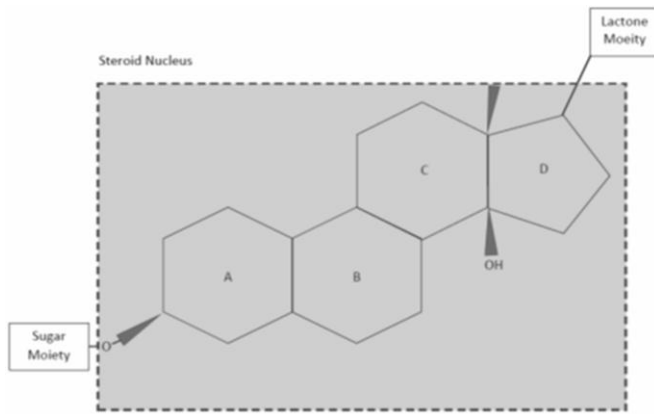


Figure 3. Glycoside molecular structure, adapted from Prassass & Diamandis 2008 (12)

sodium-calcium exchange. This causes an increase in intracellular calcium ion concentration, positive inotropy and lengthening of phase 0 and 4 of cardiac action potential. They also cause negative chronotropy through increased vagal tone by impeding conduction through the atrio-ventricular node.

The lethal dose of *Cerbera* glycoside is not well established. There have been reports of lethality from ingestion of a single seed kernel.(14,15) Early symptoms of cardiac glycoside toxicity can be non-specific including anorexia, nausea, vomiting, lethargy, headache, confusion, and visual disturbance.(16,17) The ECG changes described include (15):

1. Mild toxicity: T-wave flattening, ST depression
2. Moderate toxicity: Bradycardia – fascicular block, atrial fibrillation
3. Severe toxicity: Second to third degree heart block, sinus arrest, and ventricular arrhythmia recalcitrant to cardioversion.

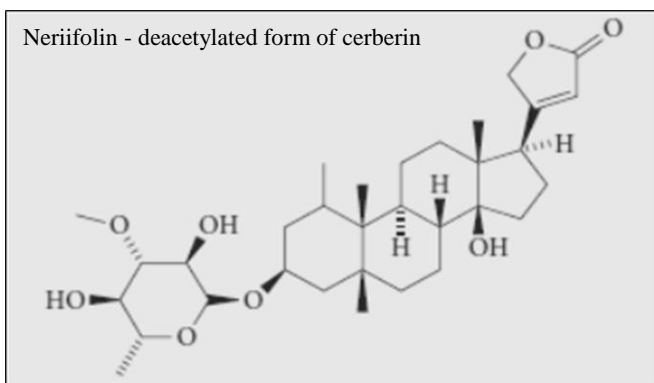
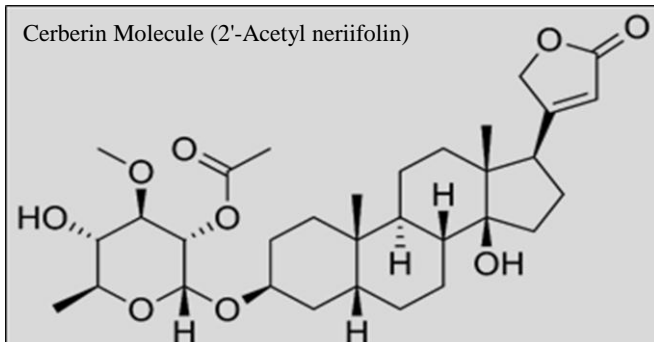
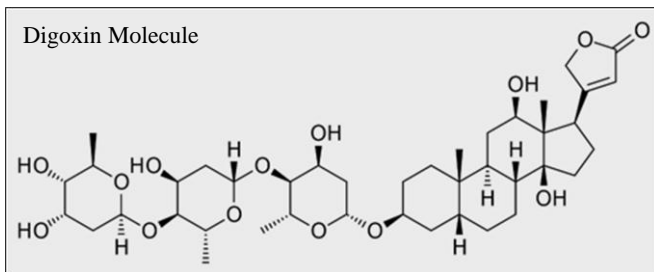


Figure 4. Molecular Structure of Digoxin, Cerberin & Neriifolin (12)

Full cardio-toxic effect of these glycosides may have delayed onset up to 24 to 48 hours later.(16,17) This poses significant diagnostic challenges and can be misleading to clinicians are unfamiliar with glycoside poisoning in asymptomatic patients.(7,8)

Diagnostic Tests and Forensic Testing

Confirmation of botanic glycosides poisoning poses a real diagnostic challenge in clinical context where patient's history and examination of the fruit is needed. In terms of laboratory investigation, botanic glycosides poisoning has been shown to cross-react with digoxin immunoassay and produce positive results.(4,7,8,14,18) However, plasma digoxin level from this patient was not detectable and it did not correlate with cerberin toxicity, despite its lethality. Accurate qualitative forensic diagnosis is made possible with liquid chromatography and mass spectroscopy (LC-MS). However, it requires turnover time of one to two days, rendering it clinically irrelevant in acute setting.

In this case, post-mortem urine toxicology was performed. Neriifolin was identified based on LC-MS spectral library which was employed locally by the Forensic Medicine Division of Health Sciences Authority (HSA). Cerberin was not detected in urine sample. This resembles a few reported cases where only neriifolin was detected in the biological specimens.(10,19) The metabolism in vivo of cerberin is not well-researched.(10,20) It is also likely that cerberin, also known as 2'-acetyl neriifolin, could have been hydrolysed by carboxyl-esterase to neriifolin in vivo.(21)

Prognostic Factors and Monitoring

Reports on prognostic factors of *Cerbera* glycoside poisoning have not been consistent. There have been case reports or case series reporting successful treatments of *Cerbera* glycoside toxicity.(7,8,14) Few prognostic factors identified in a study which correlate well with mortality are: ingestion of more than one kernels, vomiting, bradycardia, hyperkalaemia and hypotension.(10,15,22) As established in digoxin toxicity, hyperkalaemia and ECG changes have been known to correlate with digoxin level.(10,12,19,23–25)

exchanger in cardiomyocytes, leading to increasing intracellular sodium and subsequently decreasing activity of

Patients with these two clinical features should be treated with utmost caution. In view of high risk of cardiac arrhythmia, patient should be admitted for continuous ECG monitoring. (15)

Prevention of Absorption with Activated Charcoal and Gastrointestinal Decontamination

Activated charcoal works on toxin by adsorption, reducing GI absorption and reducing enterohepatic recirculation.(29) Its role in *Cerbera* glycoside toxicity remain unclear. There have been trials indicating multi-dose activated charcoal (MDAC) can be beneficial in glycoside poisoning.(26,30,31) The usual single-dose activated charcoal of 50-100g may be insufficient due to the unpredictable gastrointestinal transit time and glycoside absorption.(29,31) In a position statement by American Academy of Clinical Toxicology AACT and European Association of Poisons Centres and Clinical Toxicologists EACCT (1999), studies have been quoted showing significant reduction in drug half-life and increased drug clearance of digoxin.(16,32) MDAC has been trialled for oleandrin poisoning. The dosage of 50 -100g immediately, followed by 50g every subsequent 6 hours, elucidates a simple regimen with minimal side effects.(29,33) Activated charcoal has been shown to reduce plasma glycoside concentrations post-ingestion. However, the largest RCT to-date (Eddleston *et al.*, 2008) did not demonstrate survival benefit.(33) Gastric lavage remains as a controversial intervention as it is associated with aspiration risk. It can be considered within 60 minutes of toxin ingestion as decontamination, provided airway is protected.

Digoxin Immune Fab as Antidote

The role of digoxin immune Fab (DigiFab) as an antidote for *Cerbera* glycoside remains unclear though has been proven successful in a number of cases.(14,20) Literature search has not discovered any study demonstrating molecular affinity of DigiFab with *Cerbera* glycosides; also, mortality benefit has been inconsistent. (24-28,32-35) However, successful used in digoxin and oleandrin, makes a compelling argument for the use of DigiFab in cerberin poisoning (23,24). Evidence-based guideline in the use of DigiFab has not been established; however the conventional approach is to estimate the amount of digoxin absorbed and match with the molar requirement of digoxin immune Fab.(16,24) Approach in *Cerbera* glycoside poisoning will require toxicologist input and adopt “dose and observe” strategy for ECG improvement and reduction of hyperkalaemia given unknown quantity of glycoside in the fruits.

Correction of Electrolyte Abnormality

Hyperkalaemia is associated with digoxin toxicity.(23–25) Little is known of cellular effect from active management of hyperkalaemia. Case series and trials have addressed hyperkalaemia by using the standard treatments i.e. potassium binder, intravenous dextrose-insulin, sodium bicarbonate.(24,25) Calcium replacement to “stabilize” the cell membrane in glycoside toxicity remains controversial.(16) It is commonly speculated that “stone heart syndrome” may develop as a result of calcium

infusion.(16,37) However, it was not proven in animal model.(38)

Arrhythmia Treatment

Arrhythmia is a late and ominous sign in cardiac glycoside toxicity. Pharmacological as well as electrical treatments has been described as rescue measures. Atropine has been used routinely in response to bradycardia.(16,24) It works by obliterating the vagal activity in the context of bradycardia but does not address the issue of auto-rhythmicity. Hence, the benefit of atropine use remains unclear. Isoprenaline has been used in Sri Lanka to treat bradyarrhythmia in anecdotal reporting.(25) Electrical therapies, such as temporary pacing and cardioversion, have been administered in patients with digoxin toxicity in conjunction with DigiFab.(24) However, observational studies of Cerberin glycoside poisoning in Sri Lanka did not demonstrate promising results.(17)

Serum Toxin Reduction and Elimination

Utility of intravenous lipid emulsion (ILE) has been proven in local anaesthetic (LA) toxicity and cardiotoxic medication also in majority of lipophilic drugs based on “lipid sink theory”.(37-39) ILE reduces unbound molecule fractions by molecular carriage hence reducing action on myocardium. There has been increasing application of ILE in treating *non*-LA toxicity after the success garnered in treating animal model LA toxicity. It has been used in cardiac toxicity caused by organophosphate, calcium channel blockers, beta-blockers and psychotropics (39-40). In Glycoside poisoning, ILE was demonstrated to be effective in delaying cardiac arrest in rat model with digoxin toxicity, however its use in humans has not been tested.(38) Considerations must be taken before ILE is given as it may affect ECMO function by increase the risk of clotting in oxygenator membrane.(41) Should ECMO use is anticipated, ILE should be avoided.

Although digoxin is renally cleared, there is limited evidence of extracorporeal treatment use in eliminating glycoside.(41-44) Many other extra-corporeal interventions such as haem-charcoal perfusion (HCP), plasma exchange (PE) has been postulated to remove glycoside molecules. However, none has good evidence and therapy such as HCP has fallen out of favour.

Cardiac Support

Venous-Arterial ECMO has been hailed as cardiac supportive therapy in patients with cardiopulmonary arrest whilst borrowing time for treatment to work. Its application in toxin related cardiogenic shock will become more prevalent with increased availability and familiarity. ECMO should be considered should pharmacological treatment fails. It offers up to 80% survival rate in cases of poisoning with cardiogenic shock or cardiac failure.(45-46) As a novel and resource-intensive intervention, decision-making process for ECMO activation has remained remain complex and challenging. It is reasonable to discuss with ECMO specialist and transfer high-risk patient to ECMO-capable centre in anticipation of cardiovascular collapse.

CONCLUSION

The authors call for medical community to treat *Cerbera* glycoside poisoning with utmost caution as the fruit is easily accessible and highly toxic. Admission for close cardiac monitoring is a must due to high mortality risk. DigiFab should be instituted as guided by toxicologist. Patients should be transferred to ECMO centre for observation in all cases due to the unpredictable nature of toxin. Further investigation of *Cerbera* glycoside toxicity treatment is awaited.

REFERENCES

- Gaillard Y, Krishnamoorthy A, Bevalot F. *Cerbera odollam*: a "suicide tree" and cause of death in the state of Kerala, India. *J Ethnopharmacol.* 2004; 95:123–6.
- Cerbera odollam*. Available from: <https://lkcnm.nus.edu.sg/dna/organisms/details/302> Accessed August 11, 2019
- Flora Fauna Web. [cited 2019 Nov 12]. Available from: <https://florafaunaweb.nparks.gov.sg/Special-Pages/plant-detail.aspx?id=2800> Accessed August 11, 2019
- Menezes RG, Usman MS, Hussain SA, Madadin M, Siddiqi TJ, Fatima H, et al. *Cerbera odollam* toxicity: A review. *J Forensic Leg Med.* 2018; 58:113–6.
- Severson E, Jufer-Phipps R, Fowler DR, Alexander R. Beyond the Boundaries of Forensic Toxicology - the Use of an Atypical Consultant in a Rare Case of Cerberin Poisoning. *Academic Forensic Pathology.* 2015; 5:140–4.
- Kassop D, Donovan MS, Cohee BM, Mabe DL, Wedam EF, Atwood JE. An unusual case of cardiac glycoside toxicity. *Int J Cardiol.* 2014;170: 434–7.
- Eddleston M, Haggalla S. Fatal injury in eastern Sri Lanka, with special reference to cardenolide self-poisoning with *Cerbera manghas* fruits. *Clin Toxicol.* 2008; 46:745–8.
- Carlier J, Guitton J, Bévalot F, Fanton L, Gaillard Y. The principal toxic glycosidic steroids in *Cerbera manghas* L. seeds: Identification of cerberin, neriifolin, tanghinin and deacetyltanghinin by UHPLC–HRMS/MS, quantification by UHPLC–PDA-MS. *Journal of Chromatography B.* 2014; 962:1–8.
- Cheenpracha S, Karalai C, Rat-A-Pa Y, Ponglimanont C, Chantrapromma K. New cytotoxic cardenolide glycoside from the seeds of *Cerbera manghas*. *Chem Pharm Bull.* 2004; 52:1023–5.
- Prassas I, Diamandis EP. Novel therapeutic applications of cardiac glycosides. *Nat Rev Drug Discov.* 2008; 11:926–35.
- Nelson LS, Hoffman RS, Howland MA, Lewin NA, Goldfrank LR. *Goldfrank's Toxicologic Emergencies*, Eleventh Edition. McGraw Hill Professional; 2018.
- Wermuth ME, Vohra R, Bowman N, Furbee RB, Rusyniak DE. Cardiac Toxicity from Intentional Ingestion of Pong-Pong Seeds (*Cerbera Odollam*). *J Emerg Med.* 2018; 55:507–11.
- Menon MS, Kumar P, Jayachandran CI. Clinical Profile and Management of Poisoning with Suicide Tree: An Observational Study. *Heart Views.* 2016; 17:136–9.
- Roberts DM, Gallapatthy G, Dunuwille A, Chan BS. Pharmacological treatment of cardiac glycoside poisoning. *British Journal of Clinical Pharmacology.* 2016; 81:488–95.
- Khajja BS, Sharma M, Singh R. Forensic Study of Indian Toxicological Plants as Botanical Weapon (BW): A Review. *Journal of Environmental & Analytical Toxicology.* 2011; 1: 112.
- Radford DJ, Cheung K, Urech R, Gollogly JR, Duffy P. Immunological detection of cardiac glycosides in plants. *Aust Vet J.* 1994; 71:236–8.
- Laphookhieo S, Cheenpracha S, Karalai C, Chantrapromma S, Rat-a-Pa Y, Ponglimanont C, et al. Cytotoxic cardenolide glycoside from the seeds of *Cerbera odollam*. *Phytochemistry.* 2004; 65: 507–10.
- Maillaud C, Lefebvre S, Sebat C, Barguil Y, Cabalion P, Cheze M, et al. Double lethal coconut crab (*Birgus latro* L.) poisoning. *Toxicol.* 2010; 55:81–6.
- Laizure SC, Herring V, Hu Z, Witbrodt K, Parker RB. The role of human carboxylesterases in drug metabolism: have we overlooked their importance? *Pharmacotherapy.* 2013; 33:210–22.
- Renymol B, Palappallil D, Ambili N. Study on clinical profile and predictors of mortality in *Cerbera odollam* poisoning. *Indian J Crit Care Med.* 2018; 22:431–4.
- Bismuth C, Gaultier M, Conso F, Efthymiou ML. Hyperkalemia in Acute Digitalis Poisoning: Prognostic Significance and Therapeutic implications. *Clinical Toxicology.* 1973; 6: 153–62.
- Antman EM, Wenger TL, Butler VP Jr, Haber E, Smith TW. Treatment of 150 cases of life-threatening digitalis intoxication with digoxin-specific Fab antibody fragments. Final report of a multicenter study. *Circulation.* 1990; 81:1744–52.
- Woolf AD, Wenger T, Smith TW, Lovejoy FH Jr. The Use of Digoxin-Specific Fab Fragments for Severe Digitalis Intoxication in Children. *N Engl J Med.* 1992; 326:1739–44.
- Roberts DM, Buckley NA. Antidotes for acute cardenolide (cardiac glycoside) poisoning. *Cochrane Database Syst Rev.* 2006; 4:CD005490. Available from: <http://dx.doi.org/10.1002/14651858.CD005490.pub2>. Accessed August 1, 2019.
- Rajakakke S. Management of yellow oleander poisoning. *Clin Toxicol.* 2009; 47:206–12.
- Cheung K, Urech R, Taylor L, Duffy P, Radford D. Plant cardiac glycosides and digoxin Fab antibody. *J Paediatr Child Health.* 1991; 27:312–3.
- Roberts DM, Southcott E, Potter JM, Roberts MS, Eddleston M, Buckley NA. Pharmacokinetics of digoxin cross-reacting substances in patients with acute yellow Oleander (*Thevetia peruviana*) poisoning, including the effect of activated charcoal. *Ther Drug Monit.* 2006; 28:784–92.
- Lip GY, Metcalfe MJ, Dunn FG. Diagnosis and treatment of digoxin toxicity. *Postgrad Med J.* 1993; 69:337–9. Available from: <http://pmj.bmj.com/cgi/doi/10.1136/pgmj.69.811.337> Accessed August 15, 2019
- de Silva HA, Fonseka MMD, Pathmeswaran A. Multiple-dose activated charcoal for treatment of yellow oleander poisoning: a single-blind, randomised, placebo-controlled trial. *Lancet.* 2003; 361:1935–8.
- American Academy of Clinical Toxicology, European Association of Poisons Centres and Clinical Toxicologists. Position Statement and Practice Guidelines on the Use of Multi-Dose Activated Charcoal in the Treatment of Acute Poisoning. *J Toxicol Clin Toxicol.* 1999; 37:731–51.
- Eddleston M, Juszczak E, Buckley NA, et al. Multiple-dose activated charcoal in acute self-poisoning: a randomised controlled trial. *Lancet.* 2008; 371:579–87.
- Dasgupta A, Emerson L. Neutralization of cardiac toxins oleandrin, oleandrigenin, bufalin, and cinobufotalin by digibind: Monitoring the effect by measuring free digitoxin concentrations. *Life Sciences.* 1998; 63:781–8.
- Bandara V, Weinstein SA, White J, Eddleston M. A review of the natural history, toxicology, diagnosis and clinical management of *Nerium oleander* (common oleander) and

- Thevetia peruviana* (yellow oleander) poisoning. *Toxicol.* 2010; 56:273–81.
34. Levine M, Nikkanen H, Pallin DJ. The effects of intravenous calcium in patients with digoxin toxicity. *J Emerg Med.* 2011; 40:41–6.
35. Hack JB, Woody JH, Lewis DE, Brewer K, Meggs WJ. The Effect of Calcium Chloride in Treating Hyperkalemia Due to Acute Digoxin Toxicity in a Porcine Model. *Journal of Toxicology: Clinical Toxicology.* 2004; 42:337–42.
36. Muller SH, Diaz JH, Kaye AD. Clinical applications of intravenous lipid emulsion therapy. *J Anesth.* 2015; 29:920–6.
37. Weinberg G. Lipid Rescue Resuscitation from Local Anaesthetic Cardiac Toxicity. *Toxicol Rev.* 2006; 25:139–45.
38. Yurtlu BS, Özbilgin Ş, Yurtlu DA, et al. Intravenous lipid emulsion prolongs survival in rats intoxicated with digoxin. *Am J Emerg Med.* 2016; 34:1112–6.
39. Bejarovski NG Lipid Rescue Therapy and High-Dose Insulin Euglycemic Therapy are Effective for Severe Refractory Calcium Channel Blocker Overdose: Case Report and Review of Literature. *Asia Pac J Med Toxicol.* 2013; 2(3): 114-116.
40. Mir SA & Rasool R Reversal Of Cardiovascular Toxicity in Severe Organophosphate Poisoning with 20% Intralipid Emulsion Therapy: Case Report and Review of Literature. *Asia Pac J Med Toxicol.* 2014; 3: 169-72.
41. Mowry JB, Burdmann EA, Anseeuw K, Ayoub P, Ghannoum M, Hoffman RS, et al. Extracorporeal treatment for digoxin poisoning: systematic review and recommendations from the EXTRIP Workgroup. *Clin Toxicol.* 2016; 54:103–14.
42. Nissenson AR, Fine RE. *Handbook of Dialysis Therapy* 5th ed. Elsevier, 2016;1143.
43. Wang GS, Levitan R, Wiegand TJ, Lowry J, Schult RF, Yin S, et al Extracorporeal Membrane Oxygenation (ECMO) for Severe Toxicological Exposures: Review of the Toxicology Investigators Consortium (Toxic). *J Med Toxicol.* 2016; 12:95–9.
44. Kim Z, Goldfarb D, S: Continuous Renal Replacement Therapy Does Not Have a Clear Role in the Treatment of Poisoning. *Nephron Clin Pract* 2010;115:c1-c6. doi: 10.1159/000286343
45. Wang GS, Levitan R, Wiegand TJ, Lowry J, Schult RF, Yin S, et al. Extracorporeal Membrane Oxygenation (ECMO) for Severe Toxicological Exposures: Review of the Toxicology Investigators Consortium (Toxic). *Journal of Medical Toxicology.* 2016 Mar 1;12(1):95–9. Doi: 10.1007/s13181-015-0486-8
46. Lewis, J., Zarate, M., Tran, S Albertson T. The Recommendation and Use of Extracorporeal Membrane Oxygenation (ECMO) in Cases Reported to the California Poison Control System. *J. Med. Toxicol.* 15, 169–177 (2019). <https://doi.org/10.1007/s13181-019-00704-3>