

Possible role of ECMO in multiorgan failure and prolonged CPR: Aluminum Phosphide poisoning

MAHDI DALIRI¹, AHMAD AMIN², ZIAE TOTONCHI², JAN SCHMITTO³, NASIM NADERI², MONA YADOLLAHI² AND SAEID HOSSEINI¹

¹Heart Valve Disease Research Center, Rajaie Cardiovascular Medical and Research Center, Iran University of Medical Sciences, Tehran, Iran

²Rajaie cardiovascular, medical and research center, Iran University of medical science. Tehran, Iran

³Department of Cardiac, Thoracic, Transplantation and Vascular Surgery, Hannover Medical School, Hannover, Germany

Abstract

Introduction: Aluminum phosphide (ALP) is one of the most common causes of poisoning. Also, it is commonly used to attempt suicide. Extracorporeal Membrane Oxygenation (ECMO) is a therapeutic method that supports the function of the heart and lungs, giving body enough time for detoxification and organ function improvement; therefore, management of the problem using ECMO is critical in these patients and increases the survival chance. Moreover, the impact of COVID-19 on the treatment course during the COVID-19 pandemic and the patients' involvement and contact with the virus is a critical issue with unknown consequences.

Case presentation: The patient was an 18-year-old girl who was hospitalized due to the poisoning aluminum phosphate. The ECMO was connected to the patient during CPR. Then, the patient was transported to a specialized healthcare facility. At the time of arrival, the EF (Ejection Fraction) was less than 5%. During the course of poisoning, the patient developed ARDS, fulminant hepatitis, massive gastrointestinal and vaginal bleeding, and septicemia. The ECMO was weaned on day 5 when the EF was reported 55%. In the following, the general and pulmonary conditions of the patient exacerbated when she was suspected of having COVID-19. The necessary therapeutic measures were done and finally, the patient was discharged after 45 days.

Conclusion: ECMO is a useful therapeutic procedure in ALP poisoned patients. In case of careful management, it can be used in multiple organ involvement and prolonged PCR. Considering the COVID-19 pandemic, it is very important to notice the chance of COVID-19 infection in ICU during treatment.

Keywords: Aluminum Phosphide, COVID-19, Extracorporeal Membrane Oxygenation, poisoning

How to cite this article: Daliri M, Amin A, Totonchi Z, Schmitto J, Naderi N, Yadollahi, M, Hosseini S. Possible role of ECMO in multiorgan failure and prolonged CPR: Aluminum Phosphide poisoning. *Asia Pac J Med Toxicol* 2020; 9(4):154-158.

INTRODUCTION

One of the most common insecticides and rodenticides used in agriculture is aluminum phosphide (ALP) [1, 2]. However, in the presence of moisture, for example in the human body after ingestion or inhalation of aluminum phosphide, this substance will result in the formation of phosphine gas [1, 2]. Therefore, this inhalation or ingestion can lead to toxicity in various organs in the body, including the heart, the kidneys, the lungs, and the liver [1-3]. The overall mortality rate reported for exposure to aluminum phosphide ranges from 30 to 77 percent [3-6]. Some of the suggested toxicity mechanisms for aluminum phosphide include suppressing oxidation in the mitochondria accompanied by significant reductions in the potential of the membrane of the mitochondria as well as the suppression of cytochrome C oxidase that results in higher levels of reactive oxygen species formation [7, 8]. Individuals exposed to aluminum phosphide will most likely suffer multisystem organ failure, followed by cardiovascular collapse, and

ultimately death.

On the other hand, since the dysfunction or failure of the left ventricular as well as respiratory problems caused by ALP poisoning can be potentially reversed during a 5 to 7-day window [2], it is recommended to employ a number of extracorporeal life support systems (ECLS), including Venous Arterial Extracorporeal Membrane Oxygenation (VA ECMO), which can help maintain the functionality of the lungs and the cardiovascular system on a temporary basis for patients with severe shock. Utilizing such systems can be helpful in improving the chance of survival for these patients.

In the current paper, a case is presented which may be the first published case on a patient with ALP poisoning who experienced cardiac arrest, while suffering from acute respiratory distress syndrome (ARDS), fulminant hepatitis, and highly suspicious for COVID-19. This patient received respiratory support as well as circulatory support using ECMO.

CASE REPORT

At 10 in the morning our team received information from

*Correspondence to: Mahdi Daliri, MD, Heart Valve Disease Research Center, Rajaie Cardiovascular Medical and Research Center, Iran University of Medical Sciences, Tehran, Iran

Phone: +989151040818, email: m_daliri@yahoo.com

Archive of SID

the healthcare center of downtown about a young patient consumed aluminum-phosphide tablet which is known as “rice pills or wheat pills” in Iran. The patient was not in good condition and it was a request for ECMO setup. Thus, a team consisting of a cardiac surgeon, an operating room nurse and two perfusionists was immediately dispatched by ambulance to the specified center which was 30 kilometers away. The patient was an 18 year old girl with Afghan nationality who migrated to Iran in childhood and was raised there as well. She had history of injuring her right arm with a blade due to family problems. She had no history of an underlying disease or specific drug use. The patient took one aluminum-phosphide tablet at 14 p.m. the day before admission and complained of nausea and vomiting with severe headache on afternoon whom finally was transferred to the Intensive Care Unit(ICU) of the given care center on that night. Upon our team arriving, the patient was not conscious and only responded subtly to painful stimulation. Glasgow Coma Scale (GCS) was estimated to be 5-6. She had severe bradycardia with no palpable pulses and there was profound acidosis. Therefore a surgical sterile environment was prepared on bedside during the time she developed cardiac fibrillation and arrest. CPR was initiated by a separate team. Cardiac surgeon exposed right femoral region and explored the femoral artery and vein. The femoral artery was found to be too narrow and unusual. Hence, the artery was dilated with Seldinger’s technique via several dilators and thereafter cannulated percutaneously with a 17 French cannula. Also a 6 French sheath was placed in the artery 1 cm away from the entrance point of arterial cannula and guided to the distal of limb. The proximal part of the sheath was attached to the arterial cannula using a connector for performing antegrade perfusion of

the distal limb. After that the vein was cannulated with a single stage cannula and connected to the ECMO to start the flow.

Patient began to respond to resuscitation after the initiation of ECMO and heartbeat returned but she was still bradycardic having wide QRS complexes. IV fluid was given through the peripheral access and the patient was transferred by ambulance to a specialized cardiovascular center with the team and the ECMO machine by her side. She developed several fibrillation episodes in the way for which DC shock according to the ACLS was given and breathing continued via the tracheal tube.

Upon admission, patient was transferred immediately to the ICU ward. Her blood pressure was 70/40(SBP/DBP) mmHg, serum lactate: 16.5, arterial pH: 7.18, Arterial O₂ Saturation: 99%, P_ACO₂: 42 and HCO₃: 17. Echocardiography demonstrated total LV akinesia with EF < 5%. A platelet count was around 222000 and HCT was 34. ECMO flow was set to 3.5 L/min and heparin given with ACT goal range of 180-220. Supportive measures were initiated and ventilator set to SIMV mode with TV: 400, RR: 16 and PEEP: 5. Inotropes epinephrine (0.05 µg/kg/min) and norepinephrine (0.5 µg/kg/min) was given. Urine output was acceptable.

During the 45 days of in-patient period, she developed low platelet counts, massive GI bleeding and generalized necrosis of the gastrointestinal mucosa, vaginal bleeding, fulminant hepatitis, ARDS, bilateral ischemic changes of lower limbs, profound psychological changes, sepsis, dysphagia, pleural effusion, diarrhea and arrhythmia. Management of the specified problems is discussed in the following. The patient was eventually discharged from hospital with good general condition. (Fig 1)

Acute heart failure: In the first day given the total LV &

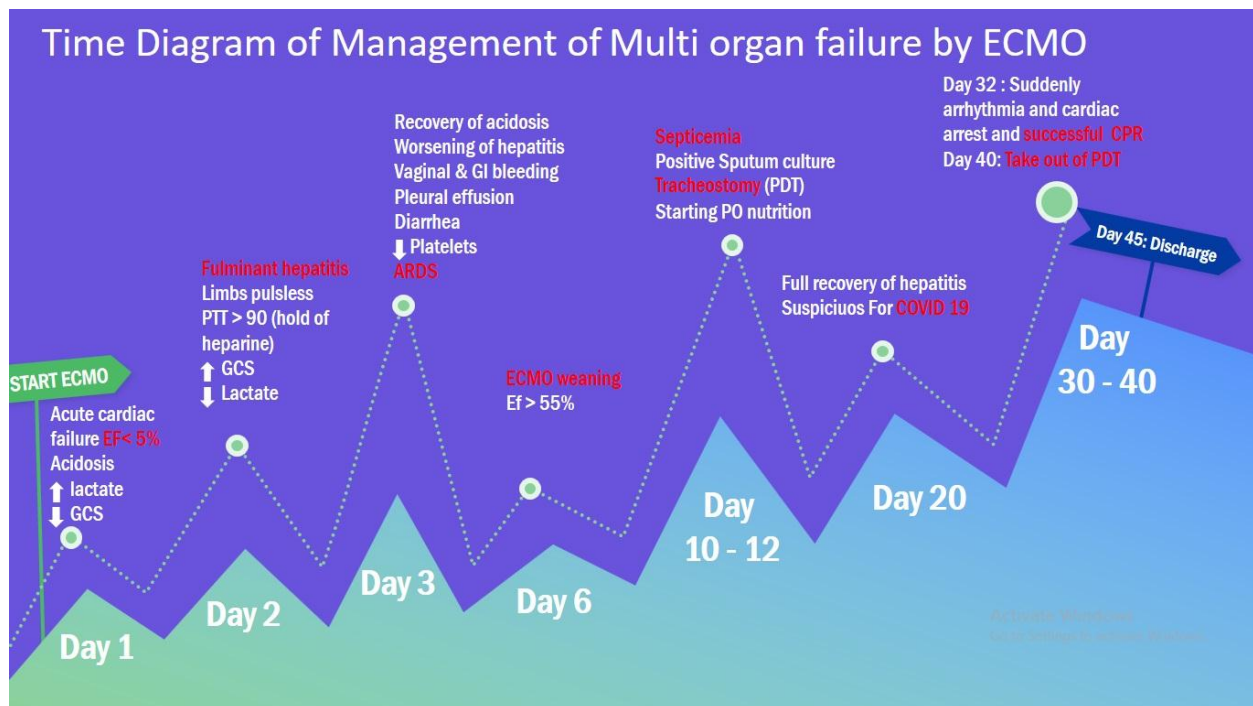


Fig 1. Time diagram of management of multiorgan failure by ECMO

RV akinesia a total flow of 3.5 Lit/min was set and according to the location of mixing zone at the aortic root with a flow higher than femoral artery and to prevent the harlequin syndrome, the oxygen flow was set at 100%. In this setting the SVO₂ will also stay high and prevents hypoxia of head, neck and upper limbs (especially left upper limb). With some resolution of acidosis and ABG findings the EF improved to 25-30% on the second day. Therefore, ECMO flow was decreased to 2.5 Lit/min to allow for some filling of the heart. According to the bleedings and coagulative disturbance and the need to discontinue heparin, the flow was increased later on to prevent thrombosis of the ECMO system. Inotropes were tapered gradually and daily serial echocardiography was performed. After the total resolution of lactate levels and observation of an appropriate ejection fraction on the arterial pressure monitoring system, the ECMO flow was decreased to 1.5 Lit/min in 4 days. Also Oxygen flow was decreased to 30% and after 24 hours having a flow of 1.5 Lit/min with EF = 55% and also a platelet count of 61000, platelets was reserved for the patient and she was transferred to the operating room. After giving heparin and having ACT > 400 the ECMO was discontinued. After one hour of observing good hemodynamics the ECMO was weaned and protamine given afterwards.

On day 32 the patient developed cardiac arrest without a clear discoverable etiology whom undergone CPR for 45 minutes and there was no decrease in EF on post resuscitation echocardiography.

Acute liver failure (fulminant hepatitis): The liver enzymes started to rise from the second day which came on peak on day 4 (CPK: 8000 IU/L (25-225), ALP: 126 IU/L (80-306), ALT: 141 IU/L (5-40), AST: 342 IU/L (5-40), LDH: 1500 IU/L (up to 480)). Therefore N-Acetyl Cysteine (1200 mg/q12h), vitamins C (2gr daily) & E (400 unit daily) and Lasix (80 mg/ 24 h) were given from the second day. Patient was kept NPO and completely recovered by day 20.

ARDS and COVID-19: The patient was intubated upon first visit. There were bilateral generalized changes in lungs. Tracheal tube was filled with abundant secretions therefore complete respiratory support initiated via ventilator machine. After resolving consciousness a complete sedation was given to prevent patient scrambles. Tracheostomy was performed on day 10 and tracheal tube discharged. According to improving Chest X-Ray findings the ventilator settings were changed gradually until days later that the tracheal tube was also discharged from the machine and [patient given] oxygen and finally exposing the room air. On day 20 the patient next to our patient died of respiratory distress whom PCR test was positive for COVID-19. Thereafter our patient also developed respiratory distress and new CXR findings. She was attached again to the ventilator and oropharyngeal specimens was obtained and sent to the lab which resulted two times suspicious for COVID-19. Thus a treatment regimen consisting of hydroxychloroquine and oseltamivir was given which fortunately gave rise to recovery and PDT was discontinued on day 40. Fig 2

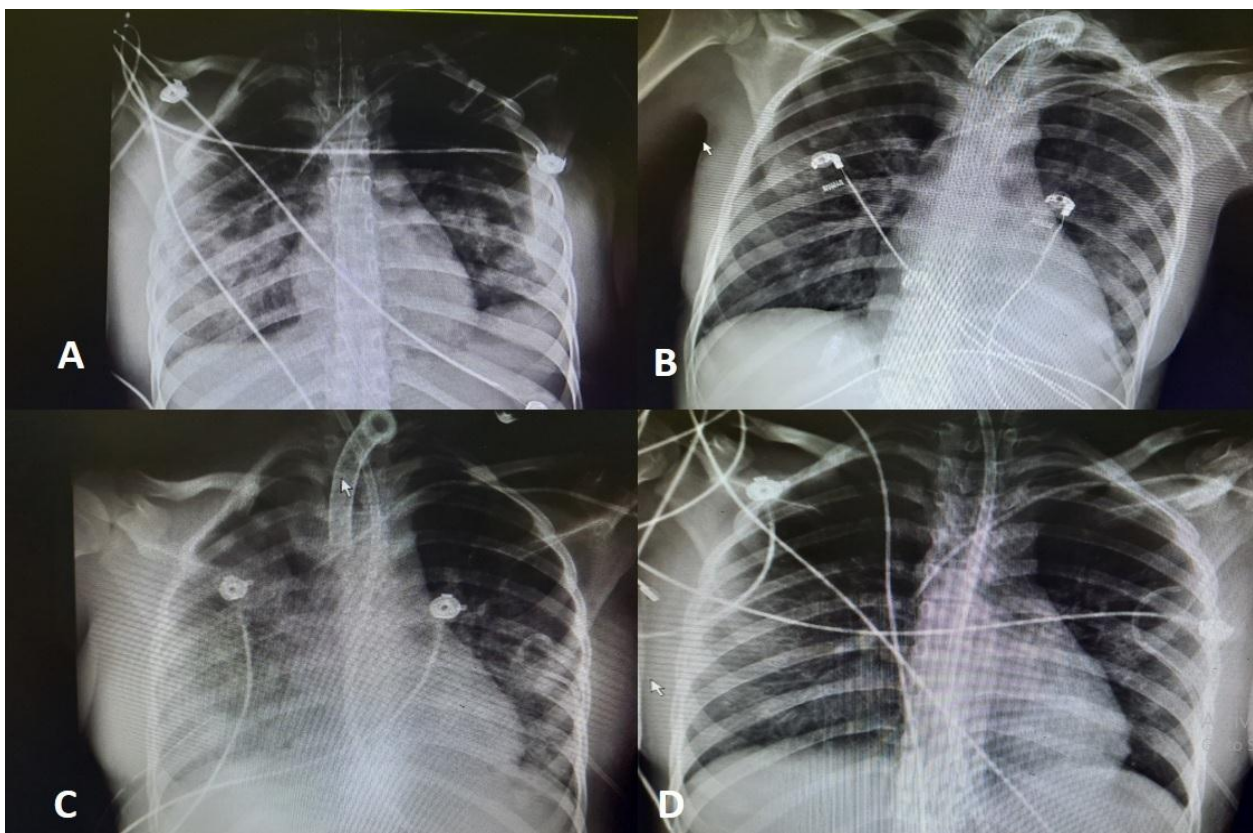


Fig 2. Chest Xray of patient. A: Day 1 at admission in hospital. B: Day 20 after recovery. C: Day 22: after suspicious Of COVID 19. D: Day 44 before discharge

Limb ischemia: Given the multi systemic involvement with aluminum-phosphide intoxication we noticed unusual narrowing of the femoral arteries upon exploring. Therefore an antegrade perfusion cannula was applied via a 6 French sheath to prevent distal limb ischemia. At first there was no detectable pulse which raised concerns regarding the contralateral limb (which had no cannula for ECMO). Therefore Doppler ultrasonography was performed which demonstrated arterial flow to the distal of the left limb but the vessels were too narrow in the entire path that was probably due to vascular involvement during intoxication. Hence, given the state of shock and unreliability of pulse oximetry "INVUS" pads were placed on both calves which indicated 73 and 75 in right and left limb, respectively. The number increased to 90 in the second day which was suspicious of poor oxygen absorption from the tissues and SVO₂ rise. A specimen was taken from both arterial and venous cannulas which demonstrated a PO₂ of 480 which decreased concerns. After discharging cannula the artery was primary closed as end to end.

Neurologic and psychologic involvement: Despite several CPR episodes the patient was fully awake and GCS = 14-15 from day 3. Fortunately she was awake with no complications after an effective CPR and hypotension prevention following a cardiac arrest in day 32.

According to the past history and long in-patient time and impossibility of presence of a companion due to coronavirus pandemic and presence of COVID-19 patients in ICU the patient developed depression and was not cooperating for treatment which was managed by consultation and medical anti-depressive drugs and also staff sacrifice for establishing a friendly communication with the patient to improve her morale.

Vaginal and gastrointestinal bleeding: Given the vaginal and upper & lower gastrointestinal bleeding heparin was discontinued on day 2 and endoscopy was done which indicated generalized injury of the gastrointestinal mucosa. Therefore irrigation with normal saline was initiated and octreotide and antacids were given. Patient was kept NPO and from day 10 according to dysphagia an oral regimen consisting of ice cream and cold liquids was given to improve ingestion and the regimen was gradually completed over time. The ECMO flow was increased after discontinuation of heparin to prevent system thrombosis. Heparin was initiated again from day 4 with PTT and ACT kept in the range of 50-70 and 180-220, respectively.

Sepsis and infection: On day 10 according to intermittent fever samples of sputum, blood and urine were taken and sent to the lab for culture which were positive for acinetobacter and candida for sputum and urine cultures, respectively. Therefore treatment regimens were changed based on antibiograms until all cultures were negative upon discharge.

On day 20 the patient was fully isolated because of probability of coronavirus infection and given the impossibility of transferring the patient to perform CT-Scan a PCR test was done after CXR which resulted suspicious and a two-drug regimen of hydroxychloroquine and oseltamivir was prescribed for 7 days.

Follow-up: The patient had no respiratory complaints on the

next month visit with EF = 55-60% and she was on regular diet. She couldn't walk because of severe muscle atrophy and low force that resolved completely after 3 months of physiotherapy when she could easily walk and run. The echocardiography was normal and tracheostomy site was completely repaired but she still complained of respiratory discharges and night time coughs.

DISCUSSION

Aluminum phosphide (AIP) poisoning can have a varied presentation and clinical course. The early symptoms can be nonspecific and include epigastric pain, vomiting, diarrhea, dizziness, and dyspnea. Cardiovascular complications including dysrhythmias (bradycardia and ventricular arrhythmias (VA) such as ventricular tachycardia (VT)) and systolic heart failure ranging from impaired cardiac function to complete cardiovascular collapse are common in AIP poisoning [7]

Extracorporeal membrane oxygenation (ECMO) has been well described for reversible cardiogenic shock in AIP-poisoned patients. Prompt referral to an ECMO center and initiation of support for patients with severe (or acute) metabolic acidosis, refractory shock, and severe left ventricular (LV) dysfunction, have been associated with improved survival [7, 8].

The mortality rate among AIP-poisoned patients varies from 40% to 80%. [9]. Once refractory myocardial depression sets in, which is not uncommon, the mortality rate further increases to 77% (37-100%) [9, 10] Reportedly, resistant hypotension and metabolic acidosis are robust predictors of poor prognosis after AIP poisoning [11]. Based on the literature, the mortality rate of a combination of acute respiratory distress syndrome (ARDS), acute liver failure (ALF), and cardiogenic shock (CS) is nearly 100%, like our case [12].

In other case series and case reports of ALP poisoning, who had been treated with ECMO, the lowest ejection fraction (EF) was 20% [13-15]. However, in our case, EF was less than 5%, and maybe it was the first case of global myocardial akinesia in ALP poisoning who was treated with ECMO. The EF of our patient was less than 5% at presentation, improved to 55% at the time of ECMO decannulation, and further improved to 60% after a 3-month follow-up.

We presented a rare case of AIP poisoning that was associated with CS, VA, liver (or hepatic) involvement, and ARDS in the COVID 19 pandemic, who had a cardiac arrest and successful resuscitation multiple times. Despite her severe clinical presentation, she had complete normalization of her end-organ dysfunction. Given the multisystem organ failure (MOF) and high risk of morbidity and mortality, we would recommend prompt referral to a tertiary care center with ECMO capability and an experienced team in cases of suspected or documented AIP poisoning. Furthermore, our case highlights various complications of ECMO and their solution. On the other hand, our patient was highly suspicious of COVID 19.

Thus, the use of ECMO in patients with acute ALP poisoning with severe shock saves young lives even in MOFs. We can expand the indication for ECMO to other MOF patients.

REFERENCES

1. Shadnia S, Sasanian G, Allami P, Hosseini A, Ranjbar A, Amini-Shirazi N, et al. A retrospective 7-years study of aluminum phosphide poisoning in Tehran: opportunities for prevention. *Hum Exp Toxicol* 2009 Apr;28(4). 209-13.
2. Proudfoot AT. Aluminium and zinc phosphide poisoning. *Clin Toxicol* 2009 Feb 1;47(2):89e100.
3. Bumbrah GS, Krishan K, Kanchan T, Sharma M, Sodhi GS. Phosphide poisoning: a review of literature. *Forensic Sci Int* 2012 Jan 10;214(1e3):1e6.
4. Sharma A, Dishant VG, Kaushik JS, Mittal K. Aluminum phosphide (celphos) poisoning in children: a 5-year experience in a tertiary care hospital from northern India. *Indian J Crit Care Med: peer-reviewed, official publication of Indian Society of Critical Care Medicine* 2014 Jan;18(1):33.
5. Moller PE, Kristensen AK, Bredahl C. Survival after oral poisoning with insecticide against moles containing aluminium phosphide. *Ugeskr Laeger* 2013 Jun;175(24). 1704-5.
6. Mehra A, Sharma N. ECMO: A ray of hope for young suicide victims with acute aluminum phosphide poisoning and shock. *Indian heart journal* 68(2016) 256-257.
7. Elabbassi W, Chowdhury MA, Fachtartz AA. Severe reversible myocardial injury associated with aluminium phosphide toxicity: a case report and review of literature. *Journal of the saudi heart association* 2014 Oct 1;26(4). 216-21.
8. Mohan B, Gupta V, Ralhan S, Gupta D, Puri S, Wander GS, et al. Role of extracorporeal membrane oxygenation in aluminum phosphide poisoning-induced reversible myocardial dysfunction: a novel therapeutic modality. *J Emerg Med* 2015 Nov 1;49(5). 651-6.
9. Chugh SN, Arora BB, Malhotra GC. Incidence and outcome of aluminium phosphide poisoning in a hospital study. *Indian J Med Res.* 1991;94:232–235.
10. Bogle RG, Theron P, Brooks P, Dargan PI, Redhead J. Aluminium phosphide poisoning. *Emerg Med J.* 2006; 23:e3
11. Singh S, Singh D, Wig N, Jit I, Sharma BK. Aluminum phosphide ingestion – a clinico-pathologic study. *J Toxicol Clin Toxicol.* 1996;34:703–706.
12. Tripathi SK, Gautam CS, Sharma PL. Clinical pharmacology of aluminium phosphide poisoning. *Indian J Pharmacol.* 1992;24:134–137.
13. Hassanian-Moghaddam H, Zamani N, Rahimi M, Hajesmaeili MR, Taherkhani M, Sadeghi R. Successful treatment of aluminium phosphide poisoning by extracorporeal membrane oxygenation. *Basic Clin Pharmacol Toxicol.* 2016;118: 243–246.
14. Mohan B, Singh B, Gupta V, Ralhan S, Gupta D, Puri S, et al. Outcome of patients supported by extracorporeal membrane oxygenation for aluminum phosphide poisoning: an observational study. *Indian Heart J.* 2016;68: 295–301.