

Combined Ethanol, Cocaine, Heroin and Methadone Abuse: a Deadly Mix, Review of the Literature

MARYAM AKHGARI¹, FARZANEH JOKAR¹, LEILA BAHMANABADI¹

¹Forensic Toxicology Department, Legal Medicine Research Center, Legal Medicine Organization, Tehran Iran

Abstract

Background: Polysubstance use or abuse is defined as the ingestion or use of more than one drug of abuse within a defined time frame, aiming to enhance or modulate psychoactive effects, alleviate unwanted side effects of one substance and free access to different kinds of substances. Although deaths involving cocaine and other psychostimulants are increasing in many countries, it is not common in Iran due to the high price of cocaine due to a decrease in the supply chain to Iran.

Case presentation: We report the case of a death due to polysubstance use. Analytical toxicology results were positive for cocaine, cocaethylene, morphine (heroin metabolite), and methadone in combination with positive blood and vitreous humor alcohol contents. The most significant histopathologic features were vascular hypertrophy, chronic myocardial ischemia, moderate to severe atherosclerosis, acute myocardial infarction, hemorrhagic pulmonary edema, *diffuse alveolar collapse*, micro-vesicular steatosis, focal hepatocyte necrosis, *chronic hepatitis*, and *steatohepatitis*.

Discussion: polysubstance users mix drugs to reduce the negative effects of each drug. However, mixing recreational drugs is very dangerous. Pharmacokinetic and pharmacodynamics interactions in polysubstance users can produce health consequences leading to death.

Conclusion: Results of this forensic case study increased attention to overdose mortality due to polydrug use.

Keywords: Cocaine; Ethanol; Cocaethylene; Sudden death; Forensic toxicology

How to cite this article: : Akhgari M, Jokar F, Bahmanabadi L. Combined Ethanol, Cocaine, Heroin and Methadone Abuse: a Deadly Mix, Review of the Literature. *Asia Pac J Med Toxicol* 2020; 9(4):165-169.

INTRODUCTION

Cocaine is one of the psychoactive substances that is used in combination with other drugs. Substance users seek out drug combinations to create a "speedball effect" (1). SAMHSA reported that the number of overdose deaths involving cocaine is increasing in the United States.² Cocaine is a central nervous system (CNS) stimulant drug that affects many systems in the body including cardiovascular, respiratory, central nervous, and renal systems (3). The heart is the most affected organ because of the uncontrolled stimulation of the sympathetic system (4). Although cocaine abuse is not prevalent in Iran due to the high price, studies show that in many other countries, cocaine is a frequently abused substance involved in polydrug abuse (5). There is also evidence that up to 90% of cocaine abusers co-ingest beverages that contain ethanol (6). Polydrug users indicate that cocaine modulates feelings of intoxication and decreases ethanol-induced sedation (7). Both cocaine and ethanol exhibit cardiotoxic effects. Chronic consumption of ethanol leads to progressive cardiomyopathy known as alcoholic heart muscle disease. Cocaine induces cardiovascular abnormalities such as ventricular arrhythmia, ventricular hypertrophy and acute myocardial infarction. Accordingly,

co-abuse of ethanol and cocaine produces a toxicokinetic interaction leading to cocaethylene production, which is a toxicologically active metabolite of cocaine formed only in the presence of ethanol (8). This metabolite crosses the blood-brain barrier (BBB) rapidly and shows similar pharmacologic properties to cocaine (9). Considering their individual cardiotoxic effects, it is suggested that cocaine and ethanol are more toxic in combination in comparison to their single drug use.

Polydrug use including especially heroin, cocaine, and methadone, is a prevalent phenomenon in many countries (10). Cocktails of illicit drugs are produced to get desired effects (11). Methadone maintenance treatment (MMT) is widely used as opioid substitution therapy. Many patients undergoing MMT continue to use illicit drugs such as heroin and cocaine in combination with their daily dose of methadone (12). This case report presents a forensic case of polydrug use that was referred to the forensic toxicology department in Tehran, Iran to be investigated from forensic toxicology and pathology points of view. Previous studies on polydrug users have reported toxicity or death due to two or three drugs. However, this case report describes the use of a cocktail of drugs that included at least four substances. Moreover, histopathologic findings of vital organs were

*Correspondence to: Maryam Akhgari, Department of Forensic Toxicology, Legal Medicine Research Center, Legal Medicine Organization, Old Gom Road, 500 meters after Beheste Zahra, Tehran, Iran. Postal code: 1816153141
Tel/Fax: +982156524763, +989122125864, Email: akhgari1349@yahoo.com

inspected in combination with the toxicological investigation.

CASE REPORT

An Iranian male subject in his early thirties was found dead in his bed with bleeding around his mouth and nose with no visible injuries. According to his relative's declaration, he participated in a party on the night before his death. Although the subject had received Methadone maintenance treatment (MMT) for two months for heroin cessation, he continued to use heroin in combination with methadone. The daily dose of heroin inhaled by the subject reached about 0.5 g/day and he was also receiving 10 mg/day of methadone syrup. At the scene of death, police found an empty bottle of methadone 25 mg/5 mL beside his bed. The deceased was subsequently transferred to the Department of Forensic Medicine at the Legal Medicine Organization in Tehran for an autopsy to determine the cause of death. Height was 180 cm weight was 114 kg. There were no wounds or injuries. Multiple self-immolation scars were seen on the hands and arms. Sulcus and gyrus of the brain were edematous. Hemorrhage was not observed in the brain parenchyma, stem, and cerebellum. The heart weighed 450 g, and there was thickening of the cardiac walls and moderate to severe atherosclerosis in the left anterior descending artery. Myocardial muscle was reddish and petechial hemorrhages in the myocardium were seen. Pulmonary edema and conjunctival hyperemia were noted. The liver weighed 1600 g, was coarsely granular and showed

typical advanced fatty liver.

Urine, liver, stomach contents and bile samples were prepared using liquid-liquid extraction and dispersive liquid-liquid microextraction (DLLME) prior to analysis. Sample preparation steps were taken using prevalidated methods for systematic toxicological analysis of postmortem specimens (13). Qualitative analyses of postmortem samples were carried out for the detection of alcohol, licit and illicit drugs using gas chromatography/mass spectrometry (GC/MS), headspace gas chromatography/mass spectrometry (HSGC/MS) and headspace gas chromatography (HSGC) (13). Forensic toxicology analysis results are shown in Table 1. Chromatograms and mass spectra of detected analytes are shown in Figures 1-3.

Histologic examination was performed on cardiac, pulmonary and hepatic tissues. Pre-established macroscopic and histological criteria were used for the diagnosis of pathologic features. All tissues were formalin fixed. In order to be stained by hematoxylin and eosin, after fixation, samples were dehydrated in alcohol series and embedded in paraffin wax. All prepared samples were examined under light microscopy for histopathological study based on Kiernan protocol (14). Two pathologists reviewed slides blindly. Any gross and microscopic features of tissues were considered and histologic changes for the case were recorded. The histopathological assessment of heart included the inspection of ventricles, pericardium, endocardium, and coronary arteries. The gross examination of the heart showed a pattern of dilated cardiomyopathy. Cardiovascular pathology was noted in the case. Common histopathologic features were left ventricular hypertrophy, chronic myocardial ischemia, moderate to severe atherosclerosis, acute myocardial infarction, hemorrhagic pulmonary edema, *diffuse alveolar collapse*, micro-vesicular steatosis, focal hepatocyte necrosis, *chronic hepatitis and steatohepatitis*.

Table 1. Drugs and substances detected in postmortem samples of a poly drug abuser

Biological matrix	Forensic toxicology analysis result
Blood	Ethanol: 23 mg/dL
Vitreous humor	Ethanol: 25 mg/dL
Urine	Morphine, Methadone, Cocaine, Cocaethylene
Stomach content	Methadone, Cocaine
Liver	Methadone, Morphine, Cocaine

DISCUSSION

Polysubstance use is a common occurrence among substance abusers and often includes cocaine (15). Side effects of mixing drugs with each other can be severe (16).

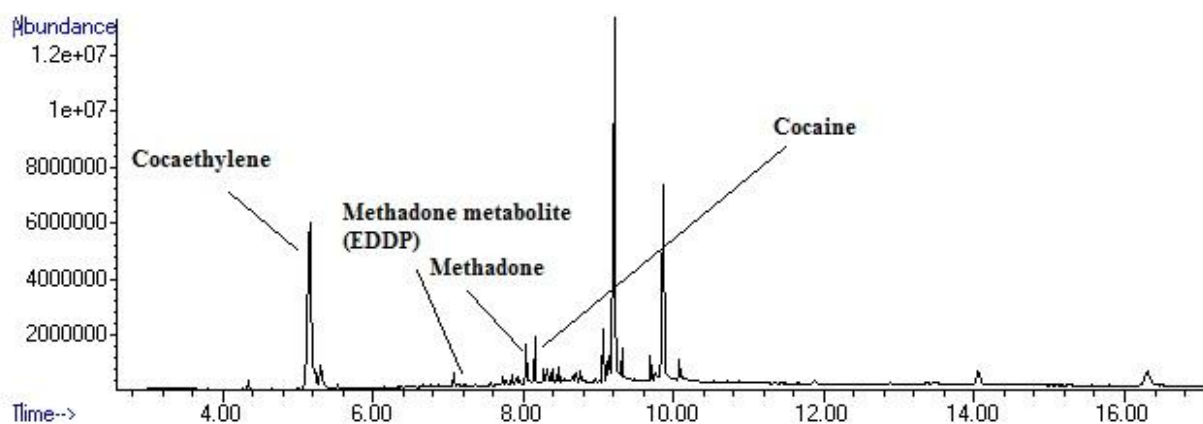


Figure 1. Chromatogram cocaine, cocaethylene, methadone and methadone metabolite (EDDP) detected in postmortem samples of a poly drug abuser case.

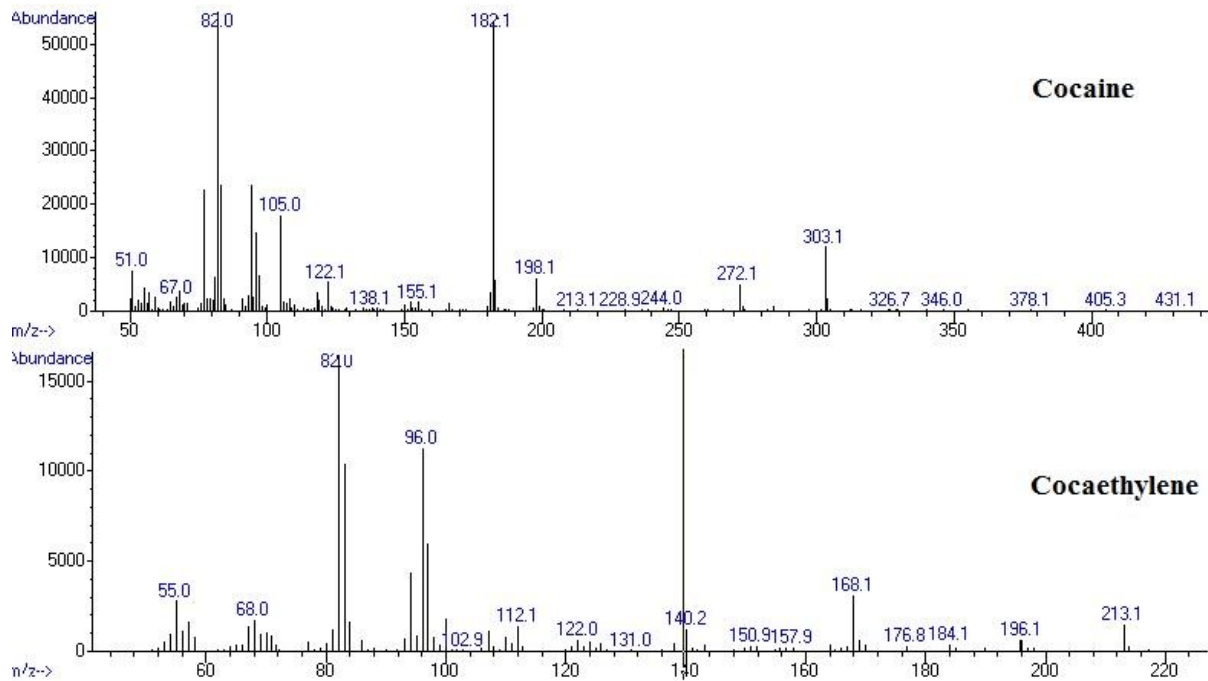


Figure 2. Mass spectra of cocaine and cocaethylene detected in postmortem samples of a poly drug abuser case.

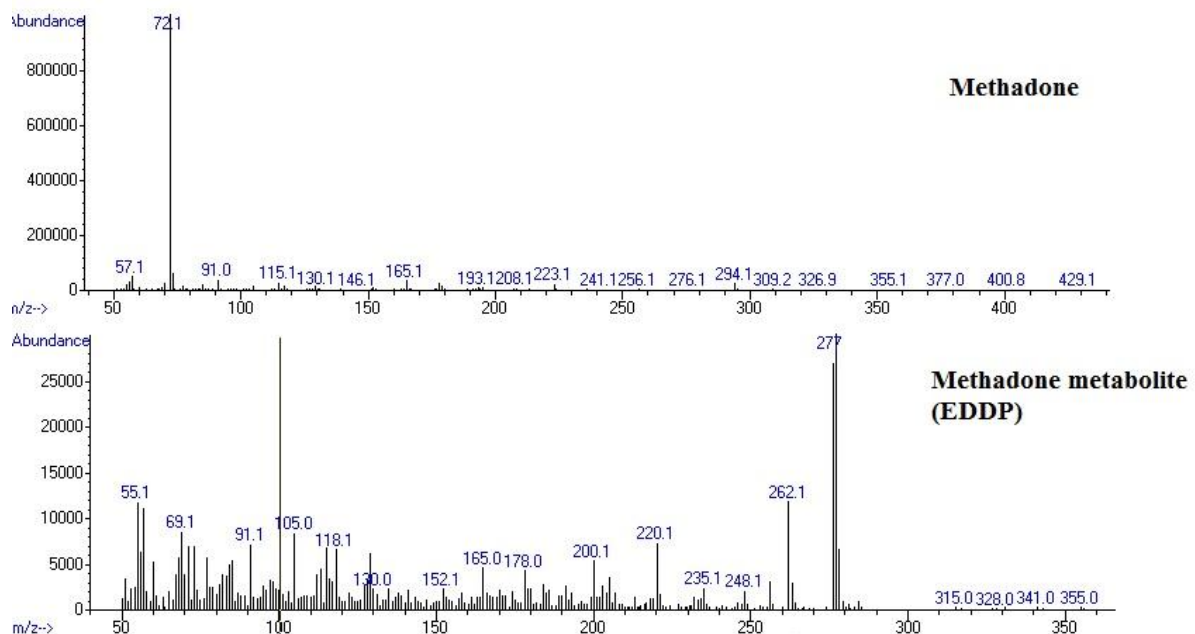


Figure 3. Mass spectra of methadone and methadone metabolite (EDDP) detected in postmortem samples of a poly drug abuser case.

Cocaine exerts its psychostimulant activity via the inhibition of presynaptic reuptake of noradrenaline, dopamine and serotonin in the mesocorticolimbic "reward" system.⁹ Cocaine is metabolized to benzoylecgonine and ecgonine methyl ester (17). In the presented case, detection of ethanol, cocaine and cocaethylene in postmortem samples indicated that cocaine and ethanol were used simultaneously.

Cocaethylene has a pharmacologic action comparable to cocaine (18). In general, alcohol is often co-abused with psychostimulants such as cocaine and amphetamine type stimulants, opioids like heroin, and cannabis derivatives (16). Heroin was one of the substances used in the presented case. Previous studies suggest that alcohol increases the risk of heroin-related deaths due to pharmacodynamics interactions

(19). In addition to well-known pharmacodynamics interactions between heroin and ethanol, which lead to respiratory depression and death, a previous study by Thaulow and colleagues showed that heroin has pharmacokinetic interactions with ethanol as well. Heroin converts to 6-monoacetyl morphine (6-MAM) and then morphine in the metabolism pathway. The last metabolite conjugates to glucuronic acid to form morphine-3 glucuronide (M-3 G) and morphine-6 glucuronide (M-6G). Ethanol inhibits the conversion of 6-MAM to morphine and also inhibits the final step to produce M-3 G and M-6 G. Previous studies also supported that heroin and synthetic opioids increase the risk of stimulant-involved deaths (20, 21).

Continued use of illicit drugs during methadone maintenance treatment (MMT) represents a problem and perhaps a failure of MMT. In a three-year study (1996-1998) that was conducted in Switzerland, it was concluded that continued drug abuse by study cases occurred before and during MMT program. Most of the patients had used heroin, cocaine and alcohol simultaneously. The authors stated that becoming chronic alcohol users was more probable in cocaine abusers (12).

In the present case, heart weight was 450 g (standard range for Iranian male population; 359.9 ± 76.6 g) (22) and the left ventricle wall was thick. Cardiac complications were noted. Cocaine induced arrhythmia, vasoconstriction, platelet aggregation and acceleration of atherosclerosis have been shown to be potential contributors to cardiac complications (23). Severe cardiotoxic effects of cocaine may be correlated with its short half-life in the body. Its brief effect encourages substance abusers to use multiple doses in a short period of time to enhance the feeling of euphoria. When multiple doses are taken, the heart rate increases significantly. Metabolic detoxification of cocaine is altered in the presence of alcohol and cocaethylene is produced. Takayama et al. reported that cocaine-related sudden death was due to subarachnoid hemorrhage (17).

It is also well known that alcohol is a hepatotoxic agent. Alcohol is likely to increase liver damage when it is used in combination with cocaine due to alcohol-mediated increased activity of cytochrome P-450 and production of hepatotoxic agents such as norcocaine hydrochloride (24). Toxic hepatic manifestations in the present case may be related to the production of norcocaine in the body. Norcocaine is an oxidative metabolite with pharmacologically active properties. Further metabolism of norcocaine converts it to norcocaine nitroxide that exerts hepatotoxic effects in animal models. Combined use of cocaine and alcohol may mediate liver damage due to alcohol mediated activity of cytochrome P-450 (23). Laslo et al. in their review article stated that alveolar hemorrhage has been frequently shown in cocaine abusers. The case in the present study had used heroin. One of the complications in the pulmonary system was pulmonary edema. In line with the results of the present case report Laslo et al. indicated that non-cardiogenic pulmonary edema was categorized as a common manifestation associated with heroin use (24).

CONCLUSION

Concluding results from the study of this case sustain

ethanol and other drugs of abuse-elicited additive exacerbation, its consequences in cocaine-induced cardiac toxicity and the role of poly drug use in inducing death.

REFERENCES

1. LaRue L, Twillman RK, Dawson E, Whitley P, Frasco MA, Huskey A, et al. Rate of Fentanyl Positivity Among Urine Drug Test Results Positive for Cocaine or Methamphetamine. *JAMA Netw Open* 2019; 2(4):e192851.
2. Substance Abuse and Mental Health Services Administration, 2013. Drug Abuse Warning Network 2011: National Estimates of Drug-related Emergency Department Visits. From: <http://www.samhsa.gov/data/sites/default/files/DAWN2k11E/DAWN2k11ED/DAWN2k11ED.htm>. Accessed May 2020.
3. Han BH, Tuazon E, Kunins HV, Mantha S, Paone D. Unintentional drug overdose deaths involving cocaine among middle-aged and older adults in New York City. *Drug Alcohol Depend* 2019; 198:121-5.
4. De Rubeis G, Catapano F, Cundari G, Ascione A, Galea N, Catalano C, et al. Cocaine Abuse: An Attack to the Cardiovascular System—Insights from Cardiovascular MRI. *Radiol: Cardiothorac Imaging* 2019; 1(2):e180031.
5. Miró Ò, Dargan PI, Wood DM, Dines AM, Yates C, Heyerdahl F, et al. Epidemiology, clinical features and management of patients presenting to European emergency departments with acute cocaine toxicity: comparison between powder cocaine and crack cocaine cases. *Clin Toxicol (Phila)* 2019; 57(8):718-26.
6. Althobaiti YS, Sari Y. Alcohol Interactions with Psychostimulants: An Overview of Animal and Human Studies. *J Addict Res Ther* 2016; 7(3):281.
7. Martins MJ, Roque Bravo R, Enea M, Carmo H, Carvalho F, Bastos ML, et al. Ethanol additively enhances the in vitro cardiotoxicity of cocaine through oxidative damage, energetic deregulation, and apoptosis. *Arch Toxicol* 2018; 92(7):2311-25.
8. Dinis-Oliveira RJ. Metabolomics of cocaine: implications in toxicity. *Toxicol Mech Methods* 2015; 25(6):494-500.
9. Büttner A, Mall G, Penning R, Sachs H, Weis S. The neuropathology of cocaine abuse. *Leg Med (Tokyo)* 2003; 5 Suppl 1:S240-S242.
10. Lorvick J, Browne EN, Lambdin BH, Comfort M. Polydrug use patterns, risk behavior and unmet healthcare need in a community-based sample of women who use cocaine, heroin or methamphetamine. *Addict Behav* 2018; 85:94-9.
11. Akhgari M, Jokar F, Etemadi-Aleagha A. Street Level Heroin, An Overview on Its Components and Adulterants. In: Preedy VR, editor. *Neuropathology of Drug Addictions and Substance Misuse. Volume 1: Foundations of Understanding, Tobacco, Alcohol, Cannabinoids and Opioids*. Amsterdam, Netherlands: Elsevier; 2016; p. 867-77.
12. Dobler-Mikola A, Hättenschwiler J, Meili D, Beck T, Böni E, Modestin J. Patterns of heroin, cocaine, and alcohol abuse during long-term methadone maintenance treatment. *J Subst Abuse Treat* 2005; 29(4):259-65.
13. Kordrostami R, Akhgari M, Ameri M, Ghadipasha M, Aghakhani K. Forensic toxicology analysis of self-poisoning suicidal deaths in Tehran, Iran; trends between 2011-2015. *Daru* 2017; 25(1):15.
14. Kiernan JA. *Histological and histochemical methods: theory and practice*, third ed., Oxford, Butterworth-Heinemann, 1999.
15. Liu Y, Williamson V, Setlow B, Cottler LB, Knackstedt LA. The importance of considering polysubstance use: lessons from cocaine research. *Drug Alcohol Depend* 2018; 192:16-28.
16. Singh AK. Alcohol Interaction with Cocaine, Methamphetamine, Opioids, Nicotine, Cannabis, and γ -

Archive of SID

- Hydroxybutyric Acid. *Biomedicines* 2019; 7(1):16.
17. Takayama M, Waters B, Fujii H, Hara K, Kashiwagi M, Matsusue A, et al. Subarachnoid hemorrhage in a Japanese cocaine abuser: Cocaine-related sudden death. *Leg Med (Tokyo)* 2018; 32:43-7.
 18. de Castro-Neto AG, Rameh-de-Albuquerque RC, de Medeiros PF, Uchôa R. Neuroscience of Alcohol and Crack Cocaine Use: Metabolism, Effects and Symptomatology, In: Preedy VR, editor. *Neuroscience of Alcohol, Mechanisms and Treatment*. London: Academic Press; 2019. p. 537-44.
 19. Moore N, Pollack C, Butkerait P. Adverse drug reactions and drug-drug interactions with over-the-counter NSAIDs. *Ther Clin Risk Manag* 2015; 11:1061-75.
 20. Thaulow CH, Høiseith G, Andersen JM, Handal M, Mørland J. Pharmacokinetic interactions between ethanol and heroin: a study on post-mortem cases. *Forensic Sci Int* 2014; 242:127-34.
 21. Kariisa M, Scholl L, Wilson N, Seth P, Hoots B. Drug Overdose Deaths Involving Cocaine and Psychostimulants with Abuse Potential - United States, 2003-2017. *MMWR Morb Mortal Wkly Rep* 2019; 68(17):388-95.
 22. Sheikhezadi A, Sadr SS, Ghadyani MH, Taheri SK, Manouchehri AA, Nazparvar B, et al. Study of the normal internal organ weights in Tehran's population. *J Forensic Leg Med* 2010; 17(2):78-83.
 23. Shimomura ET, Jackson GF, Paul BD. Cocaine, Crack Cocaine, and Ethanol: A Deadly Mix, In: Dasgupta A, editor. *Critical Issues in Alcohol and Drugs of Abuse Testing*. Houston: Academic Press; 2019. p. 215-24.
 24. Laslo C, Ioan BG, Bratu OG, Socea B, Diaconu C. THE LUNG EFFECTS OF ILLICIT DRUGS. *Arch Balk Med Union* 2018;53:96-99.