

---

(*Cyprinus carpio*)

( ) \*

( / / : / / )

*Cyprinus carpio*

δ

( $p < /$  )

( $p < /$  )

( $p > /$  )

(*Cyprinus carpio*) :

(Vale, 1998 )

( )

Benarji, and Rajendranath, 1990; Soldatov, )

(2005

(Watterson, 1999 )

(Triebkorn *et al.*, 2000)

(Coppage and Mathews, 1974 )

Dutta and Arends, 2003; Banaee *et* )

Khoshbavar ) (*al.*, 2009a, b, c

Rostami *et al.*, 2006; Soltani and Pourgholam,

(Üner *et al.*, 2006) (2007

(Pourgholam, *et al.*, 2006; Banaee *et al.*, 2008)

Pourgholam, *et al.*, 2001; )

Sharifpour *et al.*, ) (2006

(2006

(Nouri *et al.*, 2000; Tavakol, 2007)

(Honarpajouh, 2003)

(Tarahi Tabrizi, 2001)

(Shayeghi *et al.*, 2007)

(Shayeghi *et al.*, 2007)

Arjomandi *et al.*, ) (Bagheri, 2007)

Shayeghi ) (2010

(*et al.*, 2007; Arjomandi *et al.*, 2010

(USEPA, 2005)

Archive of SID

( ± / g)

(CHO-PAP)

NAD<sup>+</sup> NADPH ( mg/l ± °C)

%

OD OECD

µg/L

/

/ mg/l LC<sub>50</sub>

- (Banaee *et al.*, 2008) ( /

Ganji and ) ( )

(Arvand, 2002

( ) )

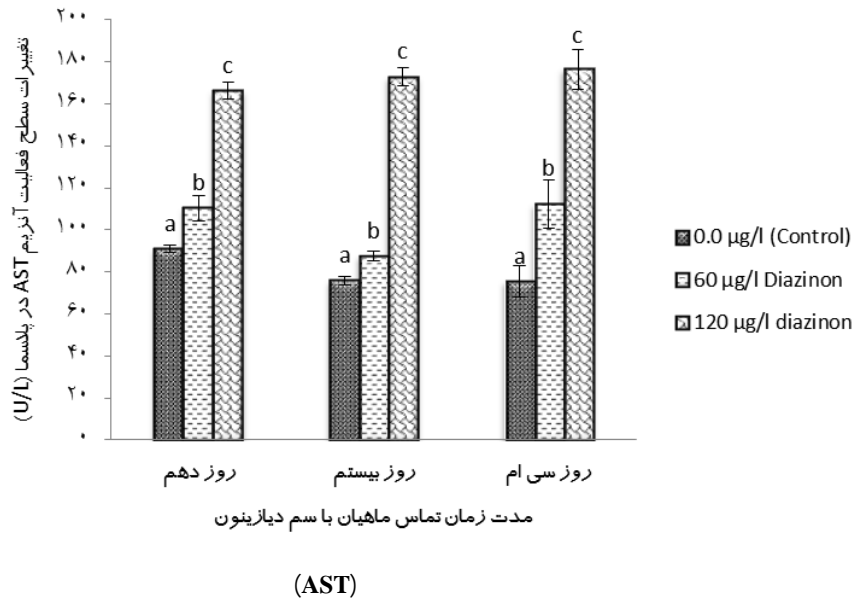
(

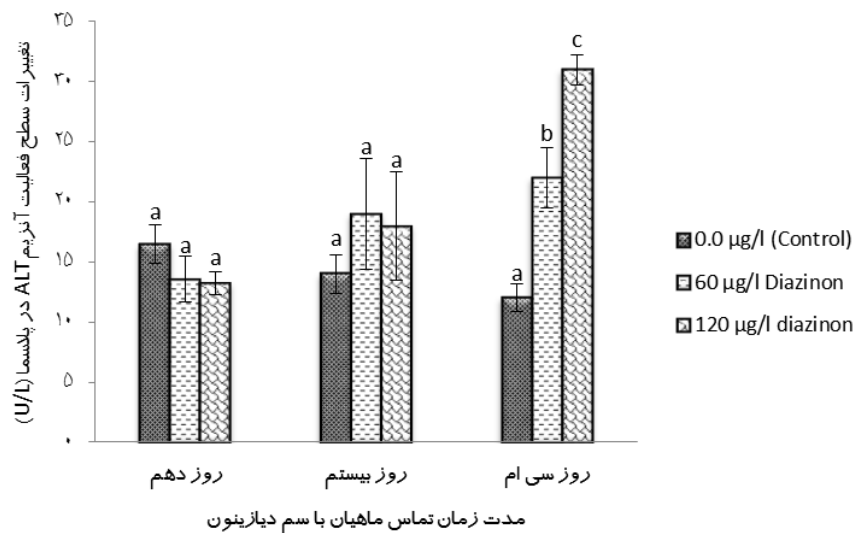
μg/L  
( )  
Mintab 13 (ANOVA)  
Kolmogorov-Smirnov Normality Test

AST (α = / ) %  
( ) (p < / )

ALT (p < / )

Journal of SID





(ALT)

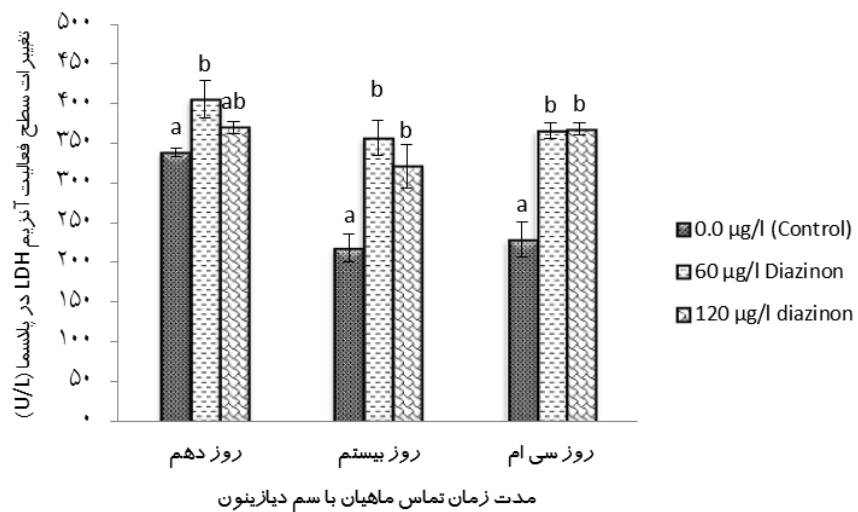
CK

( $p < /$ )

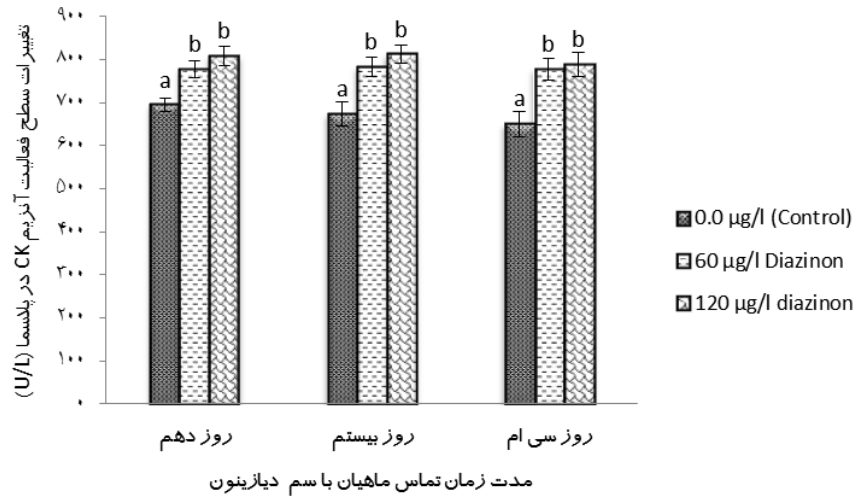
. ( )

LDH

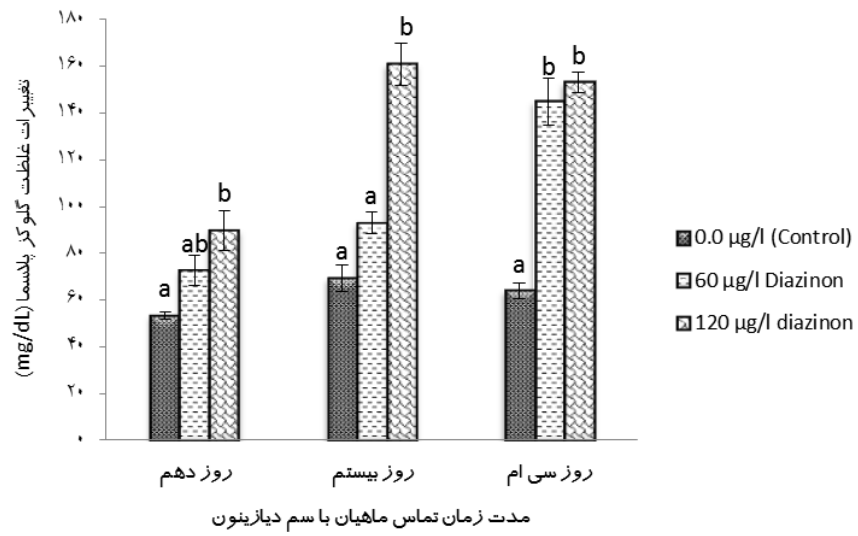
( $p < /$ )



(LDH)



(CK)



( $p < /$  )

. ( )

( $p < /$  )

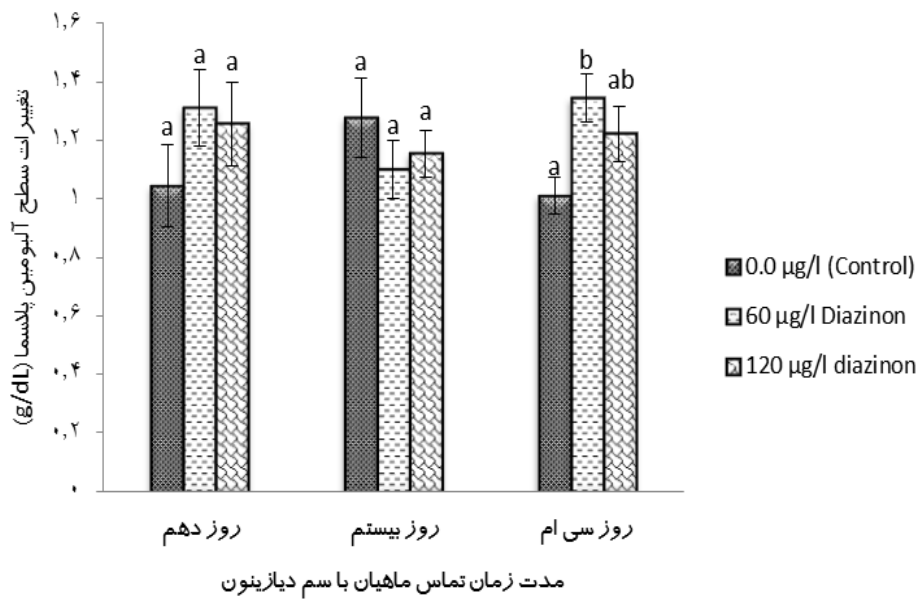
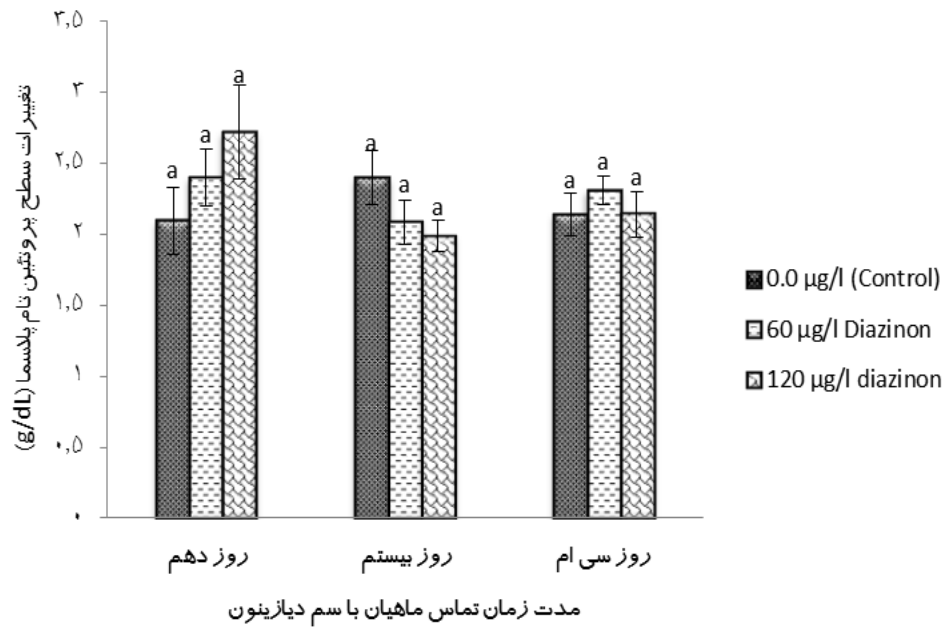
. ( )

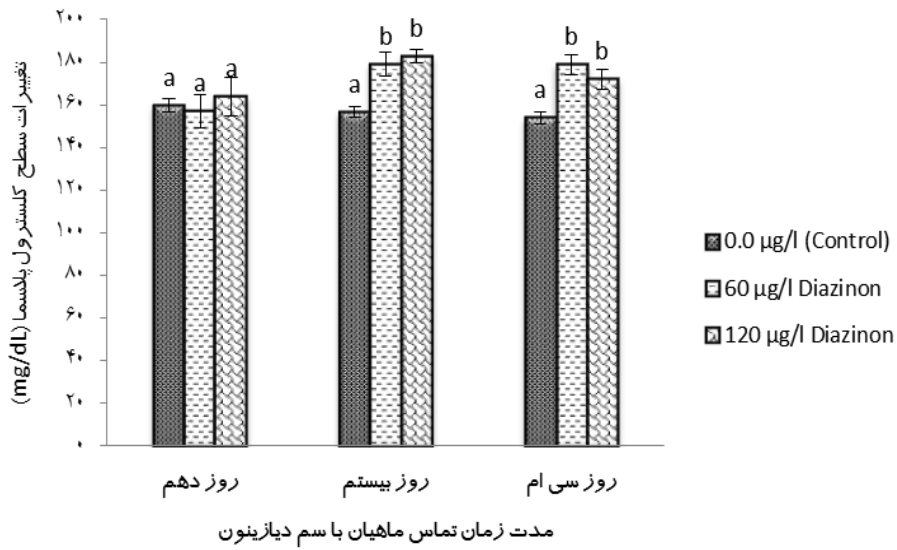
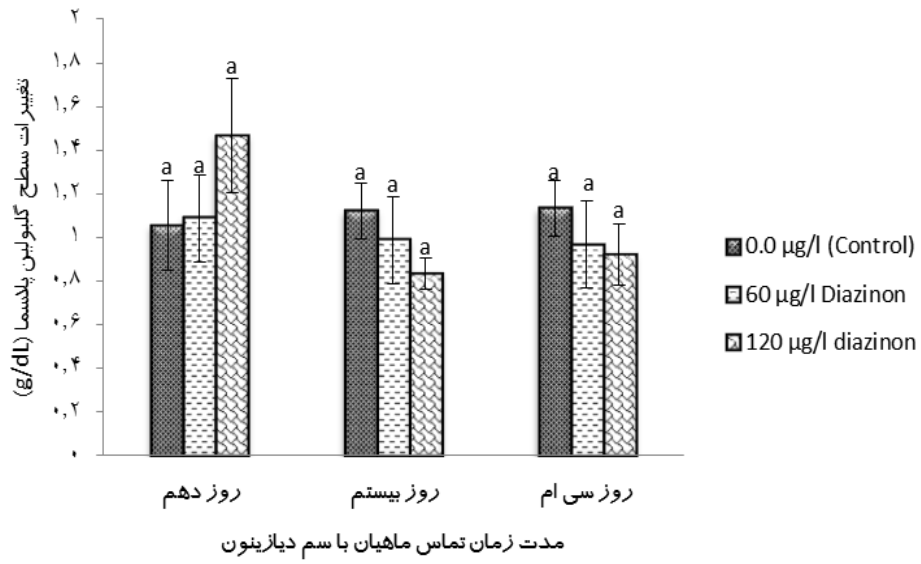
( $p < /$  )

. ( )

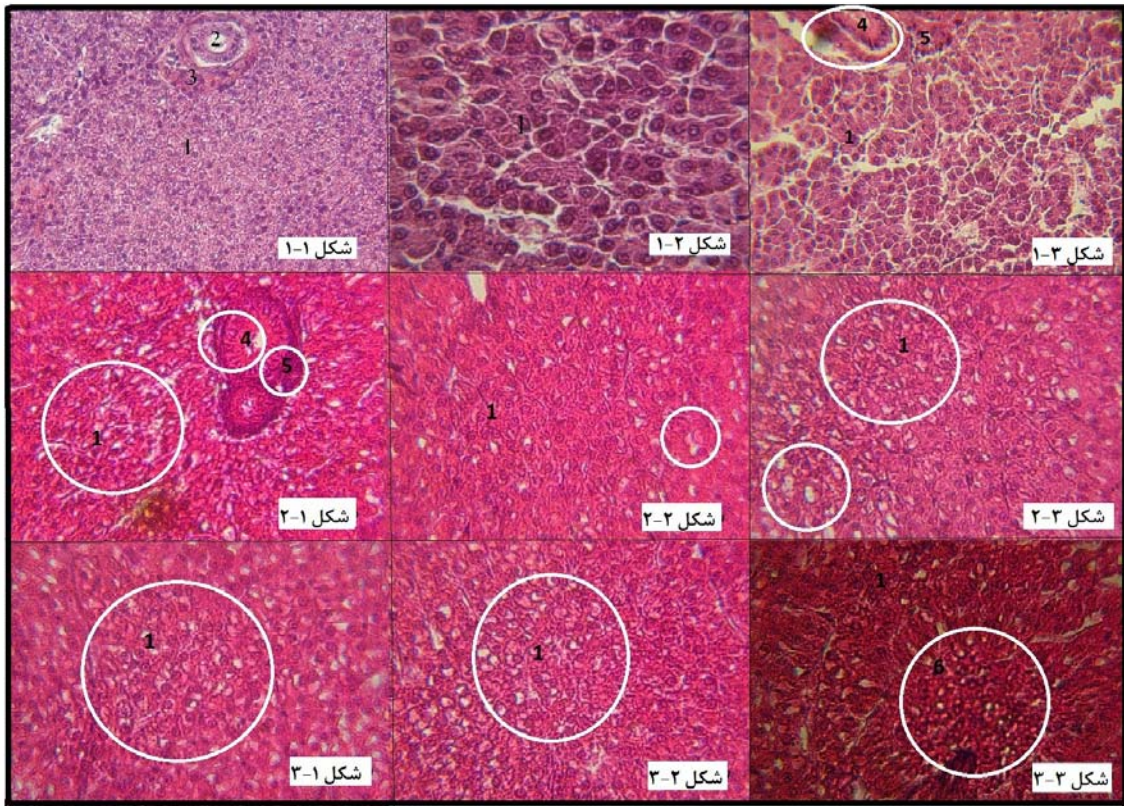
. ( )

. ( )









( ) ( ) ( ) x ( ) :  
 (2) (1)  $\mu\text{g/L}$  ( )  $\mu\text{g/L}$   
 (6) (5) (4) (3)

$\mu\text{g/L}$

$\mu\text{g/L}$ )

(

$\mu\text{g/L}$

...

- ( $p < 0.05$ )

(Hodgson, 2004)

(Vale, 1998)

- ( $p < /$  )

Banaee, )

(2012

P<sub>450</sub>

.(de Aguiar *et al.*, 2004)

- (Keizer *et al.*, 1995)

(ROS)

Saha and Kaviraj, ) *Heteropneustes fossilis*

Das and ) *Labeo rohita* (2009

(Mukherjee, 2003

*Oncorhynchus mykiss*

(*Oncorhynchus mykiss*)

(Velisek *et al.*, 2006)

(Banaee *et al.*, 2011)

.(Isik and Celik, 2008)

.(Jon, 2007)

---

<sup>1</sup> Diazoxon  
<sup>2</sup> Pyrimidinol

Zaragoza *et al.*, )  
 .(2000

Velisek )  
 LDH (et al., 2006) .(1998

(CK) (Roy and Bhattacharya, 2006)  
 (Grzyb and Skorkowski, 2005) (AST)  
 Gongga *et al.*, ) (Haagensen *et al.*, 2008) Srivastava *et.*) (ALT)  
 (Dickmeis *et al.*, 2001) (2004) Petrović *et al.*,) (al., 2004  
 CK (Bhattacharya *et al.*, 2008) (1996

-(Ozawa *et al.*, 1999)

AST (Velisek *et al.*, 2008)  
 LDH CK ALT Banacee,) AST ALT LDH .(2006  
 (Svoboda, 2001)

ALT AST

Srivastava *et al.*, )  
 ALT AST .(2004; Rao, 2006  
*Channa punctatus*

.(Agrahari *et al.*, 2007)

<sup>1</sup> Bifenthrin

## References

- Agrahari, S., Pandey, K.C., Gopal, K., 2007. Biochemical alteration induced by monocrotophos in the blood plasma of fish, *Channa punctatus* (Bloch). *Pesticide Biochemistry and Physiology* 88, 268-272.
- Ahmad, A., Pillai, K. K., Najmi, A. K., Pal, S.N., 2002. Evaluation of hepatoprotective potential of jigrine post-treatment against thioacetamide induced hepatic damage. *Journal Ethnopharmacology* 79, 35-41.
- Arjmandi, R., Tavakol, M., Shayeghi, M., 2010. Determination of organophosphorus insecticide residues in the rice paddies. *International Journal Environmental Science Technology* 7 (1), 175-182.
- Bagheri, F., 2007. Study of pesticide residues (Diazinon, Azinphosmethyl) in the rivers of Golestan province (GorganRoud and Gharehsou), M.Sc. Thesis, Tehran University of Medical Science. Tehran, Iran. (In Persian)
- Banaee, M., 2006. Sub-lethal toxicity effects of diazinon on hematology and biochemical parameters and histology of kidney and spleen in common carp (*Cyprinus carpio*). M.Sc. Thesis, Tehran University, Natural Resource Faculty, Fishery and Environmental Department. Tehran, Iran. (In Persian)
- Banaee, M., 2012. Adverse effect of insecticides on various aspects of fish's biology and physiology: Insecticides – Basic and Other Applications Book, Edited by Sonia Soloneski and Marcelo Larramendy, Published by InTech, Chapter 6: 101-126.
- Banaee, M., Mirvaghefi, A.R., Ahmadi K., Banaee, S., 2008. Acute toxic effects of diazinon on hematology and biochemical parameters in common carp (*Cyprinus carpio*). *Journal of Marine Science and Technology* 3(2), 1-10. (In Persian)
- Banaee, M., Mirvaghefi, A. R., Ahmadi, K., Ashori, R., 2009a. The effect of diazinon on histopathological changes of testis of immature male common carp (*Cyprinus carpio*). Abstract Proceeding of 1<sup>st</sup> Congress Wetland of Iran. Islamic Azad Ahvaz University. March 2009. p.69. (In Persian)
- Banaee, M., Mirvaghefi, A. R., Ahmadi, K., Rafei, G. R., Ashori, R., 2009c. Acute toxic effects of diazinon on blood biochemical indices of rainbow fish Rainbow trout (*Oncorhynchus mykiss*). Abstract Proceeding of National Conference of Coldwater Fish, Tonekabon. May 2009. p.202. (In Persian)
- Banaee, M., Mirvaghefi, A. R., Ahmadi, K., Rafei, G. R., Bagheri, D., 2009b. Study adverse effects of acute toxicity of diazinon on histopathology and blood parameters of rainbow trout (*Oncorhynchus mykiss*). Abstract Proceeding of National Conference of Coldwater Fish, Tonekabon. May 2009. p. 201. (In Persian)
- Banaee, M., Sureda, A., Mirvaghefi, A. R., Ahmadi, K., 2011. Effects of diazinon on biochemical parameters of blood in rainbow trout (*Oncorhynchus mykiss*). *Pesticide Biochemistry and Physiology* 99, 1–6.
- Soltani, M., Pourgholam, R., 2007. Lysozyme activity of grass carp (*Ctenopharyngodon idella*) after exposure to sub-lethal concentrations of organophosphate, diazinon. *Journal of veterinary Research* 62(2), 50-52.
- Benarjee, G., Rajendranath, T., 1990. Hematological changes induced by an organophosphorous insecticide in a freshwater fish *Clarias batrachus* (Linnaeus), *Tropical Freshwater Biology* 2, 197–202.
- Bhattacharya, H., Xiao, Q., Lun, L., 2008. Toxicity studies of nonylphenol on rosy barb (*Puntius conchonioides*): A biochemical and histopathological evaluation. *Tissue and Cell* 40, 243-249.
- Copping, D.C., Matthews, E., 1974. Short term effects of organophosphate pesticide on cholinesterases of estuarine fishes and pink shrimp. *Bulletin of Environmental Contamination and Toxicology* 32, 483–488.
- Das, B.K., Mukherjee, S.C., 2003. Toxicity of cypermethrin in *Labeo rohita* fingerlings: biochemical, enzymatic and haematological consequences. *Comparative Biochemistry and Physiology Part C: Toxicology and Pharmacology* 134, 109-121.
- de Aguiar, L.H., Moraes, G., Avilez, I.M., Altran, A.E., Correa, C.F., 2004. Metabolical effects of folidol 600 on the neotropical freshwater fish matrinxã, *Brycon cephalus*. *Environmental Research* 95, 224–230.

- 
- Dickmeis, T., Rastegar, S., Aanstad, P., Clark, M., Fischer, N., Plessy, C., Rosa, F., Vladimir Korzh, V., Strähle, U., 2001. Expression of brain subtype creatine kinase in the zebrafish embryo. *Mechanisms of Development* 109, 409-412.
- Dutta, H. M., Arends, D., 2003. Effects of endosulfan on brain acetylcholinesterase activity in juvenile bluegill sunfish. *Environmental Research* 91, 157-162.
- Ganji, F. K., Arvand, M., 2002. *Histology practical*. University of Medical Sciences and Health Services Mashhad. ISBN 7 - 08 - 5627 - 964, p 15-19.
- Gongga, H.Y., Wua, J.L., Huanga, W.T., Lina, C.J.F., Weng, C.F., 2004. Response to acute changes in salinity of two different muscle type creatine kinase isoforms, from euryhaline teleost (*Oreochromis mossambicus*) gills. *Biochimica et Biophysica Acta (BBA) Genral Subjects* 1675, 184- 191.
- Grzyb, K., Skorkowski, E.F., 2005. Characterization of creatine kinase isoforms in herring (*Clupea harengus*) skeletal muscle. *Comparative Biochemistry and Physiology Part B: Biochemistry and Molecular Biology* 10, 629-634.
- Haagensen, L., Jensen, D.H., Gesser, H., 2008. Dependence of myosin-ATPase on structure bound creatine kinase in cardiac myofibrils from rainbow trout and freshwater turtle. *Comparative Biochemistry and Physiology Part A* 150, 404-409.
- Hodgson, E., 2004. *A textbook of modern toxicology (3<sup>rd</sup> Ed.)*, A Join Wiley & Sons, INC., Publication, 582 pages.
- Honarpajouh, K., 2003. Study and Identification of OP pesticides residues (Azinphosmethyl and Diazinon) in the Mahabad and Siminerood Rivers, M.Sc. Thesis, Tehran University of Medical Science. Tehran, Iran. (In Persian)
- Isik, I., Celik, I., 2008. Acute effects of methyl parathion and diazinon as inducers for oxidative stress on certain biomarkers in various tissues of rainbowtrout (*Oncorhynchus mykiss*). *Pesticide Biochemistry and Physiology* 92, 38-42.
- John, P.J., 2007. Alteration of certain blood parameters of freshwater teleost *Mystus vittatus* after chronic exposure to Metasystox and Sevin. *Fish Physiology Biochemistry* 33, 15-20.
- Keizer, J., D'Agostino, G., Nagel, R., Volpe, T., Gnemid, P., Vitozzi, L., 1995. Enzymological differences of AChE and diazinon hepatic metabolism: correlation of in vitro data with the selective toxicity of diazinon to fish species. *The Science of the Total Environment* 171, 213-220.
- Khoshbavar-Rostami, H. A., Soltani, M., Hassan, H.M.D., 2006. Immune response of great sturgeon (*Huso huso*) subjected to long-term exposure to sublethal concentration of the organophosphate, diazinon. *Aquaculture* 256, 88-94.
- Nouri, J., Arjmandi, R., Bayat, H., 2000. Ecological investigation of application of pesticides in rice fields. *Iran Journal Public Health* 29 (1-4), 137-146.
- Ozawa, E., Hagiwara Y., Yoshida, M., 1999. Creatine kinase, cell membrane and Duchenne muscular dystrophy. *Molecular and Cellular Biochemistry* 190, 143-151.
- Petrović, S., Ozretić, B., Krajinović-Oaretić, M., 1996. Cytosolic Aspartate Aminotransferase from grey mullet (*Mugil auratus* Risso) Red Muscle: Isolation and Properties. *International Journal Biochemchemistry Cell Biology* 28(8), 873-881.
- Pourgholam, R., Soltani, M., Hassan, M.D., Esmaeili, F., Farhoumand, H., Yousefi, P., 2001. Evaluation of blood characteristics of grass carp (*Ctenopharyngodon idella*) after exposure to organophosphate, diazinon. *Iranian Journal of Fisheries sciences* 3(2), 1-18.
- Pourgholam, R., Soltani, M., Hassan, M.D., Ghoroghi, A., Nahavandi, R., Pourgholam, H., 2006. Determination of diazinon LC<sub>50</sub> in grass carp (*Ctenopharyngodon idella*) and the effect of sub-lethal concentration of toxin on some hematological and biochemical indices. *Iranian Journal of Fisheries sciences* 5(2), 67-82.
- Rao, J.V., 2006. Toxic effects of novel organophosphorus insecticide (RPR-V) on certain biochemical parameters of euryhaline fish, *Oreochromis mossambicus*. *Pesticide Biochemistry and Physiology* 86, 78-84.
- Roy, S., Bhattacharya S., 2006. Arsenic-induced histopathology and synthesis of stress proteins in liver and kidney of *Channa punctatus*. *Ecotoxicology and Environmental Safety* 65, 218-229.
- Saha, S., Kaviraj, A., 2009. Effects of cypermethrin on some biochemical parameters and its amelioration through dietary supplementation of ascorbic acid in freshwater catfish *Heteropneustes fossilis*. *Chemosphere* 74, 1254-1259.

- ...
- 
- Sanz, N., Fernandez, C. D., Simon, L. F., Alvarez, A., Cascales, M., 1998. Necrogenic and regenerative responses of liver newly weaned rats against a sublethal dose of thioacetamide. *Biochemica et Biophysica Acta* 1384, 66-78.
- Sharifpour, I., Pourgholam, R., Soltani, M., Hassan, M. D., Akbari, S., Nouri, A. 2006. Light and electron microscope studies of grass carp (*Ctenopharyngodon idella*) organs following exposure to various sub-lethal doses of diazinon. *Iranian Journal of Fisheries sciences* 5(2), 111-136.
- Shayeghi M., Darabi, H., Abtahi, H., Sadeghi, M., Pakbaz, F., Golestaneh, S. R., 2007. Assessment of Persistence and Residue of Diazinon and Malathion in Three Rivers (Mond, Shahpour and Dalaky) of Bushehr Province; 2004-2005. *Iranian South Medical Journals* 10(1), 54-60. (In Persian)
- Soldatov, A. A., 2005. Peculiarities of organization and functioning of the fish red blood system. *Journal of Evolutionary Biochemistry and Physiology* 41(3), 272-281.
- Srivastava, A. S., Oohara, I., Suzuki, T., Shenouda, S., Singh, S. N., Chauhan, D.P., Carrier, E., 2004. Purification and properties of cytosolic alanine aminotransferase from the liver of two freshwater fish, *Clarias batrachus* and *Labeo rohita*. *Comparative Biochemistry and Physiology Part B: Biochemistry and Molecular Biology* 137, 197-207.
- Status Report of Ministry of Agriculture (1379-80). Deputy of Planning and Budget, Department of Statistics and Information of ministry of agriculture (1381).
- Svoboda, M., 2001. Stress in fish-review. *Bull RIFCH Vodnany* 37, 169-191.
- Tarahi Tabrizi, S., 2001. Study of pesticide residues (diazinon, malathion, metasytoux) in the Tabriz Nahand River. M.Sc. Thesis, Tehran University of Medical Science, Tehran, Iran. (In Persian)
- Tavakol, M., 2007. Environmental impact assessment of diazinon in rice fields (a Case Study on Amol Township Rice Fields), M.Sc. Thesis, Science and Research Branch, Islamic Azad University, Tehran, Iran. (In Persian)
- Triebkorn, R., Adam, S., Casper, H., Honnen, W., Müller, E. F., Pawert, M., Schramm, M., Schwaiger J., Köhler, H.R., 2002. Biomarkers as diagnostic tools for evaluating toxicological effects of unknown past water quality conditions on stream organisms. *Ecotoxicology* 11(6), 451-65.
- U.S. EPA., 2005. Aquatic life ambient water quality criteria Diazinon Final. Office of Science and Technology Washington, DC. (CAS Registry Number 333-41-5): 1-85.
- Üner, N., Oruç, E. Ö., Sevgiler, Y., Şahin, N., Durmaz, H., Usta, D., 2006. Effects of diazinon on acetylcholinesterase activity and lipid peroxidation in the brain of *Oreochromis niloticus*. *Environmental Toxicology and Pharmacology* 21, 241-245.
- Vale, J. A., 1998. Toxicokinetic and toxicodynamic aspects of organophosphorus OP insecticide poisoning. *Toxicology Letters* 64(9), 102-103.
- Velisek, J., Dobsikova, R., Svobodova, Z., Modra, H., Luskova, V., 2006. Effect of deltamethrin on the biochemical profile of common carp (*Cyprinus carpio* L.). *Bulletin Environmental Contamination Toxicology* 76, 992-998.
- Velisek, J., Svobodova, Z., Machova, J., 2008. Effects of bifenthrin on some haematological, biochemical and histopathological parameters of common carp (*Cyprinus carpio* L.). *Fish Physiology and Biochemistry* 35, 583-590.
- Watterson, A.E., 1999. Regulating pesticides in the UK: a case study of risk management problems relating to the organophosphate diazinon. *Toxicology Letters* 107(1-3), 241-248.
- Zaragoza, A., Andres, D., Sarrion, D., Cascales, M., 2000. Potentiation of thioacetamide hepatotoxicity by phenobarbital pretreatment in rats, inducibility of FAD monooxygenase system and age effect. *Chemo-Biological International* 124, 87-101.

## Biochemical Characteristics of Blood and Histopathological Study of Experimental Diazinon Poisoning in Common Carp (*Cyprinus carpio*)

M. Banaee<sup>1</sup>, A. R. Mirvaghefi\*<sup>2</sup>, B. Mojazi Amiri,<sup>2</sup> and Gh. R. Rafiee<sup>2</sup>

<sup>1</sup> Department of Fisheries, Faculty of Natural Resources, Behbahan Khatam Alanbia University of Technology, I.R. Iran

<sup>2</sup> Department of Fisheries, Faculty of Natural Resources, Tehran University, I.R. Iran

(Received: 23/10/2010 , Accepted: 07/03/2011)

### Abstract

Diazinon is commonly used for pest control in the agricultural farms surrounding freshwater reservoirs. Therefore, this study was conducted to determine the sub-lethal toxicity of this organophosphorous pesticide, in aquatic ecosystems as a pollutant, and its effects on histopathology of liver and some biochemical blood parameters of common carp, *Cyprinus carpio*. Diazinon was applied at sub-lethal concentrations of 60 and 120 µg/L during 10, 20 and 30 days. Compared to the control specimens, fish after a chronic exposure to diazinon had significantly ( $p < 0.05$ ) higher plasma Aspartat transaminase (AST), Alanin transaminase (ALT), alkaline phosphatase (ALP), lactate dehydrogenase (LDH), cretinin phosphokinase (CK) activities, and levels of glucose, albumin and cholesterol, but no significantly differences in total protein and globulin levels were observed between treated fish and control group. The histopathological effects of diazinon on liver tissue of *C. carpio*, were examined by light microscopy. Disorientation of liver cells, cytoplasmic and nuclear material deposition, vacuoles formation in liver tissue, liver cell necrosis and destruction of the structure and rupture of the blood sinuses were observed in the liver tissue of treated fish by diazinon.

**Keywords:** *Diazinon, Biochemical parameters, Liver histopathology, Common carp*

\*Corresponding author:

Tel: +982632223044

Fax: +9802632245908

E-mail: vaghefi@nrf.ut.ac.ir