

لیگاتور شریان فمورال مشترک در مبتلایان به آنوریسم
مایکوتیک
شریان فمورال در معتادان تزریقی

**

۱*

(/)

(/)

()

(/)

Archive of SID

:

:

:

:

:

*

**

// :

// :

// :

()

.()

(.)

.(.)

() (/)

.()

.()

.()

()

()

:

()

(/)

(/)

(/)

(/)

(/)

()

(/)

:

Archive of SID

/

/

/

/

/

(

)

(/)

)

(

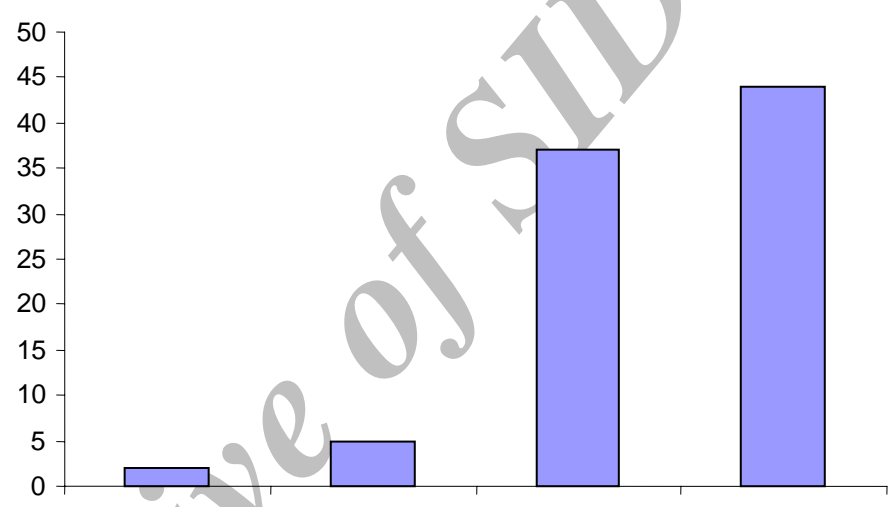
/

(/)

(/)

(/)

:



(.)

(.)

(.)



(.)

(.)

()

Archive of SID

(.)

Reddy

(.)

Mankeller

(.)

.()

. (/)

- 1-Lumsden AB, Lin PH, Bush RL, Chenc. Arterial Disease. In: Brunicaardi c, Andersen DK, Billiar TR, Dunn DL, Hunter JG,. Pollock RE, editors. Schwartz's Principles of Surgery.New York: Mc Grow- hill; 2005.p. 732.
- 2-Veith FJ, Hobsin RW, Williams RA, Wilson SE. Vascular surgery: principles and practice. 2nd ed. New York: McGraw- Hill; 1994.
- 3-Moeis PJ, Malt RA. Oxford textbook of surgery. New York: Oxford Univ Press; 1994.
- 4-Johnson J, Ledqewood A,lucas C. Mycotic aneurysm; new concepts in thearpy. Arch surgery 1993; 118: 577-82.
- 5-Buerger R, Feldman AJ. Infected groin aneurysm from heroin addiction. In: Bergan JJ, Yao JST, editors. Aneurysms. New York: Grune & Stratton; 1982. p. 643-55.
- 6-Brown SL, Busuttill RW, Boker JD. Bacteriologist and determinant of survival in patient with mycotic aneurysm. J Vas Surg I 1984: 541-5.
- 7-Reddy DJ, Smith RF, Elliot JP, Haddad GK, Wanek EA. Infected femoral artery false aneurysm in drug addicts: evaluation of selective vascular reconstruction. J vasc surg 1986, 3:718-22.
- 8- Salehian MT, Shahid N, Mohseni M, Ghodoosi I, Marashi SA, Fazel I. Tretment of infected pseudoaneurysm in drug abusers: ligation or reconstruction? Arch Iranian Med 2006; .9(1):49-52.
- 9-Manekeller S, Tolba RH, Schroeder S, Lauschke H, Reming J,Hirner A. Analysis of vascular complications in intra-venous drug addicts after puncture of femoral vessels. Zentralbl chir 2004 Jan;129(1):21-8.