

//  
//

( )

**(OKC)**

\*

---

*OKC* (OKC) :  
*OKC* OKC .  
*OKC* OKC :  
*OKC* ( ) :  
*OKC* OKC :  
*OKC* OKC :  
*OKC* (IHC) :

---

OKC

(OKC)

OKC .( )

.( )



(mono clonal anti -

DAB  
Mouse)

( )

(Overnight)

Silon coated  
Oven

)

(

)

(Xylene)

(

:

%

PH= % / )

(

( )	( )
( )	(+)
( )	(++)
( ) ( )	(+++)

( )

(+)

(++)

(+++)

PH=6

)

(

(Room temperature)

PBS

Non-serum protein

OKC

% / OKC

% /

% /

(Anti

PBS

%

human cytokeratin)

%

%

( )

(% ) OKC

(% )

(P < / )

(% )

(% )

(% ) OKC

(P < / )

% OKC %

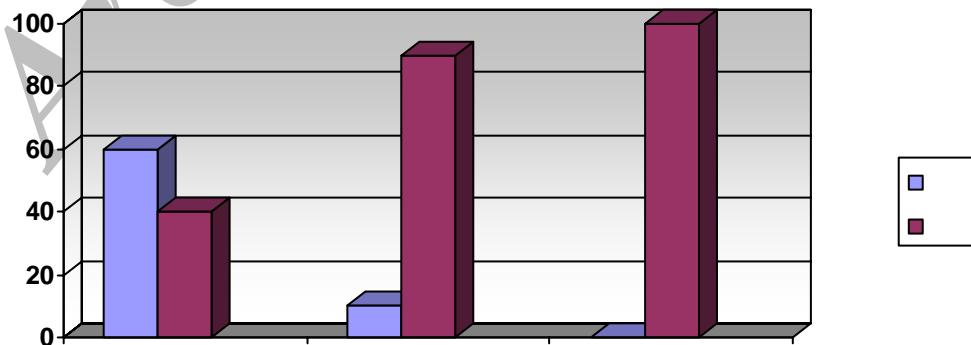
% OKC

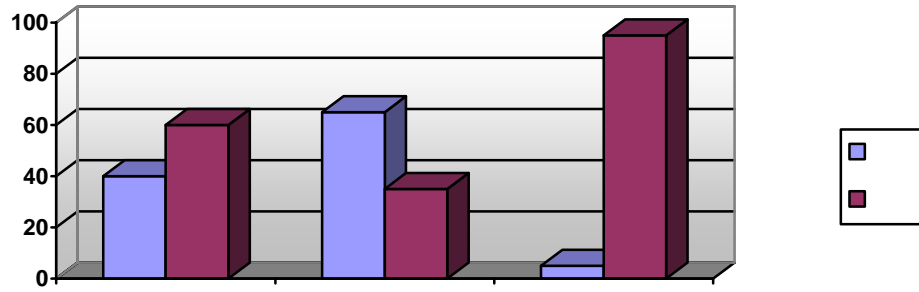
%

(% / )	(% / )	(N=19)
(% / )	(% / )	(N=12)
(% / )	(% / )	(N=16)
(% / )	(% / )	(N=47)

Mann – Whitney

OKC





Archive of SID

( )

OKC ( )

( )

( )

OKC

Morgan

OKC

OKC %

( )

Mathew

OKC

OKC ( )

OKC

## OKC

**REFERENCES**

1. Neville D, Allen B. Oral and Maxillofacial Pathology . 2<sup>nd</sup> Ed. Wb Saunders 2002.
3. Mervyne S. The aggressive nature of the odontogenic keratocyst: is it a benign cystic neoplasm? Part 1: Clinical and early experimental evidence of aggressive behaviour. J Oral Oncol 2002;38:219-26.
4. Meredith A, William CF, Maria T, Leonard BK. Differentiation of odontogenic keratocyst from non keratinizing cysts by use of FNA (Fine-Nedle Aspiration) Biopsy and cytokeratin 10 staining . J Oral Maxillofacial Surg 2000;58:935-40.
5. Ben Z. Hean and Neck surgical pathology. Williams and Wikins and wikins 2000. pp:204-20.
6. Mervyn S. The aggressive nature of the odontogenic keratosyst : is it a benign cystic neoplasm ? part 2 : proliferation and genetic studies. J Oral Oncol 2002;38:407-15.
7. John GM, Ben ZP, Samir SS, Michael J. Cytokeratin expression in the odontogenic keratocyst. J Oral Maxillofac Surg 2000;58:862-5.
8. Home M. Epression of cytokeratin in odontogenic jaw cysts: Monoclonal antibodies reveal distinct variation between the different cyst types. J Oral Pathology 1987;16:338-46.
9. Morgan PR, Shirlow PJ, Johnson NW. Potential application of antikeratin antibodies in oral diagnosis . J Oral Pathol 1987;16:212-22.
10. Gao Z, Mackenzie IC. Cytokeratin expression of the odontogenic epithelia in dental follicles and developmental cysts. J Oral Med 1989;18(2):63-7.
11. McDonald AW, Fletcher A. Expression of cytokertatin in the epithelium of dentigerous cysts and odontogenic keratocysts. And aid to diagnosis . J Clin Pathol 1989;42:736-9
12. Mervyn S: The aggressive nature of the odontogenic keratosyst : is it a benign cystic neoplasm? Part 3: Immunocytochemistry of cytokeratis and other epithelial cell markers. J Oral Oncol 2002;(38):407-15.

- 
13. Morgan PR, Shirlow PJ, Jhonson NM, Lerigh IA, Lane EB. Potential applications of antikeratin antibodies in oral diagnosis. *J Oral Pathol* 1987;16:212-22.
  14. Mathews JB, Moson GI, Browne RM. Epithelial cell markers and proliferating cells in odontogenic jaw cysts. *J Pathol* 1988;156:283-90.

Archive of SID