

//
//

()

*

Abduction

Paired-t test

Abduction

Sign test

Stage

/

/

/ ± /

Stage

Stage

/ ± /

/ ± /

$P < /$

Stage

Stage

$(P < /)$

Stage Latissimus Dorsi

Episcopo

Teres Major

External Rotation

()

/ /

Duchenne

Latissimus Dorsi

()

Stimsun

Abduction

Hoffer

()

Itoh ()

Hoffer

Latissimus Dorsi

()

()

Abduction
 Mallet
 ()
 Stage
 Stage
 Stage
 Stage
 Stage

(Lateral Decubitus)

()

()

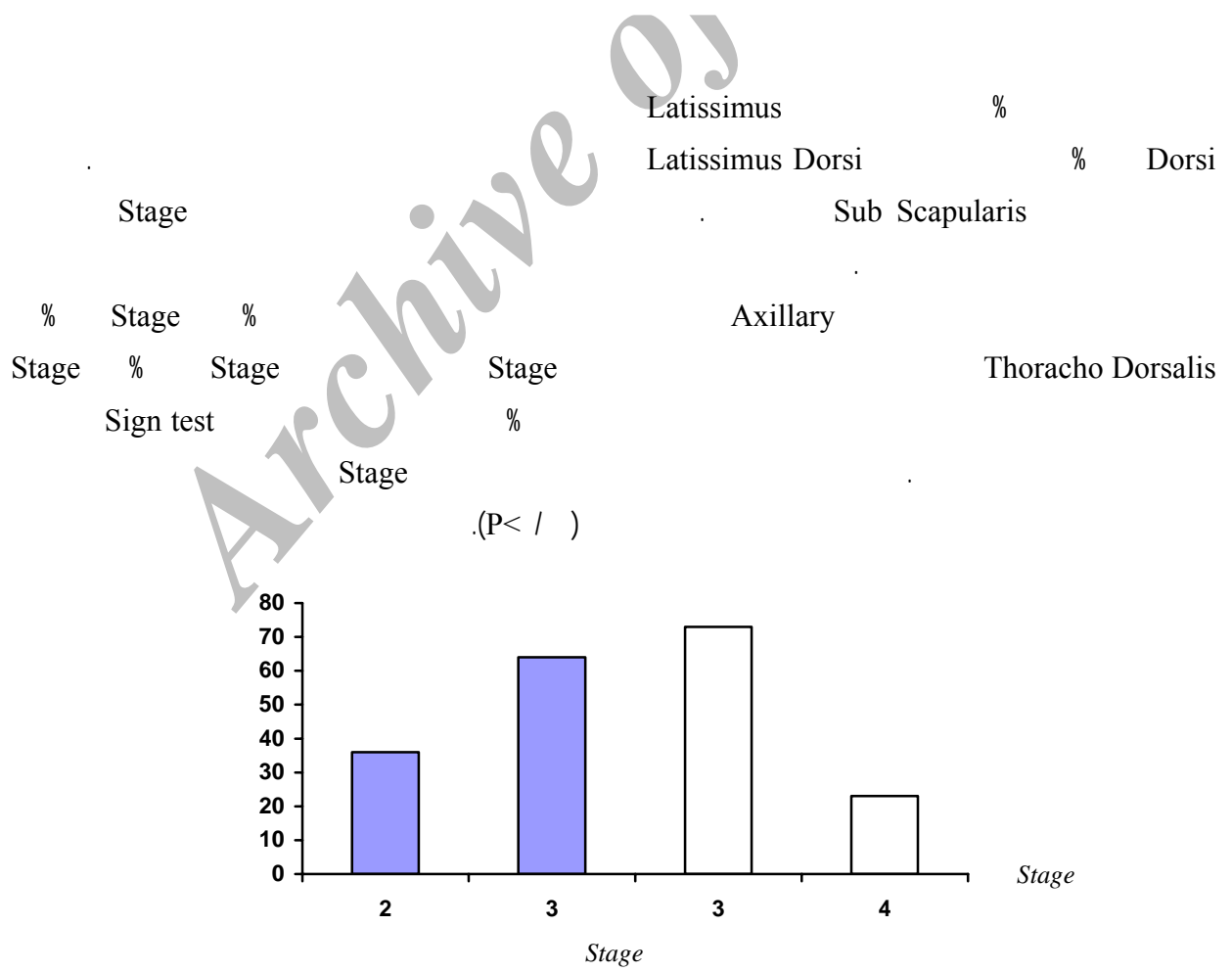
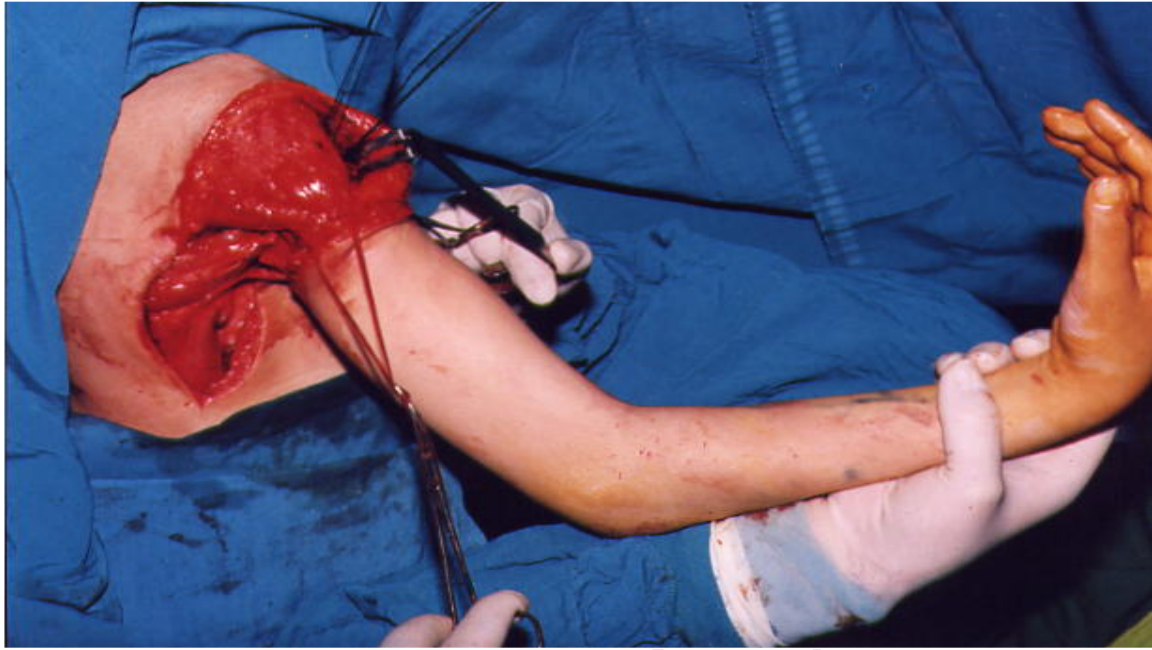
()

Archive of SID

(% /)
/ ± /

(% /)

ECG



(P < /)

/ ± /

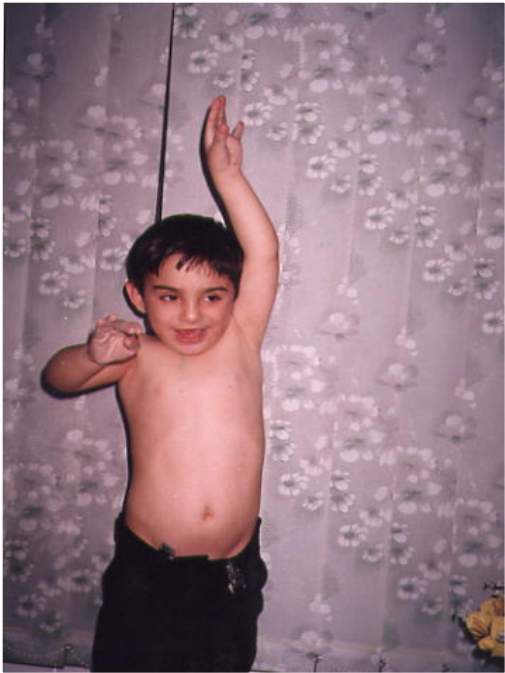/ ± /

()

Paired-t test

/ ± /

%



Abduction

Stage

Abduction

Stage

Latissimus Dorsi

()

/ /

()

REFERENCES

1. Peter M. Waters. Pediatric brachial plexus palsy, Green's operative hand surgery: 5th ed. Vol 2. Philadelphia: Elsevier. 2005; PP: 1297-316.
2. Duchene GB. De L' Electrisation localisee et son application a la pathologie et a la therapeutique. 3rd ed. Paris: Balliere. 1872.
3. L' Episcopo JB. Restoration of muscle balance in the treatment of obstetrical paralysis. NY State J Med. 1939; 39: 357.
4. Hoffe MM, Wickenden R, Roper B. Brachial plexus birth palsies: Results of tendon transfers to the rotator cuff. J Bone Surg 1973; 60A: 691- 5.
5. Z Achary RB, Leed's MB. Transplantation of teres major and latissimus dorsi for loss of external rotation at shoulders. Lancet 1947; 2: 757.
6. Waters PM, Pelijovich AE. Shoulder reconstruction in patients with chronic brachial: Plexus birth palsy. J Bone Joint Surg 1999; 81: 649-59.
7. Itoh Y, Sasaki T, ishiguro T. Transfer of latissimus dorsi to replace a paralyzed anterior deltoid. A new technique using an inverted pedicle graft. J Bone Surg 1987; 69B: 647- 51.
8. LAitung JKG, Peck F. shoulder function following loss of the latissimus dorsi muscle. Eur J Plast Surg 1985; 38: 375- 9.
9. Troum S, Floyd we 3 waters PM. Posterior dislocation of the Humeral head in infancy associated with obstetrical paralysis. J Bone Joint Surg 1993; 75A: 1370-5.
10. Price AE, Grossmn JA. Management approach for secondary shoulder and forearm deformities following obstetrical plexus injury. Hand Clin 1995; 11: 607-17.
11. Troums. Floyed we, Waters PM. Posterior dislocation of the humeral hand in infancy associated with obstetrical paralysis. A case report. J Bone Joint Surg 1993; 75: 1370- 5.
12. Dunkerton M. Posterior dislocation of the shoulder associated with obstetric brachial plexus palsy. J Bone Joint Surg 1989; 71: 764- 6.
13. Jackson St, Hoffer MM. Brachial- plexus palsy in the newborn. Am J Bone Joint Surg 1988; 70- 1217-20.
14. Pearl ML. Edgerton Bw, Kon Ds. Arthroscopic findings related to MRI and arthrography in children with glen Humeral deformities secondary to brachial plexus birth palsy, presented at the annual meeting of the American academy of orthopedic surgeons, 2000: Dallas, Texas.
15. Rollnik JD, Hierner R, Schubert M. Botulinum toxin Treatment of co contraction after birth-related, Brachial plexus lesions. Neurology 2000; 33: 1350- 4.

-
16. Grfen Wt. Tachd Jian MO. Correction of residual deformity of the shoulder from obstetrical palsy. *J Bone Joint Surg* 1985; 45 A: 1545.
 17. Houc, Tai Y. Transfer of upper pectoralis major flap for functional reconstruction of deltoid muscle. *Chin Med J* 1991; 104: 7537.

Archive of SID