

//
//
//

()

PCNA ki – 67

*

R.E.E

Squamous cell carcinoma Mucoepidermoid carcinoma Ameloblastoma

PCNA ki- 67 .

PCNA Ki-67

IHC PCNA ki-67

streptavidin- avidin biotin

%

Ki-67

%

%

%

PCNA

PCNA , ki-67

PCNA ki – 67

() .

REE

REE

CEJ

()

(Cervicoenamel Junction)

PCNA ki- 67 .()

(.)

PCNA Edematsu
ki-67

(.)

Ki-67 PCNA Multi Potential

Ki-67 SCC (Mucoepidermoid Carcinoma) MEC
(Squamous Cell Carcinoma)

(.)

DNA

PCNA

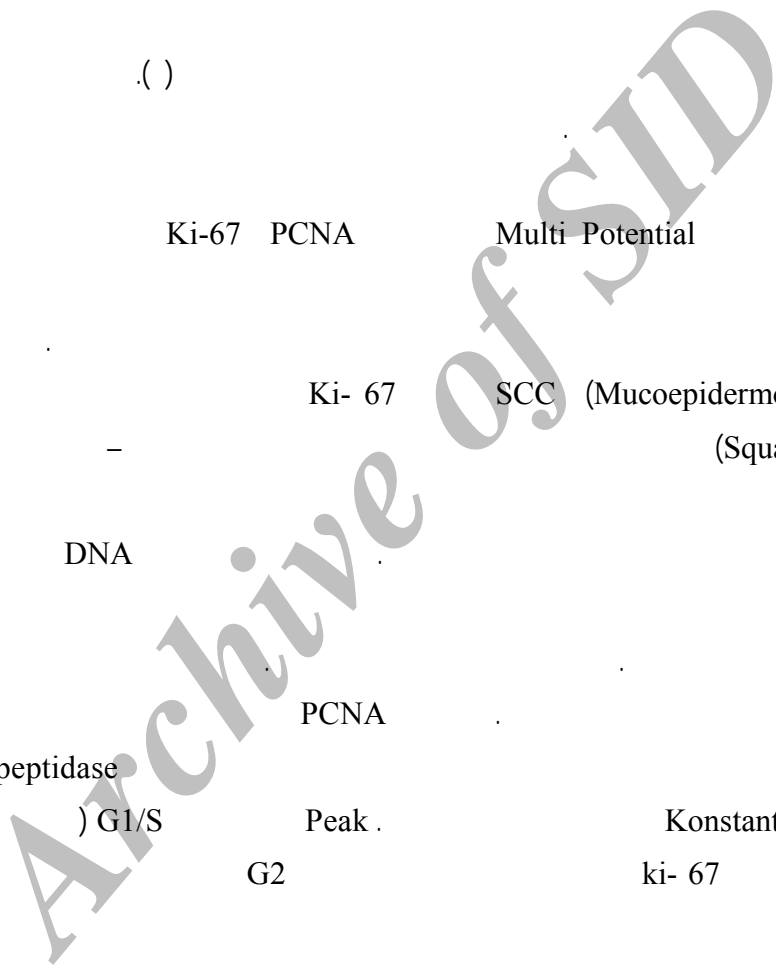
DNA- Polypeptidase
() G1/S Peak . Konstantinos .
G2 ki-67

(.)
PCNA Matulova

Immunohistochemistry

(.)

() ki-67 Piatelli



(Clone Sigma 1: 100 PC 10) PCNA

(Clone MIBI 1: 100) anti- ki-67 Ki-67

Ki-67

%
% %

(shun)

(++)

(+)

(+++)

X4

(++)

X10

(+++)

(.)

(+)

X40

IHC

Avidin- Biotin

H2O2 % /

Antigen retrieval

(700 watt) Microwave

Ki-67 (%) ()

(P< /)

Ki-67

USA, DAKO, Ki-67 PCNA clone :Pc10)

/ (clone:MIB-1

	ki-67 /
(%) (%)	
() ()	
() ()	

Biotinlated- antimouse immunoglobulin

(Denmark, DAKO , Ko673)

(D.A.B) diaminobenzidine tetrahydrochloride

(%)

PCNA

(%)

()

(P< /)

Meyer's hematoxilin counterstain

mount

counter stain

anti PCNA

(++) (+) (++)
(+++)
(P < /)

PCNA

(++) (+)
(+++) (++) (+)

(P < /)

ki- 67

(+) (++) (+)
(+++) (++)
(P < /)

PCNA Ki-67

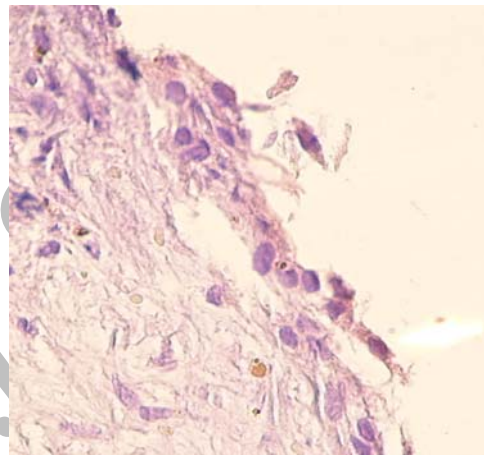
Edematsu
Edematsu

() Edematsu
() Matulva

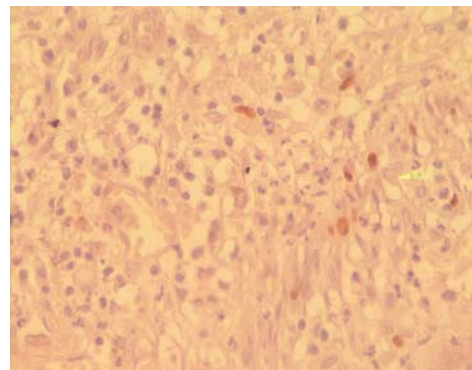
() Tripi
PCNA ki- 67

PCNA

(%)	(%)	PCNA /
()	()	
()	()	



PCNA



PCNA

() PCNA () ki- 67 () Edematsu
(+) (++) (+)
(+++) (++)
(P < /)
(+) ki- 67

case-control

Ki-67 PCNA

cohort

PCNA Ki-67

()

Sharshhta

cystic precystic

(EGF)

REFERENCES

1. Ten Cate AR. Oral Histology: Development, structure and function RK 280. T96, 6th ed. St Louis: The CV Mosby. 2003; PP: 1-6.
2. Neville B, Damm D, Allen M, Bougot J. Oral and Maxillofacial Pathology. 2nd ed. WB Saunders. 2002; PP: 590-5.
3. Regezi JA, Sciubba JJ, Jordan R. Clinical pathologic correlation. 4th ed. WB Saunders. 2003; PP: 246-8.
4. Edematsu M, Kumamoto H, Ooya K, Echigo S. Apoptosis - related factor in the epithelial components of dental follicle and dentigerous cysts associated with impacted third molar of mandible. Am J Oral Surg Oral Pathol Endod 2005; 99: 17-23.
5. Piatelli AD, Lezzi G, Fioroni MA, Santinelli AL, Fubini MM, Santinelli AF, et al. Ki- 67 expression in dentigerous cyst, unicystic ameloblastoma and ameloblastoma arising in dentigerous cyst. Am J Endodon 2002; 128: 56-62.
6. Konstantinos J, Karantza E, Karantza AN. Immunohistochemical study of bel-2 protein, Ki-67 and P53 protein in epithelial of glandular odontogenic cyst and dentigerous cyst. Am J Oral Pathol Med 2000; 29: 139- 44.
7. Matulova P, Witter K, Misek J. Proliferating cell nuclear antigen (PCNA) expression in tooth primordial in the fide vole (*Microtus agrestis* Rodentia). Connect Tissue Res 2002; 43: 138-42.

8. Trippi TR, Bonaccorso A, Rapisarda F, Bartoloni G. Proliferative activity in periapical lesion. *Aus J Endod* 2003; 29: 31-3.
9. Sharshita P, Yamada K, Higa S, Mori M. Epidermal growth factor receptor in odontogenic cyst and tumors. *Am J Oral Pathol Med* 1992; 21: 314-7.

Archive of SID